



# A clinically unsuspected nasopharyngeal sarcoidosis

## Klinik olarak şüphelenilmeyen nazofarengeal sarkoidoz

Selahattin Tuğrul, MD,<sup>1</sup> Seda Sezen Göktaş, MD,<sup>1</sup> Berke Özücer, MD,<sup>1</sup>  
Fatma Cavide Sönmez, MD,<sup>2</sup> Orhan Özturan, MD.<sup>1</sup>

<sup>1</sup>Department of Otolaryngology, Medical Faculty of Bezmialem Vakıf University, İstanbul, Turkey

<sup>2</sup>Department of Pathology, Medical Faculty of Bezmialem Vakıf University, İstanbul, Turkey

### ABSTRACT

Sarcoidosis is a multi-system disease which rarely involves the upper respiratory tract, leading to hoarseness, dysphagia, laryngeal paralysis, and upper airway obstruction. The Waldeyer's ring involvement in sarcoidosis is also very rare. In this article, we report a 32-year-old male case in whom a nasopharyngeal mass was detected based on the Waldeyer's ring involvement due to sarcoidosis.

**Keywords:** Nasal obstruction; nasopharynx; sarcoidosis.

### ÖZ

Sarkoidozis nadiren üst solunum yolunu tutarak ses kısıklığı, yutma güçlüğü, larengeal paralizisi ve üst solunum yolunda tıkanıklığa yol açan multisistemik bir hastalıktır. Sarkoidozun Waldeyer halkası tutulumu da oldukça nadirdir. Bu yazıda, sarkoidoz nedeni ile Waldeyer halkası tutulumu olan, nazofarenkste kitle tespit edilen 32 yaşında bir erkek olgu sunuldu.

**Anahtar Sözcükler:** Nazal tıkanıklık; nazofarenks; sarkoidozis.

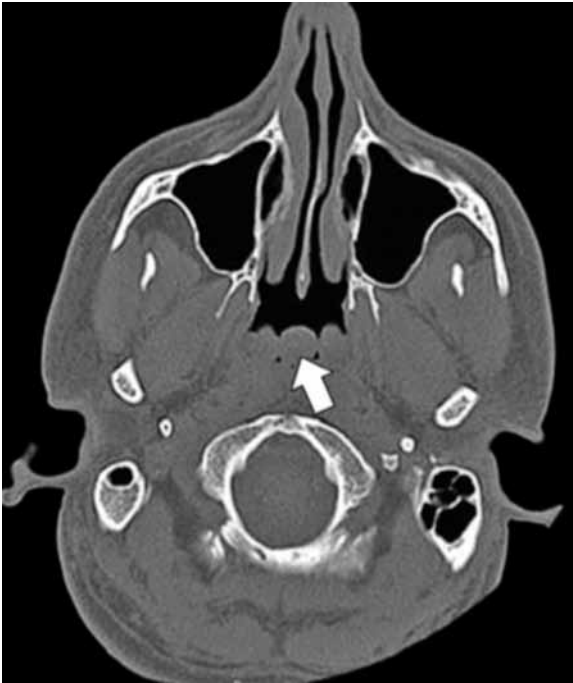Sarcoidosis is a multisystem disease that most commonly affects those between the ages of 10 and 40. The overall prevalence of sarcoidosis appears to be between 10 to 20 per 100,000 people. Lung involvement occurs in over 90% of cases. Rarely there may be involvement of the upper airway with symptoms of hoarseness, dysphagia, laryngeal paralysis, and upper airway obstruction. Extrapulmonary symptoms may be reported, including the skin (rashes, plaques), joint (arthritis) or eye findings (changes in vision, iridocyclitis). Patients may have noticed lumps due to lymphadenopathy. The physical exam may reveal several findings supportive of a diagnosis of sarcoidosis; however none of the findings

are specific to sarcoidosis.<sup>[1]</sup> We report a case of sarcoidosis with nasopharyngeal involvement.

### CASE REPORT

A 32-year-old male was referred to our hospital with a chief complaint of nasal obstruction and snoring. Nasal endoscopic examination revealed septal deviation to the left, bilateral inferior turbinate hypertrophy, a polypoid mass in the nasopharynx and hypertrophy of the uvula. Operative planning included septoplasty, radiofrequency ablation and outfracture of the inferior turbinates, nasopharyngeal biopsy as well as adenoidectomy and partial uvulectomy. Preoperative lab values were within normal






**Figure 1.** Computed tomography, axial section showing nasopharyngeal mass (white arrow).

limits. Paranasal computed tomography (CT) revealed a polypoid mass in the nasopharynx (Figure 1). Written informed consent for these procedures and their reporting had been obtained from the patient, and surgery was performed.

Postoperative pathological examination of the nasopharyngeal material was interpreted as 'granulomatous inflammation' (Figure 2). A sample was negative for acid resistant bacteria



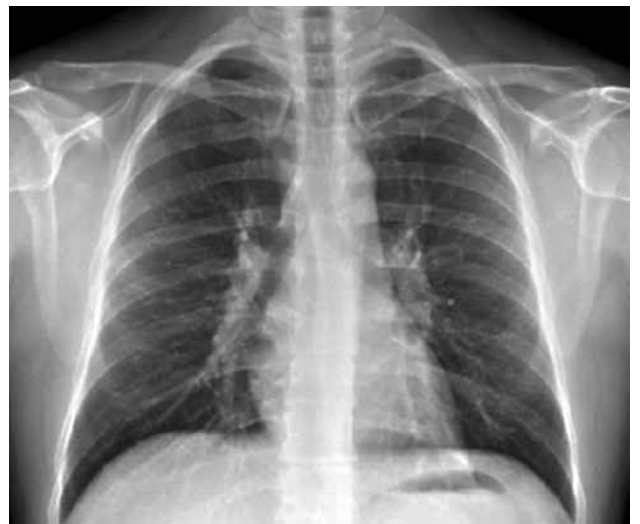**Figure 2.** Histopathologic section, showing respiratory epithelium with granulomas in lymphoid stromae (H-E x 100)

staining and cell line cultures did not propagate. Further examination revealed slightly elevated levels of serum angiotensin converting enzyme (57 U/L, Normal range: 8-52 U/L). Blood and urine calcium levels were within normal limits.

Chest X-ray and thoracic CT revealed mediastinal vs. hilar lymphadenopathies (Figure 3). The patient underwent bronchoscopy, and microscopic examination of bronchoscopic material revealed alveolar macrophages, lymphocytes and polymorphonuclear leukocytes. Ophthalmic examination did not reveal any ocular involvement. The patient was referred to the Pulmonology Department for further follow-up.

### DISCUSSION

Many systemic diseases affect Waldeyer's ring and should be considered in the differential diagnosis, such as Tangier's disease (familial hypo-alpha-lipoproteinemia), tuberculosis, amyloidosis and metastasis from primary tumors as well as sarcoidosis. Children with Tangier's disease have enlarged, hyperplastic palatine and pharyngeal tonsils with yellow-orange or yellow-grey discoloration. Histologically, large groups and accumulations of macrophages with foamy cytoplasm can be identified in the palatine and pharyngeal tonsils. Isolated tumor-like involvement of the nasopharynx, of the entire Waldeyer's ring or the palatine tonsils without systemic disease is exceptionally rare. Amyloid deposition in Waldeyer's ring has been described in plasmacytomas, nasopharyngeal carcinomas



**Figure 3.** Chest X-ray, posterior-anterior view, showing hilar lymphadenopathy.

or tonsillitis. Metastases from primary tumors outside the head and neck area to the naso- and oropharynx are exceptionally rare, because the nasopharyngeal and palatine tonsils have no afferent lymph vessels. Renal cell carcinomas are known to metastasize to the nasopharynx. Bilateral metastases to the palatine tonsils have been described for pancreatic carcinoma. Other metastatic palatine tonsil tumors include carcinomas of the breast, lung, stomach, colon, prostate, skin and kidneys. Another differential diagnosis consists of infections with *Mycobacterium tuberculosis* and formation of caseating tuberculoid granulomas. The majority of patients with pulmonary tuberculosis have nasopharyngeal involvement, but isolated nasopharyngeal tuberculosis is rare.<sup>[2]</sup>

There are few examples in the literature of Waldeyer's ring involvement due to sarcoidosis. Yarrington et al.<sup>[3]</sup> reported a case with isolated tonsillar sarcoidosis and Erwin<sup>[4]</sup> reported tonsillar sarcoidosis cases. Saussez et al.<sup>[5]</sup> reported a five-year-old case that was incidentally identified with bilateral tonsillar and adenoidal sarcoidosis. In 1986, two sarcoidosis cases were reported that were diagnosed after adenoidectomy.<sup>[6]</sup>

In a study published in 1982, 220 of 2,319 sarcoidosis patients had head and neck region involvement, representing 9% of the patients seen at the Mayo Clinic from 1950 through 1981, and researchers identified 12 who had laryngeal sarcoidosis.<sup>[7]</sup> Similarly in another epidemiologic study, 22 out of 736 patients with sarcoidosis had ear, nose and throat involvement (3%).<sup>[8]</sup> Also, a study of 818 patients with multisystem sarcoidosis reported that 53 patients (6%) exhibited involvement of the upper respiratory tract, with the majority (n=36) having nasal mucosal involvement.<sup>[9]</sup> A nasal examination may reveal a granulomatous mass, yellow-white mucosal papules, and adhesions and crusting of septal and turbinate mucosa. Nodular sarcoidosis of supraglottic and glottic structures can lead to dyspnea, stridor, dysphonia, irritating cough with pharyngolaryngeal discomfort, dysphagia, retronasal obstruction, and/or hyponasal speech.<sup>[10]</sup> In laryngeal sarcoidosis, most commonly involved is the epiglottis followed by the arytenoids, aryepiglottic folds, and ventricular folds. Involvement of the true vocal folds and subglottis is rare.<sup>[11]</sup> Cervical

lymphadenopathy is the most common head and neck manifestation of sarcoidosis, but sarcoidosis only accounts for 1.7% of all head and neck lymphadenopathy.<sup>[12]</sup>

In conclusion, patients with sarcoidosis can refer to otolaryngology clinics with nonspecific symptoms such as nasal obstruction and snoring. This report is intended to indicate that nasopharyngeal involvement of sarcoidosis is one of the reasons of nasal obstruction in patients with sarcoidosis and to draw attention to the need to consider sarcoidosis in the differential diagnosis of patients with acquired nasal obstruction.

#### Declaration of conflicting interests

The authors declared no conflicts of interest with respect to the authorship and/or publication of this article.

#### Funding

The authors received no financial support for the research and/or authorship of this article.

#### REFERENCES

1. Heinle R, Chang C. Diagnostic criteria for sarcoidosis. *Autoimmun Rev* 2014 Apr;13:383-7.
2. Cardesa A, Pieter JS. *Pathology of the Head and Neck*. 6th ed. Berlin: Springer; 2006.
3. Yarrington CT Jr, Smith GS Jr, Benzmler JA. Value of histologic examination of tonsils. A report of isolated tonsillar sarcoidosis. *Arch Otolaryngol* 1967;85:680-1.
4. Erwin SA. Unsuspected sarcoidosis of the tonsil. *Otolaryngol Head Neck Surg* 1989;100:245-7.
5. Saussez S, Mahillon V, Haller A, Levy J, Ferster A, Dargent JL. Clinically unsuspected tonsillar sarcoidosis in a child revealed by routine histologic examination. *Int J Pediatr Otorhinolaryngol* 2006;70:155-8.
6. Wilson R, Sweatman M, Mackay IS, Mitchell DN. Adenoidal tissue as an aid to the diagnosis of sarcoidosis in childhood. *Thorax* 1986;41:66-7.
7. Neel HB, McDonald TJ. Laryngeal sarcoidosis: report of 13 patients. *Ann Otol Rhinol Laryngol* 1982;91:359-62.
8. Baughman RP, Teirstein AS, Judson MA, Rossman MD, Yeager H Jr, Bresnitz EA, et al. Clinical characteristics of patients in a case control study of sarcoidosis. *Am J Respir Crit Care Med* 2001;164:1885-9.
9. James DG, Barter S, Jash D, MacKinnon DM, Carstairs LS. Sarcoidosis of the upper respiratory tract (SURT). *J Laryngol Otol* 1982;96:711-8.
10. Polychronopoulos VS, Prakash UB. Airway involvement in sarcoidosis. *Chest* 2009;136:1371-80.
11. van den Broek EM, Heijnen BJ, Verbist BM, Sjögren EV. Laryngeal sarcoidosis: a case report presenting transglottic involvement. *J Voice* 2013;27:647-9.
12. Chen HC, Kang BH, Lai CT, Lin YS. Sarcoidal granuloma in cervical lymph nodes. *J Chin Med Assoc* 2005;68:339-42.