



## Endoscopic transcanal stapes surgery: our technique and outcomes

### Endoskopik transkanal stapes cerrahisi: Tekniğimiz ve sonuçlarımız

Engin Dursun, MD., Abdulkadir Özgür, MD., Suat Terzi, MD., Mahmut Oğurlu, MD.,  
Zerrin Özergin Coşkun, MD., Münir Demirci, MD.

Department of Otolaryngology, Medical Faculty of Recep Tayyip Erdoğan University, Rize, Turkey

#### ABSTRACT

**Objectives:** This study aims to evaluate the outcomes of endoscopic stapes surgery in terms of hearing gain and complications.

**Patients and Methods:** The medical records of 31 patients (13 males, 18 females; mean age 41.5±8.6 years; range 23 to 60 years) who underwent endoscopic stapes surgery in our clinic between April 2013 and June 2015 were retrospectively analyzed. The mean preoperative and postoperative pure tone bone conduction, air-bone gap, postoperative air-bone gap gain, duration of surgery and complications were evaluated.

**Results:** The right ear was operated on 15 patients and the left ear on 16 patients. The mean postoperative air-bone gap was statistically significantly improved, compared to preoperative values ( $p<0.001$ ). The mean air-bone gap gain was 25.5±7.0 dB.

**Conclusion:** Our study results suggest that endoscopy is a safe method which can be used in stapes surgery.

**Keywords:** Endoscopic ear surgery; otosclerosis; stapes surgery.

#### ÖZ

**Amaç:** Bu çalışmada stapes cerrahisinin işitme başarısı ve komplikasyonlar açısından sonuçları değerlendirildi.

**Hastalar ve Yöntemler:** Nisan 2013 - Haziran 2015 tarihleri arasında kliniğimizde endoskopik stapes cerrahisi uygulanan 31 hastanın (13 erkek, 18 kadın; ort. yaş 41.5±8.6 yıl; dağılım 23-60 yıl) tıbbi kayıtları retrospektif olarak incelendi. Ameliyat öncesi ve ameliyat sonrası saf ses kemik yolu ortalamaları, hava-kemik yolu açıklığı, ameliyat sonrası hava-kemik yolu açıklığı kazancı, cerrahi süresi ve komplikasyonlar değerlendirildi.

**Bulgular:** On beş hastanın sağ kulağı ve 16 hastanın sol kulağı ameliyat edildi. Ameliyat öncesi değerlere kıyasla, ameliyat sonrası ortalama hava-kemik yolu açıklığında istatistiksel olarak anlamlı bir iyileşme gözlemlendi ( $p<0.001$ ). Ortalama hava-kemik yolu açıklığı kazancı 25.5±7.0 dB idi.

**Sonuç:** Çalışma bulgularımız endoskopinin stapes cerrahisinde kullanılabilecek güvenli bir yöntem olduğunu göstermektedir.

**Anahtar Sözcükler:** Endoskopik kulak cerrahisi; otoskleroz; stapes cerrahisi.

Otosclerosis is a disease usually presenting with hearing loss and occurring due to bone remodeling disturbances in the otic capsule.<sup>[1,2]</sup> Although several factors such as autoimmunity,

genetics, viruses, inflammation, and hormonal factors are suspected as etiologic causes, none of them have been definitively identified as such.



The surgical treatment of otosclerosis was first described in the 1890s as opening a hole in the promontory. By the 1950s, it was understood that ensuring mobility of the stapes had an important role for improvement of hearing. After the 1960s, placing a Teflon piston after opening a hole in the oval window was considered to be the most appropriate method in modern surgery.<sup>[3]</sup>

Traditionally, stapes surgery is performed using a microscope. However, in recent years, use of an endoscope in stapes surgery has enjoyed increased popularity-similar to other ear surgical procedures. With their wide fields of view, endoscopes provide the surgeon with better visualization of difficult locations, such as the facial and tympanic recesses, compared with the linear field of view provided by microscopes.<sup>[4]</sup>

In the first published study of endoscopic stapes surgery, the endoscope was used only as an auxiliary instrument.<sup>[5]</sup> In recent years, stapes surgery has been performed with endoscopes at all stages.<sup>[6-8]</sup>

The aim of this study is to evaluate the results of endoscopic stapes surgery in terms of hearing gain and surgical complications.

#### PATIENTS AND METHODS

An informed consent was obtained from each patient. The study protocol was approved by the Medical Faculty of Recep Tayyip Erdoğan University, Hospital Ethics Committee (2016/46). The study was conducted in accordance with the principles of the Declaration of Helsinki.

Thirty-one patients (13 males, 18 females; mean age 41.5±8.6 years; range 23 to 60 years) who underwent endoscopic stapes surgery between April 2013 and June 2015 were included in this study. The archival records of the patients were reviewed.

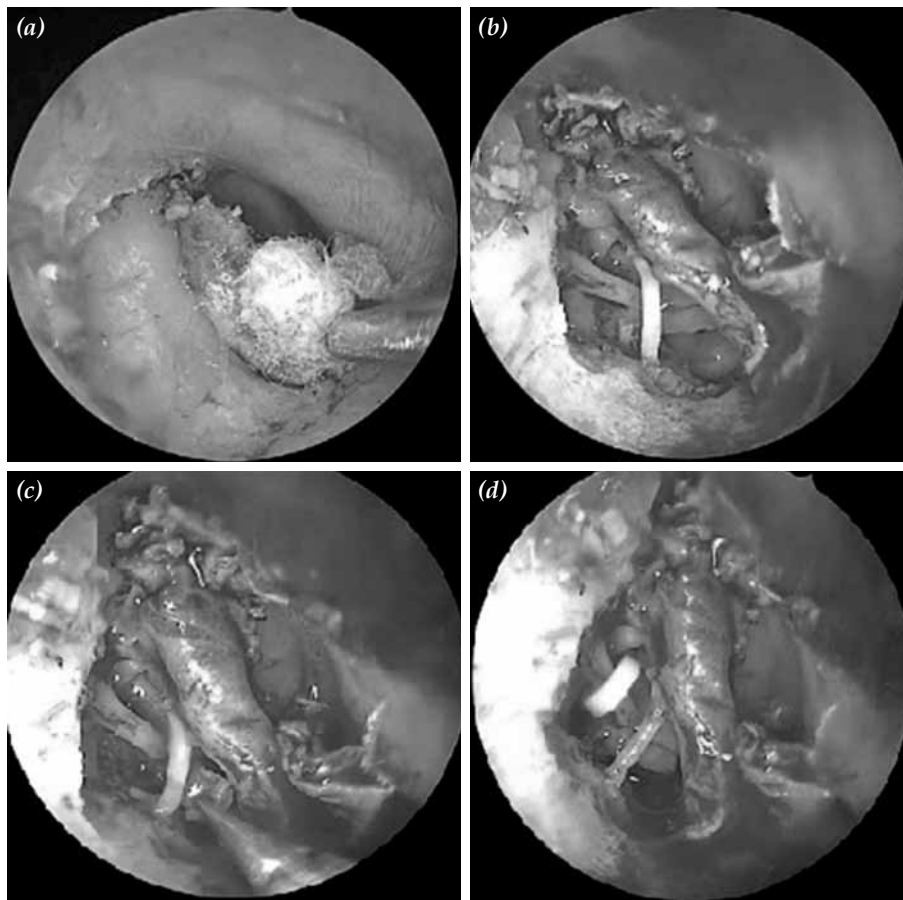
Pure tone audiometry, tympanometry, and stapedia reflex tests were routinely performed in our clinic during the preoperative evaluation of patients with a preliminary diagnosis of otosclerosis. Computed tomography was performed to exclude other diseases that can cause conductive hearing loss, and to evaluate anatomical variations rather than confirming the definite diagnosis of otosclerosis.

Preoperative evaluation of all patients was performed in accordance with these principles in the study.

The surgical procedures for endoscopic stapes surgery were performed under hypotensive general anesthesia via the transcanal approach. For this procedure, 18 cm, 2.7 mm, or 4 mm, and 0 or 30 degree endoscopes were used with a high-resolution camera system (Karl Storz, Tuttlingen, Germany). After application of a local anesthetic (20 mg/mL of lidocaine + 0.0125 mg/mL of epinephrine HCl) to the external ear canal for reduce bleeding, the flap incision was performed. The incision was made approximately 4 mm laterally from the annulus as in traditional microscopic transcanal techniques at this stage. This incision was extended towards the annulus superiorly and inferiorly. After this step, the tympanomeatal flap was elevated. Because endoscopic surgery of the ear is usually performed single-handedly, a swab inserted in the tip of the aspirator was helpful for this elevation. This technique prevented damage to the flap during elevation. It also allowed for clearing the bleeding, thereby increasing the viewed area (Figure 1a).

Once flap elevation was completed, the surgeon could enter the middle ear. At this point, the surgeon had to be careful not to damage the chorda tympani. After entering the middle ear, the ossicular system could be assessed by checking if the footplate was really fixed. In addition, the mobility of the incudomalleolar joint, course of facial nerve, and status of other middle-ear structures could be assessed. Unlike the microscopic method, the endoscopic method allowed for visualizing the stapes tendon and eminentia pyramidalis without removing bone from the scutum. However, for better control of surgical instruments and for ease of manipulating the footplate, some amount of bone could be removed from the scutum using the endoscopic method-less bone than is required with the microscopic method. We preferred to use a bone curette to remove the bone with the endoscopic method, compared to a drill with the microscopic method. This is because a drill is difficult to use with the endoscopic method (Figure 1b).

After confirming the footplate of stapes was fixed, the incudostapedial joint was separated and



**Figure 1.** (a) Elevation of the flap. (b) Appearance of the ossicles after curettage of the scutum. (c) Removal of stapes superstructure. (d) Appearance after the Teflon piston has been inserted.

the stapes tendon was cut. Anterior and posterior limbs of stapes were carefully broken, and stapes superstructure was removed (Figure 1c). After carefully drilling the footplate with a perforator, either the hole was widened with a larger size perforator or a portion or the entire footplate was removed depending on the case. The conductive chain was then restored by placing the prosthesis (Figure 1d). Materials such as fascia, perichondrium, or fat were used to support the prosthesis. After checking the movement and stability of the ossicular system, the external ear canal was packed with gelfoam or other support materials to prevent lateralization of the flap.

The time between introducing local anesthesia and pulling down the flap was recorded as the operative duration. In addition, the patients' records were reviewed to identify complications arising during the operation and associated interventions.

Patients were usually discharged on the first or second postoperative day. On the seventh postoperative day, support materials in the external ear canal were carefully cleaned. Ear drops containing topical antibiotics were administered for prevention of local infections. We used ciprofloxacin ear drops after cleaning the external ear canal at the end of the first week.

Pure tone thresholds were analyzed at 4-6 weeks postoperatively for the first audiological assessment. In addition, audiological tests were repeated at six postoperative months and at one year. For evaluating the success of surgery on hearing, the pure tone air-bone gap averages were compared at 500, 1,000, 2,000, and 4,000 Hz against the preoperative records at the postoperative sixth-month follow-up and thereafter. The patients were classified into three groups of 10 dB or less, 11-20 dB, and 21 dB or

**Table 1.** Preoperative and postoperative hearing findings

	Pure tone bone conduction (dB)		Air-bone gap (dB)		Air-bone gap gain (dB)	
	Mean±SD	Range	Mean±SD	Range	Mean±SD	Range
Preoperative	26.4±12.0	5-53	35.7±8.0	23-54		
Postoperative sixth month and after	22.2±12.4	6-52	10.2±5.0	3-30	25.5±7.0	15-44

SD: Standard deviation; dB: decibel.

more according to postoperative air-bone gap results.

### Statistical analysis

Data were analyzed with SPSS for Windows version 15.0 (SPSS Inc., Chicago, IL, USA). Continuous variables were reported as mean ± standard deviation. Preoperative and postoperative air-bone gaps were compared using the t test.

### RESULTS

In this study, 31 ears of 29 subjects were evaluated. Thirty of the analyzed patients had primary stapes surgery, while there was only one case of revision surgery. The right ear was operated on in 15 patients and the left ear in 16 patients.

The patients' preoperative and postoperative comparisons after six months for pure tone bone conduction, air-bone gap, and average postoperative air-bone gain data are summarized in Table 1. Results of the air-bone gap indicate significant improvement compared to the preoperative levels ( $p < 0.001$ ). The postoperative air-bone gap was 10 dB or lower in 19 patients (61.3%), 11-20 dB in 11 patients (35.5%), and more than 20 dB in one patient (3.2%). The mean operation duration was  $50.5 \pm 13.0$  minutes (27-90), and the mean follow-up duration was  $17.6 \pm 7.4$  months (6-31).

Complications reported in the early postoperative period were as follows. Temporary facial nerve paralysis, which was thought to be secondary to local anesthetic effect, was seen in two patients. A perilymphatic gusher was observed in one case during surgery; in this case, a Teflon piston supported by soft tissue was inserted after an observation period. As we postoperatively observed leakage enough to wet the outer dressing, a lumbar puncture

was performed for two consecutive days in order to reduce cerebrospinal fluid pressure. The leakage completely stopped on the third day. Although there was a gain of 20 dB in air conduction averages in the postoperative period, the air-bone gap was 30 dB. Revision surgery was recommended, but the patient refused. A tympanic membrane perforation was seen in three patients during surgery. Because the perforation was relatively large in one case, it was repaired with perichondrium taken from tragal cartilage. The perforation was very small in the other two cases and we did not repair the injury. The perforations closed postoperatively in all of the three cases. During flap elevation and bone curettage, the chorda tympani was injured in five patients. There was no taste loss in these patients. However, in two other cases, temporary partial taste loss was seen without any known injury. Both patients' complaints improved during the three subsequent months.

### DISCUSSION

Quite satisfactory results have been achieved regarding the effectiveness of stapes surgery in several studies.<sup>[9,10]</sup> The microscopic method is the classic method for stapes surgery. With the increasing popularity of endoscopic techniques in otologic surgery, there have been reports about endoscopic stapes surgery.<sup>[6-8]</sup> Thirty-one endoscopic stapes surgery cases were reviewed retrospectively for hearing results and complications in this report.

The history of the patient and hearing tests are the most important clues for diagnosis of otosclerosis.<sup>[11]</sup> Preoperative pure tone hearing tests, tympanometry, and stapedia reflex tests were performed on all the patients. Preoperative computed tomography evaluation has little benefit for confirmation of diagnosis. This imaging method is recommended for detection

of other anomalies, planning the operation, and for legal problems that may arise.<sup>[12]</sup> Computed tomography imaging was performed on all of the patients. There was no abnormal anatomical structure for the case in which we observed a perilymphatic gusher during surgery.

A meta-analysis about local or general anesthesia in stapes surgery did not show any difference in terms of hearing gain or risk of complication.<sup>[13]</sup> All of our operations were performed under general anesthesia. There was no complication observed due to anesthesia.

There is not enough data comparing the use of an endoscope and microscope for stapes surgery in previously documented studies. To the best of our knowledge there is only one study comparing both techniques. Operative duration and postoperative hearing results did not show a significant difference in this study. Additionally, it was reported that there was less need for drilling the posterior-superior external ear canal in endoscopic surgery. The endoscopic method is recommended especially for patients with a narrow external ear canal.<sup>[14]</sup> All surgical procedures were performed using the endoscopic approach in all patients. Relatively fewer patients underwent microscopic stapes surgery at that time in our clinic. For this reason, we were not able to compare these two techniques.

Endoscopic ear surgery has disadvantages in that the surgeon may only use one hand and the view is not three-dimensional. This condition may present difficulties to the surgeon when there is excessive bleeding.<sup>[4]</sup> Another important but theoretical disadvantage of the endoscopic technique is the possibility of hearing loss due to thermal damage. However, there was no such problem observed in this or previously reported studies. In particular, endoscopic ear surgery has been performed for five years in our clinic for many surgical procedures such as insertion of ventilation tubes, myringoplasty, tympanoplasty, and stapes surgery. Complications such as hearing loss due to thermal damage, bleeding, or tissue damage were not reported in our earlier studies.<sup>[15,16]</sup> Similarly, no such complication was seen in the present study. The rate of minor complications, such as temporary taste loss, tympanic membrane injury, and postoperative

vertigo was similar to a series of surgeries performed with microscopic methods.<sup>[9,10]</sup>

In conclusion, all of the surgical steps in classic microscopic stapes surgery can be performed via the endoscope. We believe that endoscopic technique in stapes surgery will gain popularity in parallel with its increasing use in otologic surgery.

#### Declaration of conflicting interests

The authors declared no conflicts of interest with respect to the authorship and/or publication of this article.

#### Funding

The authors received no financial support for the research and/or authorship of this article.

#### REFERENCES

1. McKenna MJ, Kristiansen AG. Molecular biology of otosclerosis. *Adv Otorhinolaryngol* 2007;65:68-74.
2. Rudic M, Keogh I, Wagner R, Wilkinson E, Kiros N, Ferrary E, et al. The pathophysiology of otosclerosis: Review of current research. *Hear Res* 2015;330:51-6.
3. Dankuc D. History of the surgery for otosclerosis and cochlear implants. *Med Pregl* 2015;68:151-5.
4. Tarabichi M. Endoscopic transcanal middle ear surgery. *Indian J Otolaryngol Head Neck Surg* 2010;62:6-24.
5. Poe DS. Laser-assisted endoscopic stapedectomy: a prospective study. *Laryngoscope* 2000;110:1-37.
6. Daneshi A, Jahandideh H. Totally endoscopic stapes surgery without packing: novel technique bringing most comfort to the patients. *Eur Arch Otorhinolaryngol* 2016;273:631-4.
7. Migirov L, Wolf M. Endoscopic transcanal stapedotomy: how I do it. *Eur Arch Otorhinolaryngol* 2013;270:1547-9.
8. Nogueira Júnior JF, Martins MJ, Aguiar CV, Pinheiro AI. Fully endoscopic stapes surgery (stapedotomy): technique and preliminary results. *Braz J Otorhinolaryngol* 2011;77:721-7.
9. Hancı D, Sözen T, Kayahan B, Saraç S, Sennaroğlu L. Stapes surgery outcomes: the practice of 35 years. *Turk Arch Otolaryngol* 2014;52:115-20.
10. Topdağ DO, Topdağ M, Aydın O, Keskin G, Oztürk M, Işeri M. Evaluation of efficacy of otosclerosis surgery on hearing outcomes. [Article in Turkish] *Kulak Burun Bogaz İhtis Derg* 2014;24:137-47.
11. Hough JV, Dyer RK Jr. Stapedectomy. Causes of failure and revision surgery in otosclerosis. *Otolaryngol Clin North Am* 1993;26:453-70.
12. Wegner I, van Waes AM, Bittermann AJ, Buitinck SH, Dekker CF, Kurk SA, et al. A Systematic Review of the Diagnostic Value of CT Imaging in Diagnosing Otosclerosis. *Otol Neurotol* 2016;37:9-15.
13. Wegner I, Bittermann AJ, Zinsmeister MM, van der Heijden GJ, Grolman W. Local versus general anesthesia in stapes surgery for otosclerosis: a systematic review of the evidence. *Otolaryngol Head*

- Neck Surg 2013;149:360-5.
14. Kojima H, Komori M, Chikazawa S, Yaguchi Y, Yamamoto K, Chujo K, et al. Comparison between endoscopic and microscopic stapes surgery. *Laryngoscope* 2014;124:266-71.
  15. Özgür A, Dursun E, Erdivanlı ÖÇ, Coşkun ZÖ, Terzi S, Emiroğlu G, et al. Endoscopic cartilage tympanoplasty in chronic otitis media. *J Laryngol Otol* 2015;129:1073-7.
  16. Özgür A, Dursun E, Terzi S, Erdivanlı ÖÇ, Coşkun ZÖ, Oğurlu M, et al. Endoscopic butterfly cartilage myringoplasty. *Acta Otolaryngol* 2016;136:144-8.