



Clinico-radiological parameters predicting early diagnosis of foreign body aspiration in children

Çocuklarda yabancı cisim aspirasyonu erken tanısını öngören klinik-radyolojik parametreler

Pradipta Kumar Parida, MD., Nirmal Shanmugasundaram, MD., Surianarayanan Gopalakrishnan, MD.

Department of Otolaryngology, Jawaharlal Institute of Postgraduate Medical Education and Research, Pondicherry, India

ABSTRACT

Objectives: This study aims to investigate clinical and radiological findings to make early diagnosis of foreign body (FB) aspiration in children.

Patients and Methods: This prospective study was conducted on 45 children younger than 12 years with a clinical diagnosis of FB aspiration undergone rigid bronchoscopy between September 2010 and May 2014. The results of 37 children (22 males, 15 females; mean age 2.6 years; range 1 to 12 years) with positive for FB on bronchoscopy were analyzed.

Results: Penetration syndrome (sudden onset coughing, choking and gagging) (89.2%) and decreased breath sounds (86.5%) were the most common clinical features. Cough, respiratory difficulty and fever were present in 83.8%, 78.4% and 27% respectively. Tachypnea, tachycardia, chest retractions, decreased chest movements and wheeze were present in 83.3%, 83.3%, 83.3%, 51.4% and 43.2% respectively. Unilateral hyperinflation (64.9%), mediastinal shift (45.9%), and collapse (21.6%) were common radiological signs on chest radiography and in 13.5% patients the chest X-rays were normal. Sites of FB lodgements were larynx, trachea, right main bronchus, left main bronchus and bilateral bronchi in 10.8%, 10.8%, 35.1%, 37.8 and 5.5% respectively. Food related FBs were present in 30 cases (peanut 54.1%) and inorganic FBs were present in seven cases.

Conclusion: Penetration syndrome, localized decreased breath sounds, unilateral hyperinflation and/or mediastinal shift on radiology are predictors for early diagnosis of FB aspiration.

Keywords: Bronchoscopy; bronchus; foreign bodies; foreign body aspiration.

ÖZ

Amaç: Bu çalışmada çocuklarda yabancı cisim (YC) aspirasyonu erken tanısı için klinik ve radyolojik bulgular araştırıldı.

Hastalar ve Yöntemler: Bu prospektif çalışma Eylül 2010 - Mayıs 2014 tarihleri arasında, YC aspirasyonu klinik tanısı ile rijid bronkoskopi uygulanan 12 yaşından küçük 45 çocuk ile yürütüldü. Otuz yedi YC pozitif çocuğun sonuçları (22 erkek, 15 kız; ort. yaş 2.6 yıl; dağılım 1-12 yıl) bronkoskopi ile analiz edildi.

Bulgular: Penetrasyon sendromu (ani başlangıçlı öksürük, boğulma ve tıkanma) (%89.2) ve azalmış solunum sesleri (%86.5) en sık görülen klinik özelliklerdi. Öksürük, solunum zorluğu ve ateş sırasıyla %83.8, %78.4 ve %27 idi. Takipne, taşikardi, göğüs çekilmeleri, azalmış göğüs hareketleri ve hırıltı sırasıyla %83.3, %83.3, %83.3, %51.4 ve %43.2 idi. Tek taraflı hiperinflasyon (%64.9), mediastinal şift (%45.9) ve çökme (%21.6) akciğer grafisinde ve göğüs röntgenlerinde ortak radyolojik bulguları ve hastaların %13.5'inin akciğer filmi normaldi. Yabancı cisim yerleşim yerleri gırtlak, soluk borusu, sağ ana bronş, sol ana bronş ve iki taraflı bronşlarda sırasıyla %10.8, %10.8, %35.1, %37.8 ve %5.5 idi. Gıda ile ilgili YC'ler 30 olguda (yer fıstığı %54.1) ve inorganik YC yedi olguda mevcuttu.

Sonuç: Penetrasyon sendromu, lokalize solunum sesleri azalması, tek taraflı hiperinflasyon veya radyolojide mediastinal şift YC aspirasyonu erken tanısı için gösterge niteliğindedir.

Anahtar Sözcükler: Bronkoskopi; bronş; yabancı cisimler; yabancı cisim aspirasyonu.



Foreign body (FB) in the pediatric airway will end in complications including death if not diagnosed and removed promptly.^[1] The most important aspect of diagnosis of FB aspiration is to suspect this possibility when an afebrile and playful child presents with sudden-onset airway symptoms. Diagnosis of FB aspiration is not always straightforward as there are various conditions like bronchial asthma, pneumonia and upper and lower respiratory tract infections that may resemble FB aspiration and vice versa.^[2] A complete history, meticulous physical examination, radiography and prompt evaluation by bronchoscopy can avoid most morbidities and mortality associated with FB aspiration. In this study, we describe and analyze the clinical and radiological features that help in diagnosis of FB aspiration in children.

PATIENTS AND METHODS

The study was conducted on 45 children in a tertiary care teaching hospital between September 2012 and May 2014 after obtaining institutional ethics committee approval. Written informed consent was obtained from the parents of each patient. The study was conducted in accordance with the principles of the Declaration of Helsinki. Inclusion criteria were children below 12 years of age who presented with history of FB aspiration and/or were suspected to have aspirated FB on the basis of clinical signs and/or radiological examination. All the children were admitted to the emergency pediatric department and observed in the intensive care unit. Blood pressure, pulse rate, respiratory rate and temperature including SpO₂ were monitored. History and symptoms of aspiration, cough, noisy breathing, change in voice, respiratory distress in the form of increased rate of breathing, fever, purulent expectoration, and expulsion of inhaled bits, chest pain and hemoptysis were asked for and noted. Features such as pulse rate, blood pressure, respiratory rate, stridor, intercostal and subcostal retraction, chest movements, bilateral air entry on auscultation were examined and noted. Appropriate resuscitative measures were undertaken whenever necessary. All children except one underwent chest X-ray (posteroanterior, right and left oblique views) and neck soft tissue X-ray (anteroposterior and lateral views). Children in respiratory distress,

not maintaining O₂ saturation, cyanosis and suspected laryngeal or tracheal FB underwent emergency bronchoscopy while elective bronchoscopy was done for others at the earliest possible date. All patients received intravenous antibiotics and steroids. All bronchoscopies and FB removals were performed under general anesthesia. Appropriate sizes of rigid ventilatory bronchoscopes (Karl Storz, Tuttlingen, Germany) and forceps were used for FB removal. All patients were observed in the intensive care unit postoperatively. All patients showed symptomatic improvement after FB removal. Repeat chest radiographs were taken six hours after the procedure. Nebulized bronchodilators, intravenous antibiotics and steroids were continued in the postoperative period for variable length of time depending upon the clinical and radiological recovery of the children. The patients were discharged from the hospital once they were stable and had no signs of respiratory distress.

Forty-five children suspected to have aspirated FB underwent rigid bronchoscopy. Foreign bodies were retrieved from the airways of 37 children but in eight children no FB was found during bronchoscopy. The results of these 37 children (22 boys, 15 girls; mean age 2.6 years; range 1 to 12 years) with positive for FB on bronchoscopy were analyzed.

RESULTS

The mean duration of FB aspiration was 6.9 days, ranging from a few hours to 90 days. The children presented with various complaints. The most common presenting complaints were history of aspiration, cough and respiratory difficulty in the form of increased rate of breathing and chest in-drawing. An important history in children with FB aspiration is the symptom complex of sudden-onset coughing, choking and gagging when the child has something in the mouth (penetration syndrome). This was present in 33 children. In those without a history of penetration syndrome FB aspiration was suspected on the basis of other symptoms, physical signs, radiological signs and flexible bronchoscopy. Two patients had hoarse cry and voice and both these patients had FB lodged in the larynx. One of these patients also had intermittent stridor. Table 1 shows the different presenting symptoms in our study.

Table 1. Symptoms of foreign body aspiration

Symptoms	No. of cases	%
History of aspiration (Penetration syndrome)	33	89.2
Cough	31	83.8
Respiratory difficulty	29	78.4
Fever	10	27
Change in voice	3	8.1
Noisy breathing	3	8.1
Poor feeding	1	2.7
Seizures	2	5.4
Drowsiness	1	2.7
Neck and chest swelling (surgical emphysema)	1	2.7
Asymptomatic	3	8.1
Whistling sound on breathing	1	2.7

Thirty-six out of 37 patients had at least one abnormal examination finding. A four-year-old child who had aspirated a pen cap had no findings on physical examination and his chest X-ray was also normal. Tachycardia and tachypnea were present in 31 patients and 10 children had raised temperature at the time of admission. Blood pressure was normal for all children. Decreased breath sounds on auscultation was the most common finding, manifesting in 32 patients (86.5%). Subcutaneous emphysema involving the anterior chest and neck was found in one patient, and gradually subsided over five days postoperatively. Three patients had respiratory arrest and two had seizure episodes preoperatively. All these three patients were intubated and ventilated before being taken for bronchoscopy. Palpatory thud was present in two cases. Physical signs elicited in our study are shown in Table 2.

Radiological findings

The most common radiological finding was hyperinflation and it was recorded in 24 cases. The other findings on chest radiography were mediastinal shift, collapse, consolidation, infiltrates and shifting signs (Figure 1, 2). Radiopaque FBs were found in four patients-- two were metallic (screw and nail), one was a chiku seed seen on anteroposterior neck radiograph and the other was a brick piece. Five patients had normal chest radiograph findings. Various radiological changes in our study are shown in Table 3.

Bronchoscopic findings

Foreign bodies removed during rigid bronchoscopy included both vegetable and non-vegetable materials. The most common FB was peanut being present in 20 patients (54.1%) (Figure 3). The other FBs included betel nut,

Table 2. Physical findings

Physical sign	n	%
Decreased breath sound	32	86.5
Tachypnea	31	83.8
Tachycardia	31	83.8
Chest retractions	31	83.8
Decreased chest movement	19	51.4
Wheeze	16	43.2
Crepitations	5	13.5
Hoarse voice	2	5.4
Stridor	3	8.1
Subcutaneous emphysema	1	2.7

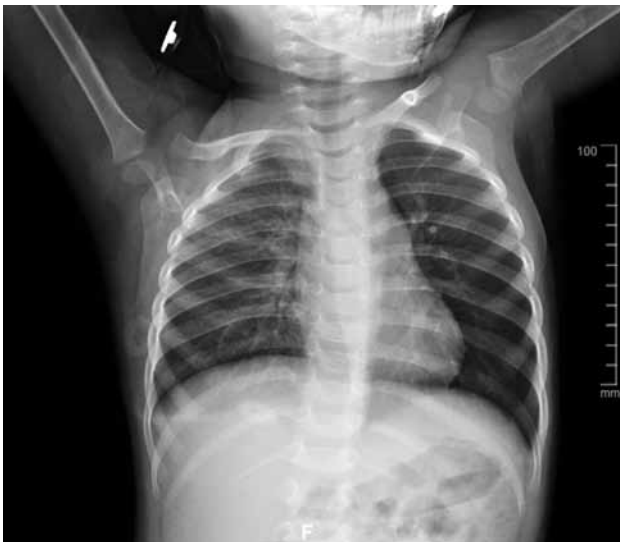

Figure 1. Chest X-ray showing hyperinflation on left side.

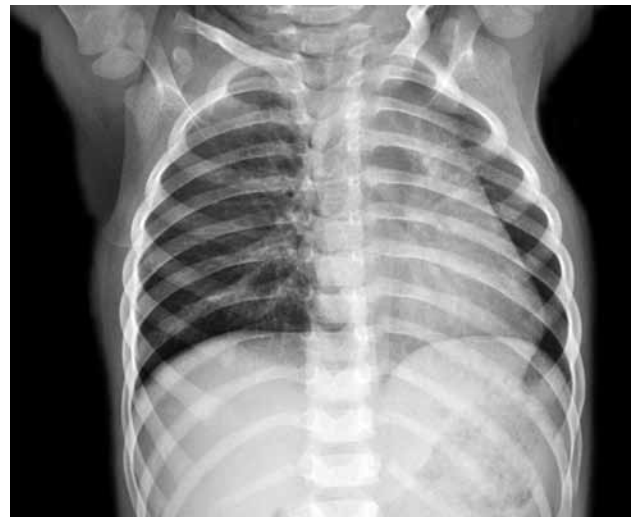

Figure 2. Chest X-ray showing hyperinflation on right side with shift of mediastinum to left side.

orange seed, rice grain, chiku seed, tamarind seed, bengal gram, coconut piece, part of a tuber in one case each and unknown organic substance in two cases. Non-food related FBs like whistle, earring, brick piece, screw, nail, plastic piece, stone and pen cap were present in one case each (Figure 4, 5). Foreign bodies were removed from the larynx, trachea, right main bronchus, left main bronchus and bilateral bronchi in four (10.8%), four (10.8%), 13 (35.1%), 14 (37.8) and two (5.5%) children respectively (Figure 6). In two patients, multiple fragments of peanut were found in both main bronchi. Except for these cases, all other FBs were single. During rigid bronchoscopy the surrounding mucosal changes varied from no mucosal changes to florid granulations that were present in three cases.

Postoperative complications

No serious complications or deaths occurred in our study. Persistent cough was found in 14 patients (37.8%) and subsided in all cases with intravenous antibiotics and bronchodilators by the second postoperative day. Hoarseness was found in one patient who had a peanut in the left main bronchus. This particular patient had florid granulation surrounding the FB and had a prolonged bronchoscopy time.

One patient had consolidation of the right upper lobe that resolved in two weeks with antibiotics. The other patient had persistent collapse of the left upper lung that recovered by the fifth postoperative Day with conservative management. These two patients had long-standing FB surrounded by granulations.

Table 3. Chest radiographs findings

Radiological findings	n	%
Hyperinflation	24	64.9
Mediastinal shift	17	45.9
Collapse	8	21.6
Normal X-ray	5	13.5
Consolidation	4	10.8
Radiopaque foreign bodies	4	10.8
Infiltration	4	10.8
Shifting sign	4	10.8
Not taken	1	2.7

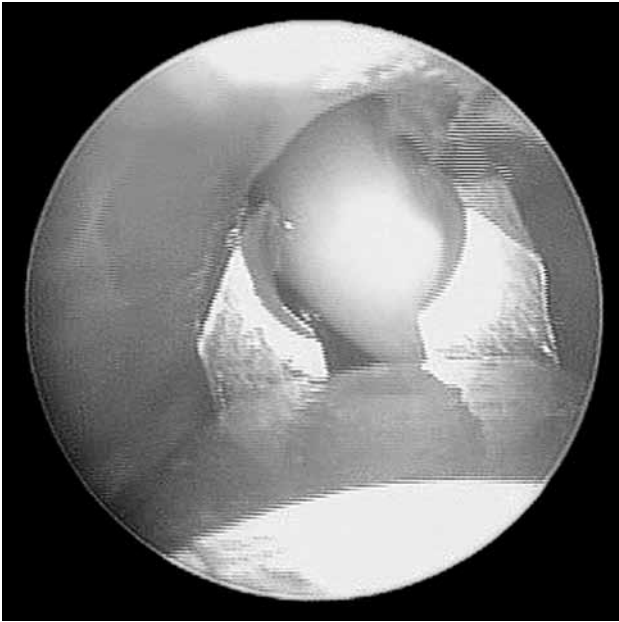


Figure 3. Video-bronchoscopic picture showing removal of foreign body (peanut) from left main bronchus using optical forceps.

DISCUSSION

Children in the age group of 1-3 are most susceptible to FB aspiration.^[1,3] In our study 86.5% of children were in the 1-3 years age group. Mouthing behavior in infants and young children, absence of molar teeth, incoordination in swallowing reflex and talking with something in the mouth can explain this age predominance.^[4,5] Children with FB

aspiration present with a number of symptoms from a definite history of aspiration followed by respiratory distress to totally nonspecific symptoms without any choking episodes.^[5,6]

A witnessed episode of choking is an important piece of historical evidence in the diagnosis of FB aspiration. Eliciting this history is vital to diagnosis of FB aspiration and to prevent any delay in diagnosis. This history was present in 56 to 87% of cases in various reported series.^[7,8,9] In our study this episode of choking suggestive of aspiration was present in 33 patients (89%). All children presenting with sudden-onset respiratory symptoms should be asked for a history suggestive of aspiration. However a positive history of choking may be misleading in some cases of respiratory illness that are not due to FB aspiration. An unnoticed FB aspiration and initial nonspecific symptoms may contribute to late diagnosis.^[10-13] Apart from a positive history of aspiration, the next most common symptom in our study was cough (83.8%) followed by respiratory distress (78.4%). In other studies cough was reported in varying proportions of patients (77%, 82.5%, 30.5%, 100%).^[7,8,9,12] Respiratory distress was present in 25%^[7] and 49.4%^[8] in other studies. Severe respiratory obstruction can lead to hypoxia and seizures as seen in two of our patients. A history of voice change is highly suggestive

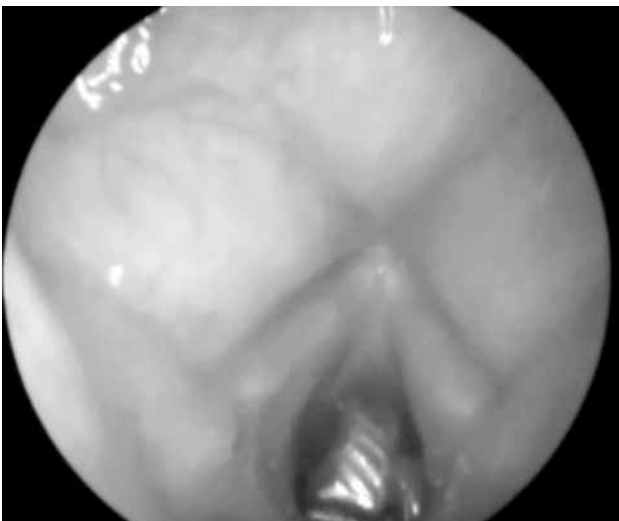

Figure 4. Video-laryngoscopic picture showing an earring in the subglottis.

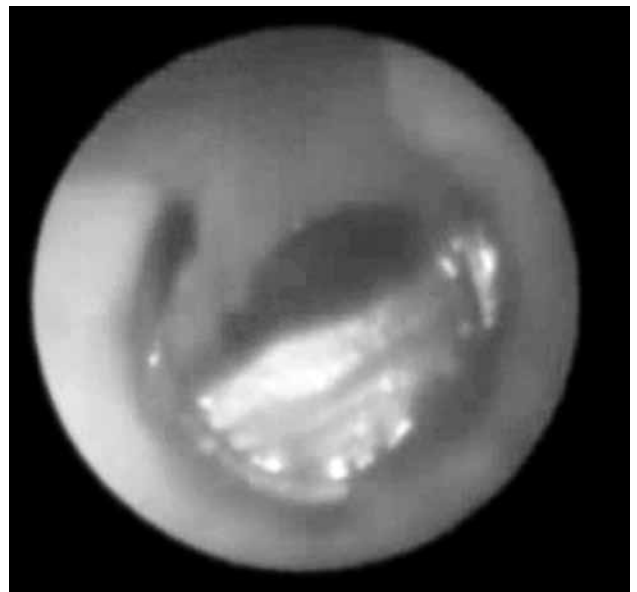


Figure 5. Video-bronchoscopic picture showing a foreign body (whistle) in the left main bronchus.

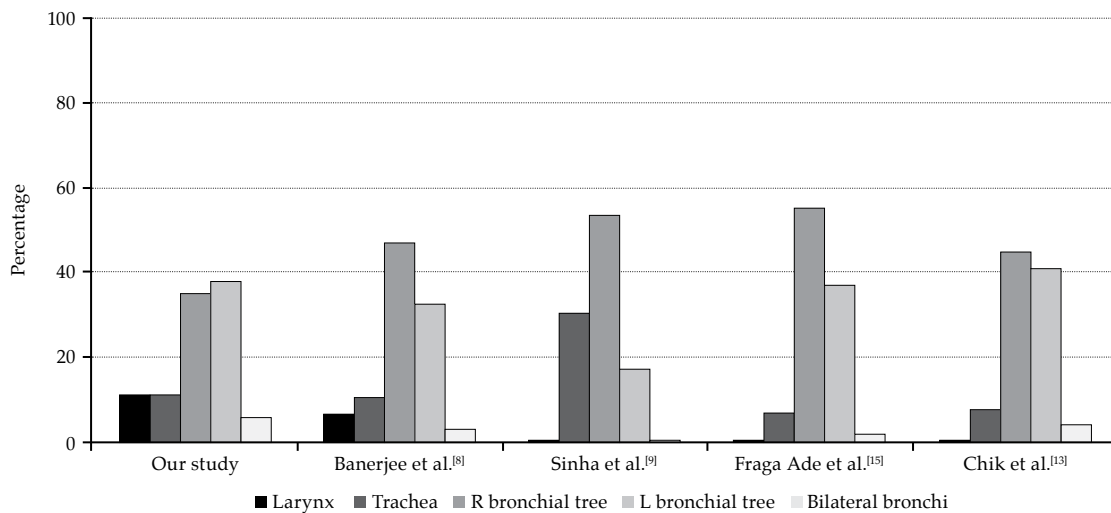


Figure 6. Comparison between our study and other studies regarding the site of foreign bodies in the airway.

of laryngeal FB. Children can present with no respiratory symptoms and only a history of a choking episode. Diagnosis in these children depends on physical findings and radiological changes. Hemoptysis (0.9%),^[8] expulsion of inhaled bits of FB (1.8%),^[8] postural dyspnea (4.9%),^[8] halitosis (1.4%),^[14] vomiting (10%),^[14] and purulent expectoration (4.7%)^[8] have been described as symptoms of FB aspiration.^[8,9,14] We did not encounter any patient with these symptoms in our study. In our study the most common physical finding was ipsilateral decreased breath sounds on auscultation in 86.5% of patients. This was followed by tachypnea (83.8%) and chest retractions (83.8%).

Stridor was present in three of our patients (8.1%). Fever was documented in 10 of our patients (27%). Varied incidence of decreased air entry (50%,^[15] 66.7%,^[12] 39.1%^[14]), tachypnea (67%,^[8] 40.1%^[12]), stridor (50%,^[15] 22.2%^[12]), decreased chest movements (33.3%^[15]) and crepitations (10%,^[15] 14.8%^[12]) have been reported physical findings in cases of FB aspiration. Progressive subcutaneous emphysema is an unusual clinical feature in FB aspiration^[16-19] The causes of pneumomediastinum with or without subcutaneous emphysema over the neck and chest include asthma, respiratory infection, pharyngeal or esophageal injury, cystic fibrosis, trauma, diabetes and leukemia.^[17] While asthma and respiratory infection are the most common non-traumatic causes, FB aspiration which can

resemble these two conditions can also present with subcutaneous emphysema.^[17] Subcutaneous emphysema and pneumomediastinum occur due to any condition that creates a gradient between intra-alveolar and perivascular interstitial pressures. A continuum of fascial planes connects cervical soft tissues with the mediastinum and retroperitoneum, permitting aberrant air arising in any one of these areas to spread elsewhere.^[18]

The spectrum of findings in a chest radiograph includes normal X-ray, typical of FB aspiration and uncharacteristic findings.^[5] The presence of a normal radiograph depends on type, site of FB lodgment and time of diagnosis. Normal radiographs are more common in non-vegetable FBs, tracheal FBs and FBs diagnosed early.^[5] In our study a normal chest x-ray was found in five patients (13.5%).

Zerella et al.^[5] reported normal chest x-ray in 42% of bronchial FBs and 81% of tracheal FBs. The rates of normal chest radiograph in various studies are 6.1%,^[8] 50%,^[15] 22.2%,^[12] and 22%^[13] Unilateral air trapping (hyperinflation), atelectasis or infiltrates are said to be characteristic of FB aspiration apart from finding a radiopaque FB.^[5,20] Findings such as bilateral pneumonia, bilateral emphysema, upper lobe atelectasis and pneumonia are uncharacteristic of FB aspiration.^[5] The most common radiological sign associated with FB aspiration differs among the various studies. Sinha et al.^[15] reported mediastinal shift (33%) as the most common

radiological sign followed by atelectasis (17%) in a study of 30 cases. Obstructive emphysema was found to be the most common radiological sign by Banerjee et al.^[8] (41.2%), Roda et al.^[13] (42%), Chik et al.^[12] (51.9%) and Narasimhan et al.^[9] (69.3%). Unilateral atelectasis was found to be the most common sign in 38.8% in a Brazilian study of 69 patients.^[14] Shifting radiological finding was found in four of our patients (10.8%) and three patients had bilateral hyperinflation (8.1%). Shifting FBs cause changes in the patterns of obstruction and the interplay between this and underlying inflammatory response leads to changing radiological signs.

Rigid bronchoscopy is the gold standard in the diagnosis and treatment of FB aspiration. "Do not fail to search for a FB endoscopically in all cases of doubt" said Chevalier Jackson who through meticulous analysis of mechanical problems related to FBs in the air and food passages and their solution, created a science of rehearsed and tested instrumental techniques for their extraction. He developed instruments to achieve remarkable results with an almost unbelievably low morbidity and mortality.^[1] Mantor et al.^[4] proposed that some negative bronchoscopies are necessary in order to prevent the morbidity that occurs from a missed FB aspiration.^[4] Until X-ray examination, physical examination, indirect examination and endoscopy have all proven negative, a patient should not be informed that there is no FB in the airway.

Subglottic, carinal and bilateral FBs were associated with difficult removal during rigid bronchoscopy.^[9] In small infants the lumen of a 2.5 mm bronchoscope may not provide adequate vision for the FB to be removed without causing injury to the bronchus.^[8] A large vegetable FB (tamarind seed) may swell and pose difficulty during removal and warrant a tracheostomy.^[9] A similar case of tamarind seed in the left main bronchus was successfully removed by rigid bronchoscopy in our study. The most common site of FB in the airway in our study was the left side of the bronchial tree (37.8%) whereas other studies reported the right side to be more common. On the basis of tracheobronchial anatomy, an inhaled FB is more likely to enter the right bronchial tree than the left in all ages. However, variability in the position of the carina with respect to the mid-trachea may explain

why this right-sided preference is less marked in children compared to adults.^[10] Figure 1 shows the comparison between our study and some other studies regarding the site of FBs in the airway.

Complications following FB aspiration and bronchoscopy include pneumonia, atelectasis, tracheal laceration, vocal cord injury, pneumothorax, tracheitis, bronchitis, cardiorespiratory arrest and death.^[3,9] The complication rate of rigid bronchoscopic removal of airway FBs has been reported as 5%,^[6] 29%,^[13] and 33.3%.^[3] Zerella et al.^[5] reported three patients with serious complications due to FB aspiration and bronchoscopy in a study involving 293 children. These are vocal cord injury, tracheal laceration and severe subglottic edema.^[5] Repeat bronchoscopy rates in various studies are 0.03%^[9] and 0.02%.^[3] Chik et al.^[12] reported a repeat bronchoscopy rate of 14% in a study involving 27 cases. None of the patients in our study required repeat bronchoscopy. In a study of 69 Brazilian children, 29% presented complications (most commonly pneumonia), which were found to be associated with longer aspiration time. Mechanical ventilation was required in seven children (10.1%), and multiple bronchoscopies were performed in five (7.2%). The other complications that were described in this study include atelectasis, barotrauma, tracheal laceration and granulomatous stenosis.^[14] Mortality due to FB aspiration and its treatment is 0.04%,^[9] 0.01%^[3] and 0.9%.^[8]

Chung et al.^[21] reported the factors affecting postoperative pulmonary recovery in pediatric patients undergoing bronchoscopic removal of FBs. More than one week for the complete pulmonary recovery was required in 25 (25.5%) cases, whereas 74.5% of subjects fully recovered within one week after the removal of FB. The recovery time of more than one week after rigid bronchoscopic retrieval of airway FB was associated with preoperative inflammatory findings by radiological study, a prolonged procedure over 50 minutes, and aggravation of the immediate postoperative radiological findings. Therefore, long-term pulmonary care is required for this group of patients.^[21] According to Roh et al.^[11] delayed lung recovery after rigid bronchoscopic removal of tracheobronchial FBs can be predicted by FB induced inflammatory

chest radiological findings and the unsuccessful or complicated removal of FBs.

In conclusion, FB aspiration is an important cause of acute respiratory morbidity in children. Children most commonly aspirate common foodstuff. A history of the "penetration syndrome" symptom complex or sudden onset of paroxysmal cough is a definite pointer towards diagnosis. Clinical findings in FB aspiration may be variable and mostly include decreased breath sounds, tachypnea, chest retraction and decreased chest movements. Radiological evaluation is useful with changes such as hyperinflation, mediastinal shift and collapse. Rigid bronchoscopy is safe and effective for removal of airway FBs in children.

Declaration of conflicting interests

The authors declared no conflicts of interest with respect to the authorship and/or publication of this article.

Funding

The authors received no financial support for the research and/or authorship of this article.

REFERENCES

1. Jackson C, Jackson CL. Diseases of the air and food passages of foreign body origin. Philadelphia: W.B Saunders Co; 1936.
2. Svedström E, Puhakka H, Kero P. How accurate is chest radiography in the diagnosis of tracheobronchial foreign bodies in children? *Pediatr Radiol* 1989;19:520-2.
3. Steen KH, Zimmermann T. Tracheobronchial aspiration of foreign bodies in children: a study of 94 cases. *Laryngoscope* 1990;100:525-30.
4. Mantor PC, Tuggle DW, Tunell WP. An appropriate negative bronchoscopy rate in suspected foreign body aspiration. *Am J Surg* 1989;158:622-4.
5. Zerella JT, Dimler M, McGill LC, Pippus KJ. Foreign body aspiration in children: value of radiography and complications of bronchoscopy. *J Pediatr Surg* 1998;33:1651-4.
6. Black RE, Johnson DG, Matlak ME. Bronchoscopic removal of aspirated foreign bodies in children. *J Pediatr Surg* 1994;29:682-4.
7. Wiseman NE. The diagnosis of foreign body aspiration in childhood. *J Pediatr Surg* 1984;19:531-5.
8. Banerjee A, Rao KS, Khanna SK, Narayanan PS, Gupta BK, Sekar JC, et al. Laryngo-tracheo-bronchial foreign bodies in children. *J Laryngol Otol* 1988;102:1029-32.
9. Narasimhan KL, Chowdhary SK, Suri S, Mahajan JK, Samujh R, Rao KLN. Foreign body airway obstructions in children- lessons learnt from a prospective audit. *J Indian Assoc Pediatr Surg* 2002;7:184-9.
10. Tahir N, Ramsden WH, Stringer MD. Tracheobronchial anatomy and the distribution of inhaled foreign bodies in children. *Eur J Pediatr* 2009;168:289-95.
11. Roh JL, Hong SJ. Lung recovery after rigid bronchoscopic removal of tracheobronchial foreign bodies in children. *Int J Pediatr Otorhinolaryngol* 2008;72:635-41.
12. Chik KK, Miu TY, Chan CW. Foreign body aspiration in Hong Kong Chinese children. *Hong Kong Med J* 2009;15:6-11.
13. Roda J, Nobre S, Pires J, Estêvão MH, Félix M. Foreign bodies in the airway: a quarter of a century's experience. *Rev Port Pneumol* 2008;14:787-802.
14. Fraga Ade M, Reis MC, Zambon MP, Toro IC, Ribeiro JD, Baracat EC. Foreign body aspiration in children: clinical aspects, radiological aspects and bronchoscopic treatment. *J Bras Pneumol* 2008;34:74-82.
15. Sinha V, Memon R, Gupta D, Prajapati B, Bhat V, More Y. Foreign body in tracheobronchial tree. *Indian J Otolaryngol Head Neck Surg* 2007;59:211-4.
16. Saki N, Nikakhlagh S, Rahim F, Abshirini H. Foreign body aspirations in infancy: a 20-year experience. *Int J Med Sci* 2009;6:322-8.
17. Findlay CA, Morrissey S, Paton JY. Subcutaneous emphysema secondary to foreign-body aspiration. *Pediatr Pulmonol* 2003;36:81-2.
18. Maunder RJ, Pierson DJ, Hudson LD. Subcutaneous and mediastinal emphysema. Pathophysiology, diagnosis, and management. *Arch Intern Med* 1984;144:1447-53.
19. Saoji R, Ramchandra C, D'Cruz AJ. Subcutaneous emphysema: an unusual presentation of foreign body in the airway. *J Pediatr Surg* 1995;30:860-2.
20. Paşaoğlu I, Doğan R, Demircin M, Hatipoğlu A, Bozer AY. Bronchoscopic removal of foreign bodies in children: retrospective analysis of 822 cases. *Thorac Cardiovasc Surg* 1991;39:95-8.
21. Chung MK, Jeong HS, Ahn KM, Park SH, Cho JK, Son YI, et al. Pulmonary recovery after rigid bronchoscopic retrieval of airway foreign body. *Laryngoscope* 2007;117:303-7.