

## DOES THE NEGATIVE PRESSURE DRESSING REMOVE THE NECROTIC PARTS OF THE WOUNDS? A HISTOPATHOLOGICAL EVALUATION OF WOUND FLUID

### NEGATİF BASINÇLI PANSUMAN YARALARIN NEKROTİK KISIMLARINI AYIRIR MI? YARA SIVISININ HİSTOPATOLOJİK DEĞERLENDİRMESİ

\*Nazım Gümüş, \*Sarper Yılmaz, \*\*Ahmet Cennet

\*Cumhuriyet Üniversitesi Tıp Fakültesi, Plastik, Rekonstrüktif ve Estetik Cerrahi Anabilim Dalı, SİVAS

\*\*Adana Numune Eğitim ve Araştırma Hastanesi Patoloji Kliniği

#### ABSTRACT

**Introduction:** Wound fluid collected in the container of the negative pressure dressing system was examined histopathologically to reveal detailed information about cellular and liquid components of it.

**Materials and Methods:** This study included six wounds of six patients who had injured with electrical burn, traffic accident and scald burn. All of the wounds were debrided surgically to viable-appearing tissue and then a negative pressure dressing was applied to the wounds. Then, the wound fluid collected in the container of the dressing system and its components were examined histopathologically under light microscope.

**Results:** Evaluation of all specimens revealed that the content of the samples was including exudate, fibrin, nonviable epithelial cells and fibrocytes, cell remnants such as nucleus or cell membrane, but no viable tissue or cell.

**Conclusions:** Negative pressure dressing may be considered as a tool for the debridement of wounds which involve bacterial colonization, exudate, particles or insignificant tissue necrosis.

**Keywords:** debridement; negative pressure; dressing; wound; fluid

#### ÖZET

**Giriş:** Negatif basınçlı pansuman sistemi toplayıcısında biriken yara sıvısının hücresel ve sıvı kısımları hakkında ayrıntılı bilgi elde etmek için histopatolojik olarak inceleme yapıldı.

**Gereç ve Yöntem:** Bu çalışma elektrik yanığı, haşlanma, trafik kazası nedeniyle ile yaralanmış altı hastanın altı yarasını kapsadı. Tüm yaralar canlı görünen dokuya kadar cerrahi olarak debride edildi. Bu yaralara düşük basınçlı pansuman uygulandı ve yara sıvısı pansuman sisteminin toplayıcısında biriktirildi. Sıvı ve onun bileşenleri ışık mikroskobu altında histolojik olarak değerlendirildi.

**Bulgular:** Örneklerin değerlendirilmesi, içeriğin eksuda, fibrin, ölü epitel hücreleri ve fibrositler, çekirdek veya hücre zarı gibi hücresel artıklardan oluştuğunu, fakat hiç canlı hücre ve doku içermediğini açığa çıkardı.

**Sonuçlar:** Bu mikroskopik bulguların değerlendirilmesinden, negatif basınçlı pansumanın bakteriyel birikme, eksuda, parçacık ve belirgin olmayan doku nekrozu içeren yaraların debridmanı için bir araç olarak kullanılabileceğini düşündürmektedir.

**Anahtar Sözcükler:** debridman, düşük basınç, pansuman, sıvı, yara

## INTRODUCTION

During the use of negative pressure dressing, mechanical tension which is produced by subatmospheric pressure, leads to rapid wound healing by removal of interstitial edema and increase in local blood flow. It not only promotes cellular proliferation and regeneration, but also optimizes microperfusion, increasing the partial oxygen pressure within the wound<sup>1-4</sup> Therefore, it is known to be beneficial for the management of various traumatic and nontraumatic soft tissue defects.<sup>2-5</sup>

A vacuum pump as a part of negative pressure dressing, produces controlled continuous or intermittent subatmospheric pressure.<sup>1,2</sup> In the continuous mode, negative pressure is usually maintained at 100 or 125 mmHg during 48-72 hours, and then when dressing is being changed, wound encounters with atmospheric pressure again. In using the pump with intermittent su-

batmospheric pressure, wound exposes to atmospheric and subatmospheric pressure regularly, because of the alternating pressure cycle of the suction pump. These two types of subatmospheric pressure affect differently on the wound surface.

While dressing is in place, wound fluid is actively collected into a container, which may consist of exudate, cloths, foreign bodies, bacteria, necrosis, tissue remnants and debris. Although wound fluid has been investigated for its humoral components such as growth factors, proteins, inflammatory mediators, chemoattractants and cytokines, histopathological evaluation of it has not been performed in the literature yet. In this study, wound fluid collected by negative pressure dressing was examined histopathologically to find out detailed information about the cellular and liquid components of it.

## MATERIAL AND METHODS

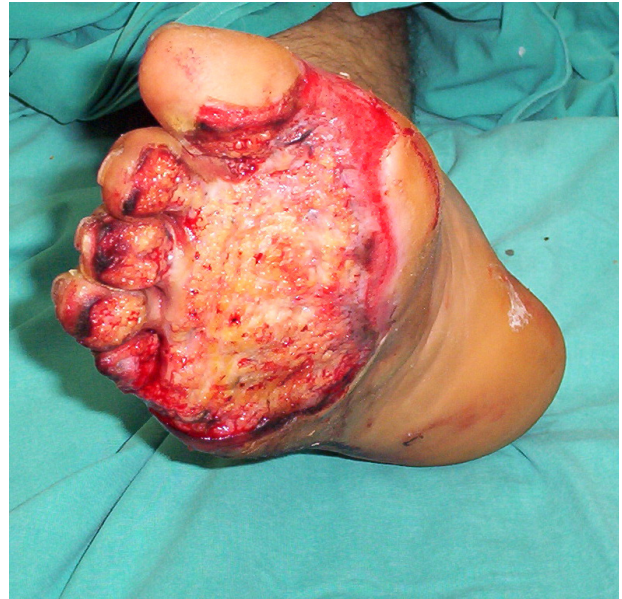This study included six wounds of six patients who were injured with electrical burn, traffic accident and scald burn. Locations of the wounds were on foot, abdomen, head, hand and arm. All of the wounds were debrided surgically to viable-appearing and bleeding tissue in order to remove whole necrosis, cloths, particles and foreign bodies. After meticulous hemostasis, a negative pressure dressing was applied to the wounds which appeared clean and viable without including significant necrosis (Figure 1a, b). Before the vacuum tube was attached to the container, 200 mL of formaldehyde was given into the container to preserve both the fluid and tissue particles which would come from the wound (Figure 1c). Later, the system was set to 125 mm Hg continuous pressure during 48 hours. After the dressing was removed, container of the system was opened in every patient after 48 hours. Liquid content of the container, which consisted of wound aspirate and formaldehyde, became a gel formation, so that it could be removed easily from the inside of the container. As particles of the wound fluid accumulated at the bottom of the content, histopathological specimens were taken particularly from this area which was capable of carrying information about both the liquid and cellular parts of the content.

## RESULTS

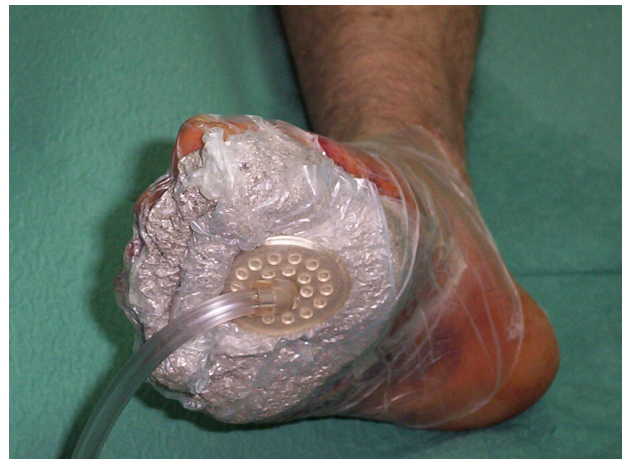Three samples were taken from every container to examine microscopically. Biopsy samples were fixed in 10% formaldehyde solution for 24 hours, embedded in paraffin, sectioned, and stained with routine haematoxyline eosin (HE) stain. Slides were evaluated under light microscope with the magnification of 100X and 200X to investigate the components of wound fluid. Examination of all specimens revealed that content of the samples involved exudate, fibrin, died epithelial cells and fibrocytes, and cell remnants such as nucleus and cell membrane, but no viable tissue or cell. Besides the gel content, wound fluid included necrotic tissue particles in all specimens. Any living tissue or cell was not found in the examinations (Figure 2a, b).

## DISCUSSION

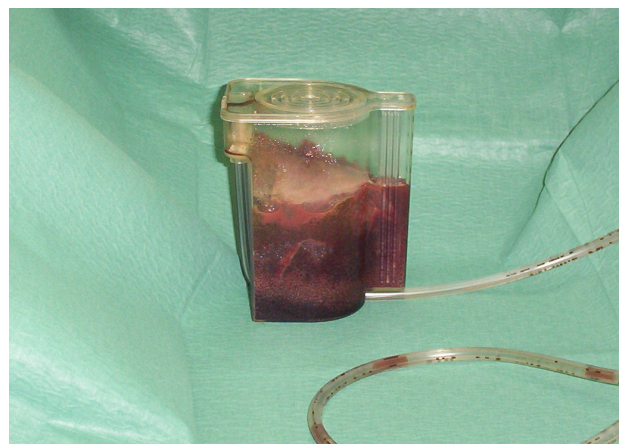As well known, none of the dressing types replaces the need of surgical debridement in the presence of significant necrosis, bacterial colonization and wound infection; however, dressing has an important complementary function in cleansing and protection of the wounds.<sup>1-3</sup> It may be considered as a mechanical and biological barrier between the wound and environment. All types of dressings can take out exudate, cloths, particles, foreign bodies, bacteria, tissue remnants and debris from the wounds gradually, eliminating their negative effects on wound healing. Apart from other dressing methods, negative pressure dressing makes those actively, possibly taking a shorter time than the others.



**Figure 1a.** Appearance of the right foot after extensive debridement of the deep necrosis due to high-voltage electrical injury. Note that excision of the necrosis was performed up to the viable-appearing and bleeding tissue without leaving significant necrosis.

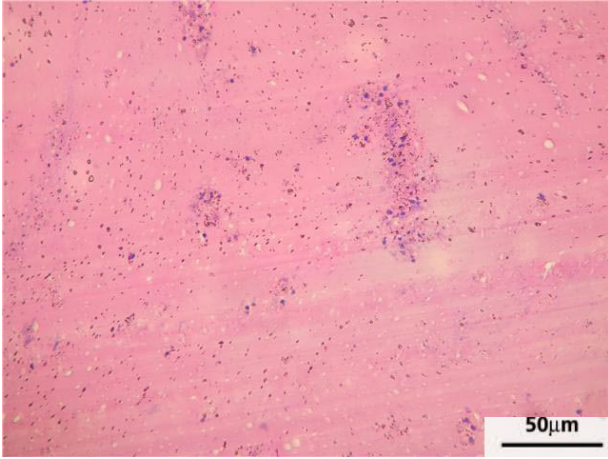


**Figure 1b.** View of the foot with the negative pressure dressing application.

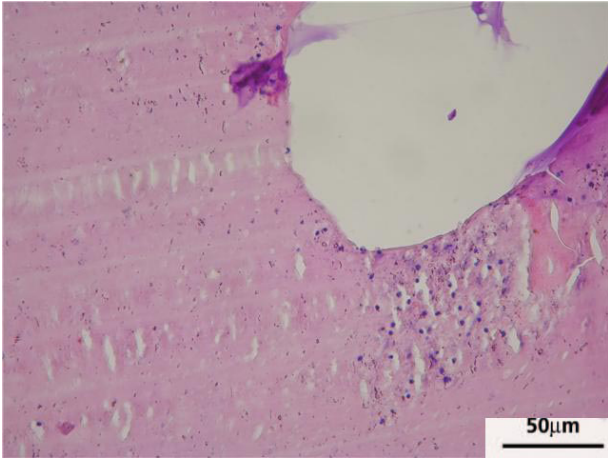


**Figure 1c.** Container of the negative pressure dressing 48 hours later the application. Note that 200 mL of formaldehyde was added to the container before starting the procedure to preserve fluid and tissue particles which would come from the wound.





**Figure 2a.** Microscopic view of the collected material, showing clearly exudate, fibrin, died epithelial cells and fibrocytes, cell remnants such as nucleus or cell membrane, and cells related to inflammation such as leukocytes (HE, x 100).



**Figure 2b.** Histopathological appearance of the fluid content of the container, showing full of necrosis without including any living tissue or cells. Note microscopic appearance of the gel content of the container which keeps fluids as a gel in the container. (HE, x 200).

As a rule, negative pressure dressing is applied to the wounds after the sufficient debridement, and then wound should be followed carefully under the dressing, because of the risk for the development of wound sepsis.<sup>3-5</sup> If necessary, debridement is performed again extensively.

Wound exudate has been investigated for revealing its compositions in many studies.<sup>6-9</sup> Minematsu described a biochemical tool for assessment of protein components in exudate of chronic wounds such as tumor necrosis factor  $\alpha$  and alkaline phosphatase.<sup>6</sup> Levels of wound fluid inflammatory mediators and matrix metalloproteases were also studied using multiplexed bead-based sandwich immunoassays.<sup>7</sup> Concentration of total protein, elastase, and plasmin was determined and besides gelatinase activity, matrix metalloproteinase-2 concentration was analyzed in the wound fluid.<sup>8</sup> Labner studied on the wound fluid collected with negative pressure dressing to measure the cytokines IL-6, IL-8, VEGF, and FGF-2.<sup>9</sup> However, histopathological findings

of wound exudate haven't been analyzed up to now. Simple observation of wound fluid collected into the container of negative pressure dressing suggests that wound exudate includes a large amount of necrosis, so in this study, this observational finding is supported by a microscopic evaluation. Although findings of this study weren't quantitative, and not suitable for statistical analyzes, they clearly revealed the necrotic content of wound exudate. Some of the damage to the wound cells may arise from negative pressure itself, possibly resulting in necrosis on the wound surface; but, this would be minimal and unpredictable in the whole necrosis.

Microscopic findings of wound fluid showed clearly that negative pressure dressing collected exudate and necrosis involving cellular remnants and tissue particles, but aspirate did not include any living cells or tissue components. It seems that this dressing is capable of separating necrosis, foreign bodies, cloths and debris from the viable tissue without damaging healthy tissue. In the presence of only bacterial colonization or contamination over the wound, negative pressure dressing may be considered as a useful tool to allow bacterial clearance with a suction force which leads to decrease in tissue bacterial levels resulting in better healing.<sup>1</sup> If there is no significant necrosis in the wound needing surgical debridement, subatmospheric pressure not only makes debridement of the microenvironment of the wounds, but also promotes cellular proliferation resulting in early healing.

Regarding these microscopic findings, negative pressure dressing may be considered as a tool for the debridement of particular wounds which involve bacterial colonization, exudate, particles or insignificant tissue necrosis and may be used as an adjunct to surgical debridement in wounds which may include minimal necrosis.

#### Dr. Nazım GÜMÜŞ

Cumhuriyet Üniversitesi Tıp Fakültesi

Plastik Rekonstrüktif ve Estetik Cerrahi Anabilim Dalı, SIVAS

E-posta: gumus1970@hotmail.com

**KAYNAKLAR**

1. Scherer SS, Pietramaggiore G, Mathews JC, Prsa MJ, Huang S, Or-gill DP. The mechanism of action of the vacuum-assisted closure device. *Plast Reconstr Surg*. 2008; 122: 786-97.
2. Braakenburg A, Obdeijn MC, Feitz R, Van Rooij IALM, Van Griethuysen AJ, Klinkenbijn JHG. The clinical efficacy and cost effectiveness of the vacuum-assisted closure technique in the management of acute and chronic wounds: a randomized controlled trial. *Plast Reconstr Surg*. 2006; 118: 390-7.
3. Labler L, Trentz O. The use of vacuum assisted closure in soft tissue injuries after high energy pelvic trauma. *Langenbecks Arch Surg*. 2007; 39: 601-9.
4. Argenta LC, Morykwas MJ, Marks MW, DeFranzo AJ, Molnar JA, David LR. Vacuum-Assisted Closure: State of Clinic Art. *Plast Reconstr Surg*. 2006; 117(S): 127-42.
5. Kamolz LP, Andel H, Haslik W, Winter W, Meissl G, Frey M. Use of subatmospheric pressure therapy to prevent burn wound progression in human: first experiences. *Burns*. 2004; 30: 253-8.
6. Minematsu T, Nakagami G, Yamamoto Y, Kanazawa T, Huang L, Koyanagi H, et al. Wound blotting: A convenient biochemical assessment tool for protein components in exudate of chronic wounds. *Wound Repair Regen*. 2013. 25.
7. Schmohl M, Beckert S, Joos TO, Königsrainer A, Schneiderhan-Marra N, Löffler MW. Superficial wound swabbing: a novel method of sampling and processing wound fluid for subsequent immunoassay analysis in diabetic foot ulcerations. *Diabetes Care*. 2012; 35(11):2113-20.
8. Ulrich D, Smeets R, Unglaub F, Wöltje M, Pallua N. Effect of oxidized regenerated cellulose/collagen matrix on proteases in wound exudate of patients with diabetic foot ulcers. *J Wound Ostomy Continence Nurs*. 2011;38(5):522-8.
9. Labler L, Rancan M, Mica L, Harter L, Mihic-Probst D, Keel M. Vacuum-assisted closure therapy increases local interleukin-8 and vascular endothelial growth factor levels in traumatic wounds. *J Trauma*. 2009;66(3):749-57.