

ULTRASONOGRAPHY GUIDED PERCUTANEOUS PLEURAL EFFUSION DRAINAGE IN NEONATES AND INFANTS: A SINGLE-CENTER EXPERIENCE

Yenidoğan ve İnfant Yaş Grubunda Ultrasonografi Kılavuzluğunda Perkütan Plevral Effüzyon Drenajı: Tek Merkez Deneyimi

Çağrı KESİM¹ , Özgür ÖZEN² 

¹Başkent University Faculty of Medicine, Konya Hospital, Department of Radiology, Interventional Radiology Section, KONYA, TURKEY.

²Başkent University Faculty of Medicine, Ankara Hospital, Department of Radiology, Interventional Radiology Section, ANKARA, TURKEY.

ABSTRACT

ÖZ

Objective: This study aimed to investigate the possible complications, outcomes and course of ultrasonography (USG)-guided percutaneous pleural effusion drainage (PEPED) treatment with underlying etiology of effusion in neonates and infants.

Material and Methods: In 31 patients aged 0-2 years hospitalized in the neonatal or pediatric intensive care unit, 45 catheters were inserted for USG-guided PEPED in a total of 40 sessions. Of these, a 6.3F 25 cm pigtail drainage catheter was inserted in 23 (57.5%) of our patients using the Seldinger method and in 17 (42.5%) using the trocar method. The sample fluid was biochemically classified as transudate, exudate, empyema and chylothorax. The duration of inserted catheter and type of fluid was studied along with etiological reasons for effusions.

Results: Of our 31 patients, 17 were male (54.8%) and 14 were female (45.2). The weeks of birth ranged from 25.1 to 41 weeks, with a mean of 35.55±4.22 weeks. The retention time of drainage catheters ranged from 1 to 18 days, with a mean of 6.5±4.02 days. We compared the retention time of inserted catheters between different preterm and mature groups. Besides, the various fluid characters in the postoperative patient group were compared in the context postoperative day period.

Conclusion: Catheter dwell time does not change with different levels of neonatal maturity. In neonates and infants with a history of surgery, the effusion transforms into chylothorax from hemothorax over time. Bedside USG-guided PEPED treatment for refractory pleural effusion in neonates and infants is highly safe and effective with low complication rates.

Amaç: Plevral efüzyon infant yaş grubunda ağır bir morbidite ve mortalite sebebi olup plevral efüzyonun en sık nedeni enfeksiyöz hastalıklardır. Ancak ameliyat sonrası dönem, kardiyak ve romatolojik etkenler de persistan plevral efüzyon nedenleri olabilir. Biz bu çalışmamızda ultrasonografi kılavuzluğunda perkütan plevral efüzyon drenajı tedavisinin seyrini, olası komplikasyonlarını ve sonuçlarını etiyojoloji ile bir arada değerlendirmeyi amaçladık.

Gereç ve Yöntem: 30 Nisan 2014 ile 30 Ağustos 2021 tarihleri arasında, 0-2 yaş grubunda olup yenidoğan veya pediatrik yoğun bakımda yatan 31 hastamıza toplam 40 seansta, USG kılavuzluğunda perkütan plevral efüzyon drenajı (PEPED) amacıyla 45 kateter takıldı. Bu hastalarımızdan 23'üne Seldinger yöntemiyle (%57.5), 17'sine trokar yöntemiyle (%42.5) 6,3F 25 cm pigtail drenaj kateteri takılmış olup gelen mayi biyokimyasal olarak transüda, eksüda, ampiyem ve şilotoraks olarak sınıflandırıldı. Kateterlerin takılı olduğu süreç, kaldığı gün sayısı ve mayi karakteri, etiyojolojik nedenlerle bir arada incelendi.

Bulgular: Otuz bir hastamızın 17'si erkek (%54.8), 14'ü kız (%45.2) idi. Doğum haftaları 25,1 – 41 arasında olup ortalama 35.55±4.22 idi. Takılan drenaj kateterlerinin kalış süresi 1-18 gün arasında olup ortalama 6.5±4.02 gün idi. Kateterlerin kalış süresini gruplar arasında kıyaslamak ve post-operatif hasta grubunda mayi karakteri ile post-operatif dönemde kateterin takıldığı gün arasında istatistiksel olarak anlamlı fark olup olmadığını görmek için normallik testlerini takiben Bağımsız Örneklem T-testi yapıldı.

Sonuç: İnfant yaş grubunda refrakter plevral efüzyon tedavisinin, özellikle aspirasyon veya medikasyon ile yeterli olmadığı durumlarda, perkütan plevral efüzyon drenajı amacıyla hasta başında USG kılavuzluğunda drenaj kateteri yerleştirmek son derece güvenli bir yöntem olup komplikasyon ihtimali son derece düşük ve oldukça etkili bir yöntemdir.

Keywords: Chylothorax, drainage catheter, infant, neonate, pleural effusion.

Anahtar Kelimeler: Şilotoraks, drenaj kateteri, infant, yenidoğan, plevral efüzyon



Correspondence / Yazışma Adresi :
Başkent University Faculty of Medicine, Konya Hospital, Department of Radiology, Interventional Radiology Section,
KONYA, TURKEY
Phone / Tel: +905300689777
Received/ Geliş Tarihi : 12.01.2022

Dr. Çağrı KESİM
Başkent University Faculty of Medicine, Konya Hospital, Department of Radiology, Interventional Radiology Section,
KONYA, TURKEY
E-mail / E-posta: cagrikesim@hotmail.com
Accepted / Kabul Tarihi: 01.07.2022

INTRODUCTION

A pleural effusion is an accumulation of fluid in various amounts and forms between the visceral and parietal pleura. It does not usually require invasive treatment unless the patient's respiratory function is impaired or there is severe flank pain and febrile symptoms. However, if the patient is at risk of entering a process such as sepsis due to its infectious nature, or if the patient's oxygen saturation is decreasing due to preexisting damage to the lung parenchyma, fluid drainage is required, even if the amount of fluid is low. In addition, biochemical, microbiological and cytological analysis of this fluid helps in the diagnosis, and the drainage itself contributes to the treatment of the patient.

Although an increase in pleural fluid is most commonly associated with pneumonia, (1) various cardiac diseases, liver problems, malignancies, and rheumatologic events can also cause an increase in pleural effusion. However, recurrent pleural effusions that do not respond to medical treatment can occur in a variety of diseases. Repeated aspiration of the effusion with a needle at frequent intervals increases the risk of complications and makes the treatment process more tedious for the patient (2). Continuous removal of the fluid formed in the pleural space during treatment maintains the lung capacity and facilitates the treatment process of the main problem (3-7). For this reason, placing a proper drainage catheter into the pleural effusion is essential for the well-being of the patient group in the treatment process (7).

Although it is possible to remove pleural effusion with appropriate antibiotic therapy or with simple thoracentesis for transude effusions, for more viscous pleural fluids, such as complicated parapneumonic effusions/empyema, replacement of a drainage catheter is the better option (8). It is necessary to insert an appropriate drainage catheter when treatment is prolonged or in cases of pleural collections such as hemothorax and chylothorax are involved (9).

This study aimed to explain our results on pleural effusion drainage catheters inserted under USG guidance at the bedside of patients aged 0-2 years admitted to our hospital's neonatal or pediatric intensive care unit. We evaluated the course and outcomes of treatment, compared the total dwell time of the catheters and their relationship with the gestational age of the patients and the etiology of the fluid.

METHODS

This study was approved by Baskent University Medicine and Health Sciences Research Board and Clinical Research Ethics Committee, date: 12.10.2021, Decision no: 21/415. Since this study is a retrospective observational study, it was prepared by considering the STROBE criteria.

Patients in the neonatal and infant age group (0-2) who required PEPED catheterization for refractory or massive pleural effusion at our center between April 30, 2014, and August 06, 2021, consecutively were included in this study. All data, including the gestational age, birth weight, concomitant

genetic, neurological, and cardiac problems, the age of the patients at the time of catheter insertion (in months), the technique of PEPED, and results of analysis of the fluid obtained are acquired through the patients' hospital information system. Patients' clinical histories, laboratory data, AP chest radiograms, and interventional radiology reports about drainage procedures were reviewed and collected. The patient demographics, number of sessions, catheters, and fluid characteristics are summarized in Table-1.

Table 1: Table showing the relationships between patient, session, number of catheters, and type of effusion.

NUMBER OF SESSIONS	NUMBER OF PATIENTS	NUMBER OF CATHETERS	EFFUSIONS' CHARACTER
One	23	24	10 Chylothorax, 8 Hemothorax, 3 Transudate, 2 Exudate
Two	7	17	7 Chylothorax, 3 Exudate, 2 Empyema, 1 Transudate, 1 Hemothorax,
Three	1	4	2 Chylothorax, 1 Hemothorax
TOTAL	31	45	40 Pleural Effusion

Patients and drainage catheters

The criterion of the absence of active pneumonia was established for pleural effusion that developed in the postoperative period in the operated group of patients. The etiology of pleural effusion was accepted as infection if pneumonia and secondary parapneumonic effusion developed in the postoperative period (first week) or if the fluid character was empyema (leukocytes 10000/mm³, glucose < 60mg/dl or pH < 7.2). The distinction between transudate and exudate was made using the Light criteria (10). If the triglyceride level was 110 mg/dl or more, chylothorax was assumed (11). Effusions developed in the acute postoperative period (first week) and were clearly hemorrhagic were considered hemothorax.

Thirty-one patients were enrolled in the study, of whom 17 (54.8%) were male and 14 (45.2%) were female. A total of 24 catheters were inserted to 23 patients (13 right, 9 left, 2 bilateral) in 1 session, 17 catheters to 7 patients (9 right, 2 left, 6 bilateral) in 2 sessions, and 4 catheters to 1 patient (2 right, 2 bilateral) in 3 sessions. Thus, of the 45 catheters, 24 were inserted to the right side in 24 sessions (53.3%), 11 to the left side (24.4%) in 11 sessions, and 10 bilaterally (22.2%) in 5 sessions. Drainage procedure and sampling

The procedure was performed at the bedside under USG guidance using the Seldinger or trocar technique. The drainage catheter was standard in all patients and it was a 6.3F 25 cm Flexima APDL Locking Pigtail Drainage Catheter (Boston Scientific Corporation, Boston, Massachusetts, USA). For the Seldinger method, in addition to the same drainage catheter, an 18G Seldinger needle (Balton Ltd, Warszawa, Poland), a 75 cm Amplatz Super stiff guidewire (Boston Scientific Corporation, Boston, Massachusetts,

USA), and a 5F dilator (Balton Ltd, Warszawa, Poland) were used.

In the trocar technique, after local anesthesia (with a 10 ccs syringe and ppd needle tip, 3 cc -10 cc prilocaine solution diluted 50/50 with saline, depending on the patient's age and weight), a 6.3 F 25 cm drainage catheter was placed directly into the effusion under USG guidance. A 20 ccs sample was collected through the catheter and then left for free drainage.

In the Seldinger technique, after USG-guided local anesthesia, a pleural puncture was performed with an 18G Seldinger needle under USG guidance into the effusion. After collecting a 20 ccs sample through the needle, a 75 cm Amplatz Super stiff guidewire was advanced through the needle lumen into the effusion. The needle was then withdrawn, and after the tract was dilated with a 5F dilator over the guide wire, a 6.3F 25 cm drainage catheter was inserted into the effusion and allowed to drain freely.

Ten of the ten bilaterally inserted catheters were inserted simultaneously and withdrawn at the appropriate time by taking a unilateral sample (total of 5 sessions). Once the drainage catheter was inserted, approximately 20 ccs of fluid were sent to the biochemistry laboratory for diagnostic procedures and the microbiology laboratory in case of suspected infection. However, the procedure for sending samples to the microbiology laboratory was not routine and the data collected retrospectively were not very reliable. Of the 40 sessions, 23 were performed with the Seldinger method (57.5%) and 17 with the trocar method (42.5%). No patient required additional surgery or fibrinolytics after percutaneous drainage.

Data analysis and statistics

Following the descriptive statistics, patients' gestational age and dwell time of catheterization data were recorded. Parametric analyzes were performed with the two-sided T-test for independent samples, after using the Shapiro-Wilk test to demonstrate that the corresponding continuous data were normally distributed. First, we analyzed the relationship between the gestational age and the dwell time of catheters. Then, we examined whether there was a significant difference between the change in fluid character by time in the postoperative patient group. The confidence interval was set at 95% and the significance level at $p < 0.05$. All analyses were performed with the SPSS program. (Version 26.0; SPSS, Chicago, Ill.).

RESULTS

The gestational age of our 31 patients ranged from 25.1 to 41 weeks and the average was 35.55 ± 4.22 weeks. There was no post-term birth among our patients. Seventeen of them were term births (37-41.9 weeks), 7 of them were late preterm births (34-36.9 weeks), 1 of them was medium preterm birth (32-33.9 weeks), 3 of them were early preterm births (28-31.9 weeks), 3 of them were very early preterm births (< 28 weeks). Birth weights ranged from 620 to 3850 grams, with an average of

2854.52 ± 928.59 grams. The age of the patients on the day of catheter insertion ranged from 0.01 to 18.72 months, with an average of 5.27 ± 5.87 months.

The most common etiologies in our series were the postoperative period (15 patients, 48.4%), nonimmune hydrops fetalis (4 patients, 12.9%) and isolated pulmonary artery stenosis that has not yet been operated on (4 patients, 12.9%). Of the remaining 8 patients, 3 had pneumonia (9.7%), 2 had intrauterine growth retardation (6.5%), 2 had neonatal respiratory distress syndrome (6.5%) one of which was also PDA, and 1 had pulmonary artery atresia and associated hypoplastic right heart (3.2%).

The dwell time of the 45 drainage catheters ranged from 1 to 18 days, with a mean of 6.5 ± 4.02 days. Analyzing the data, we found that the dwell time of drainage catheters tended to increase from term to early preterm birth, regardless of the etiology of the effusion, 5.7 ± 3.7 days (Term), 6.89 ± 3.95 days (Late-preterm), 7 ± 0 days (Medium-preterm), 9.67 ± 7.37 days (Early-preterm), and 7.75 ± 3.76 days (Very early-preterm), respectively. Although catheter dwell time is shorter in the very early preterm group than in the early preterm group, this is misleading because all three of our patients in the very early preterm group died during the catheterized process. Gestational age and its relationship with the dwell time of catheters

Statistical analysis of drainage catheter dwell time was performed by forming two groups according to the gestational week. The first group was the term, late preterm and medium-preterm (32-41.9 weeks), the second group was early-preterm and very early-preterm (< 31.9 weeks). A two-sided independent samples T-test was performed for evaluation. According to the results of this analysis, although the dwell time of the catheter in the first group (6.06 ± 3.69) was shorter than in the second group (8.57 ± 5.13), no statistically significant difference was found, $t(38) = -1.53$, $p > 0.05$. All postoperative period and pneumonia patients were in the first group; in the second group, patients were mostly followed up with a diagnosis of non-immune hydrops fetalis and neonatal respiratory distress syndrome. While 5 deaths (20%) were observed in 25 patients of the first group, 4 deaths (66%) were observed in 6 patients of the second group.

Pleural fluids' characters change in the postoperative group over time

In the postoperative patient group, one of the patients had a multiple surgery history before the surgery in our hospital. Bowel perforation developed in another patient just after the surgery. Therefore we excluded them from our analysis. Of the remaining 13 patients who developed pleural effusion in the postoperative period, 6 were localized on the right and 7 were on the left. The duration between the day of surgery and the PEPED day was 1-12 days, with a mean of 4.38 ± 3.5 days. Of these, 8 were hemothorax, 4 were chylothorax, and 1 was exudate. In 4 patients who developed a chylothorax, the time between surgery and PEPED was 6-12 days. Of these 4 patients, 3 had undergone surgery for hypoplastic/interrupted aortic arch and 1 for congenital diaphragmatic hernia. In 8

patients who developed hemothorax, the interval between surgery and PEPED ranged from 1 to 5 days. Two of these patients underwent surgery for tetralogy of Fallot, one patient for a shunt between the subclavian and pulmonary arteries because of transposition of the great arteries (TGA) and AVSD, one patient for shunt surgery due to PDA, one patient had bilateral cavopulmonary anastomosis surgery, one patient had PDA ligation & VSD surgery, one patient had jaten surgery and the last one had surgery to correct diaphragmatic eventration.

In 12 patients who developed chylothorax and hemothorax in the postoperative period, the duration between the date of surgery and the date of PEPED was listed as days. The Shapiro-Wilk test for normal distribution was applied to this group of data, and after the curve was found to be normal ($p=0.65$ for the chylothorax group; $p=0.27$ for the hemothorax group), an independent-samples T-test was performed to determine whether there was a significant difference in the change in the character of the fluid by time. According to the results of this analysis, it was found that the development time of chylothorax (8.75 ± 2.75) was significantly longer than the development time of hemothorax ((2.5 ± 1.41)). $t(4)=4.27$, $p<0.05$

Results for the post-catheterization process and complications.

In 41 of the 45 catheters, no problems occurred from the day of insertion to the time of removal. In one patient born at 36.9 weeks and 2700 grams who was operated on for congenital diaphragmatic hernia, a left pneumothorax occurred on postoperative day-1, and the left lung was almost nonventilated. In the following days, a massive pleural effusion developed here. For this reason, a drainage catheter was inserted by the trocar technique on postoperative day-6, and chyloid fluid was observed. The AP chest radiograph taken 24 hours after the drainage catheter was inserted showed that the pleural effusion had largely disappeared, but the pneumothorax persisted. The drainage catheter was then connected to the underwater seal drainage system and the pneumothorax disappeared within 24 hours (Figure 1).

In one of our patients, born at 35.6 weeks and 2530 grams, bilateral catheters had to be inserted again in a second session because two bilateral catheters inserted with the trocar method were obstructed. These occluded catheters belonged to the only empyema patient in our series and were occluded seven days after the first catheter insertion (Figure 2).

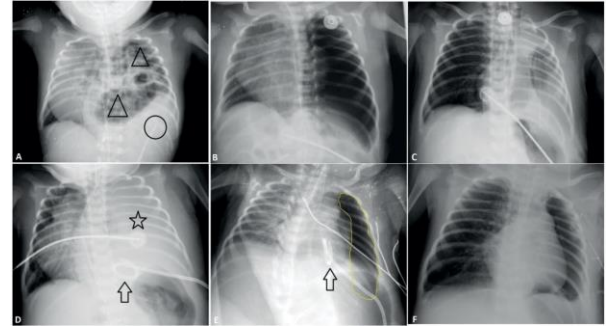


Figure-1: A. As a result of a congenital diaphragmatic hernia, bowel segments fill the left hemithorax and partially the inferior mediastinum, as seen on the chest X-ray, taken one day before surgery (black triangles). There is also a localized effusion in the inferior-lateral region of these bowel segments (black circle). B. The chest radiograph was taken on postoperative day 1, the left hemithorax is completely filled with air, and the left lung is not clearly ventilated. In addition, there is a significant shift of the mediastinal structures to the right along with the left lung tissue. C. On postoperative day 2, we see that the mediastinal structures and the left lung have largely returned to their anatomic position. However, the lung parenchyma is still not clearly ventilated. The pneumothorax has been replaced by pleural effusion. D. On postoperative day 6, the ventilation of the left lung has completely disappeared and the mediastinal structures have shifted back to the right. An effusion covers the entire left hemithorax (black star). Inferior to the left hemithorax, we see the drainage catheter inserted by the trocar method (black arrow). E. On the chest radiograph taken 1.5 days after insertion of the drainage catheter (black arrow), we see that the mediastinal structures have recovered and partial ventilation of the left lung has increased. Although no effusion has remained, there is a large area of pneumothorax (area surrounded by the yellow line). At this point, the drainage catheter is removed from the standard bag and connected to the underwater seal. F. Five days after the drainage catheter is connected to the underwater seal. It is withdrawn because there is no more air in the pleural cavity and no more fluid draining from the catheter. On the chest X-ray, the mediastinal structures are seen in their normal anatomical position and the ventilation of the left lung is completely normal.

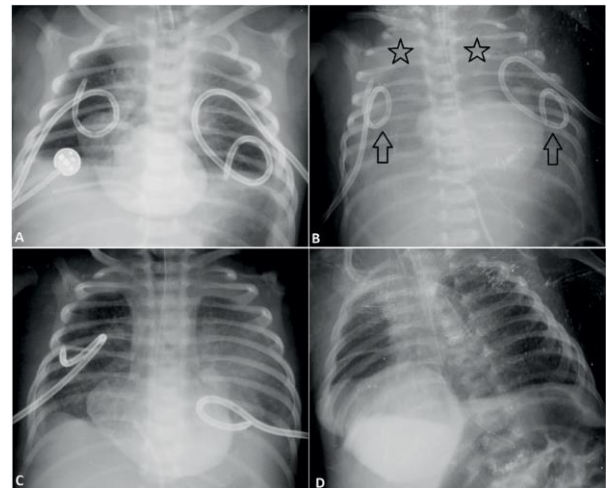


Figure-2: A. The position of bilateral drainage catheters inserted with suspicion of complicated parapneumonic effusion was checked 2 hours after insertion using chest radiography. Both catheters were well placed and well drained. B. Drainage was continued for the first 6 days but was turned off on the seventh day. The control chest radiograph showed that the ventilation of both lungs was impaired and a large effusion developed around them, especially in the apical region (black stars). It was then understood that both catheters (black

arrows) were obstructed, and then the catheters were removed. New bilateral drainage catheters were inserted the same day. C. On the chest radiograph taken one day after the insertion of the new catheters, minimal effusion is seen around both lungs, but ventilation of both lungs has substantially returned to normal D. Drainage from the bilateral catheters inserted in the second session decreased after six days. The chest radiograph shows that the ventilation of both lungs is completely normal.

The bilateral catheters inserted in the second session were removed six days later, when drainage was complete and pulmonary ventilation returned to normal. This patient, who had a total of 4 catheters inserted for 2 weeks because of severe empyema, was also followed up for numerous additional cardiovascular problems, including severe pulmonary artery stenosis and a double-outlet right ventricle.

The catheter of non-immune hydrops fetalis patient born at 27.4 weeks and 1770 grams, who had a PEPED catheter inserted into the left hemithorax by the Seldinger method, became twisted in the subcutaneous tissue on day-9. This situation was not due to the procedure but to manipulations during the care of the baby in the intensive care unit. A second PEPED catheter was placed on the left side using the Seldinger method. A second session was held 3 days after the twisting of the catheter was noticed. This catheter was removed seven days after completion of drainage, when pulmonary ventilation returned to normal (Figure 3).

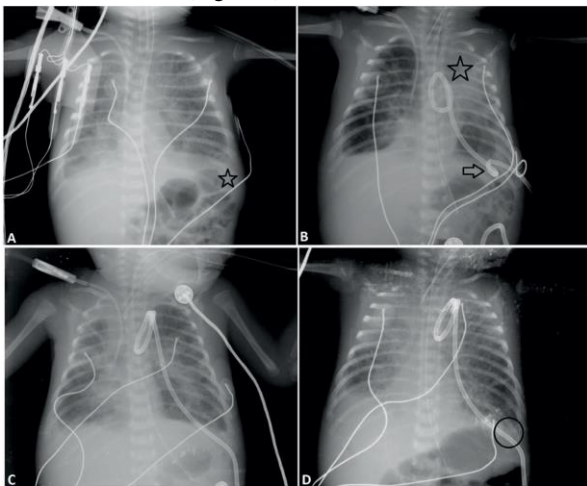


Figure-3: A. The left costophrenic sinus of a patient with very early preterm birth and intrauterine growth retardation who has developed non-immune hydrops is occluded (black star). A decision is made to insert a percutaneous drainage catheter in the patient, who was found to have a 4 cm effusion on the USG. B. While the transudate fluid continues to flow, the drainage is abruptly interrupted nine days after catheter insertion. On the chest X-ray, it is noticeable that the ventilation of the left lung is decreased and there is a significant effusion around the entire lung, which is more pronounced in the apical region (black star). This is due to the fact that the catheter has been twisted and occluded at the point of entry into the skin (black arrow) and therefore the more distal portion of the catheter is surrounded by a fibrin sheath. C. At a second session on the same day, a drainage catheter is again inserted from the left side. On the chest X-ray taken 2 hours later, it can be seen that the ventilation of the left lung has improved significantly and the amount of fluid has significantly decreased. D. Drainage gradually decreased and stopped seven days after insertion of the second catheter. The patient's chest X-ray shows that the ventilation of the left lung has wholly normalized, and there is no more effusion. Although the costophrenic sinus is closed on the right

side, it is open on the left side (black ring).

DISCUSSION

The effusion should be drained if it is excessive, localized, or the patient's condition progressively worsens (12,13). Although parapneumonic effusions are the most common in epidemiologic studies in the literature (14,15), such effusions usually regress with only antibiotherapy or simple aspiration, and there is no need for a permanent drainage catheter. Therefore, we most frequently observed chylothorax (19 effusions) and hemothorax (10 effusions) in our series due to mainly cardiac reasons and the postoperative period.

Isolated pulmonary artery stenosis that has not yet been operated on is one of the most common etiologies in our series. Although no publications clearly demonstrate the association between pulmonary artery stenosis/atresia and refractory pleural effusion, there are several case reports for adults in the literature. One of them is a refractory pleural effusion that developed on the left hemithorax as a result of pulmonary artery stenosis due to fibrosing mediastinitis in a 70-year-old man (16). However, there is no case involving this situation in the neonatal and infant age group.

An imbalance of blood gasses or a decrease in oxygen saturation must alert the clinician for pleural effusion (17), as observed in our 4 non-immune hydrops fetalis patients. In 2 of them, the effusion was on the right side, 1 was on the left, and 1 was bilateral.

Congenital chylothorax is frequently observed in Turner, Down, and Noonan syndromes (18), more common in boys than in girls (2:1), and involves the right hemithorax, probably because of the anatomic location of the thoracic duct (19). In our series, we had a total of 3 patients with Down syndrome. One of them developed hemothorax four days after surgery for tetralogy of Fallot. No more chylothorax was observed in the following days. The other was the only patient in our series who underwent surgery for AVSD, and we had three PEPED sessions for this patient. The last patient with Down syndrome had AVSD developed chylothorax and pneumonia simultaneously in the preoperative period (glucose: 132 mg/dl, triglycerides: 141 mg/dl). Therefore, it was not plausible to associate these chylothoraces as congenital.

Except for our empyema patient, we had no problems with drainage. If the child is grown enough and the intercostal space is wide, larger catheters such as 8F can be used, especially in patients with empyema. However, in neonates and infants, large-diameter catheters can cause severe pain and hemorrhagic complications (20).

Hemothorax is the presence of blood in the pleural space. If the patient was within the first week after surgery and the draining effusion was visually dark red as blood, the patient was considered to have hemothorax. If the fluid was only slightly red or pink or after postoperative day-7, the fluid was analyzed for further classification. As expected, we find hemothorax most commonly in the early postoperative period. However, other conditions such as malignancies, various bleeding disorders, and improper chest tube

placement can also cause hemothorax, but this did not occur in our series.

In 2006, Margau et al. Retro spectively investigated whether there was a difference between catheter and aspiration drainage for pleural effusion in neonates in terms of appropriateness of treatment and complications. They showed that although there was no difference in the complication rate, treatment with a drainage catheter was significantly superior to simple aspiration (21). If imaging guidance is used when placing the drainage catheter by an experienced interventional radiologist, the likelihood of complications is approximately 0%. We did not observe any complications during the procedure in our series.

CONCLUSION

The greatest strength of this study is the demonstration of efficacy and reliability of USG-guided PEPED catheterization in a narrowly defined age group with rare etiologic causes. One of the major limitations of our study is the lack of objective laboratory criteria for effusions in patients with suspected hemothorax. Although the retrospective nature of the study is another weakness, it will not be efficient to design this study as a prospective cohort study for a rare clinical condition in the patient group in question, and ethical issues will arise.

Funding: This research did not receive any specific financial support or funding.

Disclosure: The authors do not report any conflicts of interest.

Acknowledgments: No one other than the authors of this article contributed to this study.

Statement of Contribution of Researchers: The authors declare that they have contributed equally to the article. Main idea-planning: Ç.K; Analysisinterpretation: Ç.K; Data provision: Ö.Ö; Spelling: Ç.K; Review and correction: Ö.Ö; Confirmation: Ç.K, Ö.Ö.

Ethics Committee Approval: Baskent University Medicine and Health Sciences Research Board and Clinical Research Ethics Committee, date: 12.10.2021, Decision no: 21/415

REFERENCES

1. Rix-Trott K, Byrnes CA, Gilchrist CA, Matsas R, Walls T, Voss L, et al. Surveillance of pediatric parapneumonic effusion/empyema in New Zealand. *Pediatr Pulmonol.* 2021; 56(9):2949-57.
2. Doski JJ, Lou D, Hicks BA, Megison SM, Sanchez P, Contidor M, et al. Management of parapneumonic collections in infants and children. *J Pediatr Surg.* 2000; 35(2):265-8.
3. Furuya-Meguro ME, Mejia-Arangure JM, Martinez-Martinez BE, Villalpando-Canchola R, Fuentes-Arellano SA. [Pneumonia complicated with empyema in children, to operate or not? Risk factors for surgery and review of the literature]. *Gac Med Mex.* 2000; 136(5):449-54.
4. Hilliard TN, Henderson AJ, Langton Hewer SC. Management of parapneumonic effusion and empyema. *Arch Dis Child.* 2003; 88(10):915-7.
5. Hoffer FA, Bloom DA, Colin AA, Fishman SJ. Lung abscess versus necrotizing pneumonia: implications for interventional therapy. *Pediatr Radiol.* 1999;29(2):87-91.
6. Martinez L, Rivas S, Hernandez F, Avila LF, Lassaletta L, Murcia J, et al. Aggressive conservative treatment of esophageal perforations in children. *J Pediatr Surg.* 2003;38(5):685-9.
7. Roberts JS, Bratton SL, Brogan TV. Efficacy and complications of percutaneous pigtail catheters for thoracostomy in pediatric patients. *Chest.* 1998;114(4):1116-21.
8. Cochran JB, Tecklenburg FW, Turner RB. Intrapleural instillation of fibrinolytic agents for treatment of pleural empyema. *Pediatr Crit Care Med.* 2003;4(1):39-43.
9. Kilic N, Celebi S, Gurpinar A, Hacimustafaoglu M, Konca Y, Ildirim I, et al. Management of thoracic empyema in children. *Pediatr Surg Int.* 2002;18(1):21-3.
10. Light RW, Macgregor MI, Luchsinger PC, Ball WC, Jr. Pleural effusions: the diagnostic separation of transudates and exudates. *Ann Intern Med.* 1972;77(4):507-13.
11. Staats BA, Ellefson RD, Budahn LL, Dines DE, Prakash UB, Offord K. The lipoprotein profile of chylous and nonchylous pleural effusions. *Mayo Clin Proc.* 1980; 55(11):700-4.
12. Ferguson AD, Prescott RJ, Selkon JB, Watson D, Swinburn CR. The clinical course and management of thoracic empyema. *QJM.* 1996;89(4):285-9.
13. Jaffe A, Calder AD, Owens CM, Stanojevic S, Sonnappa S. Role of routine computed tomography in paediatric pleural empyema. *Thorax.* 2008;63(10):897-902.
14. Mocelin HT, Fischer GB. Epidemiology, presentation and treatment of pleural effusion. *Paediatr Respir Rev.* 2002;3(4):292-7.
15. Utine GE, Ozelik U, Kiper N, Dogru D, Yalcin E, Cobanoglu N, et al. Pediatric pleural effusions: etiological evaluation in 492 patients over 29 years. *Turk J Pediatr.* 2009; 51(3):214-9.
16. Yang S, Wang J, Li J, Huang K, Yang Y. Refractory pleural effusion as a rare complication of pulmonary vascular stenosis induced by fibrosing mediastinitis: a case report and literature review. *J Int Med Res* 2021; 49(5):3000605211010073.
17. Stevenson DA, Pysker TJ, Ward RM, Carey JC. Familial congenital non-immune hydrops, chylothorax, and pulmonary lymphangiectasia. *Am J Med Genet A.* 2006;140(4): 368-72.
18. Van Aerde J, Campbell AN, Smyth JA, loyd D, Bryan MH. Spontaneous chylothorax in newborns. *Am J Dis Child.* 1984;138(10):961-4.
19. Van Straaten HL, Gerards LJ, Krediet TG. Chylothorax in the neonatal period. *Eur J Pediatr.* 1993;152(1):2-5.

20. Islam S, Calkins CM, Goldin AB, Chen C, Downard CD, Huang EY, et al. The diagnosis and management of empyema in children: a comprehensive review from the APSA Outcomes and Clinical Trials Committee. *J Pediatr Surg.* 2012;47(11):2101-10.
21. Margau R, Amaral JG, Chait PG, Cohen J. Percutaneous thoracic drainage in neonates: catheter drainage versus treatment with aspiration alone. *Radiology.* 2006;241(1): 223-7.