



Retrospective Evaluation of Liver Transaminase Abnormalities in Asymptomatic and Symptomatic Patients According to Liver Biopsy Results

Asemptomatik ve Semptomatik Hastalarda Karaciğer Biyopsi Sonuçlarına Göre Karaciğer Transaminaz Anormalliklerinin Retrospektif Olarak Değerlendirilmesi

Bahri Abaylı¹, Cansu Abaylı², Genco Gençdal³

¹Seyhan Hospital, Department of Gastroenterology and Hepatology, Adana, Turkey

²Seyhan Hospital, Department of Pathology, Adana, Turkey

³Koc University Hospital, Center of Transplantation, Department of Gastroenterology and Hepatology, İstanbul, Turkey

Abstract

Aim: Histopathological examination of liver tissue is often performed with percutaneous liver biopsy. In this study, we aimed to evaluate the causes and results of liver biopsy performed for various reasons in our clinic between years 2016 and 2019.

Material and Method: 554 of 750 liver biopsies performed between July 2016 and January 2019 were included in the study. Pathology results of liver biopsies, the clinical information of the same patients were obtained from the patient files. Biopsy indications and results of the patients were evaluated retrospectively.

Results: 554 liver biopsy results (Male:323, 58.4%; mean age: 45±14.3) were included in the study. The most common liver biopsy indication in our hospital, was determined as the biopsies of patients with chronic hepatitis B. This indication was followed by liver biopsies performed to examine non-viral liver enzyme elevations. The pathology results were listed as; chronic hepatitis B (65%), Non-Alcoholic fatty liver disease/ Non-Alcoholic steatohepatitis (NAFLD/NASH) (16%), Autoimmune hepatitis (AIH) (3%), Hepatitis C (HCV)(3%) respectively.

Conclusion: The diversity in liver biopsy results shows the importance of histopathological evaluation. In order to reach healthy data, multi-centered prospective randomized controlled studies with larger populations are needed.

Keywords: Liver biopsy, fatty liver, hepatitis, cirrhosis

Öz

Amaç: Karaciğer dokusunun histopatolojik incelemesi, sıklıkla perkutan karaciğer biyopsisi ile yapılır. Bu çalışmada, kliniğimizde 2016-2019 yılları arasında çeşitli nedenlerle yapılmış karaciğer biyopsi nedenlerini, sonuçlarını değerlendirmeyi amaçladık.

Gereç ve Yöntem: Temmuz 2016-Ocak 2019 tarihleri arasında yapılan toplam 750 karaciğer biyopsininin 554'ü çalışmaya dahil edilmiştir. Karaciğer biyopsisinin patoloji sonuçlarına; aynı hastaların klinik bilgilerine hasta dosyalarından ve karaciğer biyopsi kayıt arşivimizden ulaşıldı. Hastaların biyopsi endikasyonları ve sonuçları retrospektif olarak değerlendirildi.

Bulgular: 554 adet karaciğer biyopsi sonucu (E:323, 58,4%;Yaş ortalaması: 45±14.3) çalışmaya dahil edilmiştir. Karaciğer nakil merkezi olan hastanemizde en sık saptanan karaciğer biyopsi endikasyonu Kronik hepatit B'li hastaların biyopsileri olarak tespit edilmiştir. Bu endikasyonu non-viral karaciğer enzim yüksekliklerini tetkik etmek amaçlı yapılan karaciğer biyopsilerininin izlediği saptanmıştır. Patoloji sonuçları değerlendirildiğinde sıklık sırasına göre hastalarda; kronik hepatit B (65%), Alkol ilişkili olmayan yağlı karaciğer hastalığı/ Steatohepatit (16%), Otoimmün hepatit (3%),Hepatit C (3%) olarak tespit edilmiştir.

Sonuç: Karaciğer biyopsi sonuçlarındaki çeşitlilik, histopatolojik değerlendirmenin önemini göstermektedir. Sağlıklı verilere ulaşmak için çeşitli merkezlerin verilerinin karşılaştırılması ve daha büyük ölçekli prospektif randomize kontrollü çalışmalar ihtiyaç vardır.

Anahtar Kelimeler: Karaciğer biyopsi, karaciğer yağlanması, hepatit, siroz



INTRODUCTION

Histopathological examination of liver tissue is a frequently used technique in the follow-up and treatment of liver diseases. Histopathological examination of liver tissue is often performed with percutaneous liver biopsy. Today, liver biopsy marked with ultrasonography, is still the gold standard method in the diagnosis and treatment of liver diseases. Through biopsy results we can provide qualitative information about the type and degree of injury and/or fibrosis. Relevant clinical information should be presented to the pathologist so that the histopathological findings can be interpreted in a clinical context. A guideline from the American Association for the Study of Liver Disease (AASLD) has defined the following indications for liver biopsy: Diagnostic evaluation, evaluation of focal or diffuse abnormalities in imaging studies, diagnosis of parenchymal liver disease, research on fever of unknown origin, staging of known parenchymal liver disease, development of treatment plans based on histological analysis.^[1-6]

In this study, we aimed to present the liver biopsies and histopathological examination results performed in a cross-sectional time interval in our clinic.

MATERIALS AND METHOD

554 of 750 liver biopsies performed between July 2016 and January 2019 were included in the study. Since it is a retrospective study, the pathology results of liver biopsies were taken from the pathology archive of our hospital; The clinical information of the same patients was obtained from the patient files. The local Ethics Committee approval was obtained (70/18.11.2020/1127).

Liver biopsies were performed by using the ultrasonography-guided percutaneous method. After marking with ultrasonography, hepatic samples were taken by using Hepafix® liver biopsy needle set (B.Braun Melsungen AG Corporate, Communications, Carl-Braun-Str., 1,34212, Melsungen, Germany-C17-gauge biopsy needle). The samples were fixed in 10% formalin and embedded in paraffin. Sections were stained with hematoxylin-eosin, Masson's trichrome and reticulin stains.

Hbsag, anti-Hbs, Hbeag, anti-Hbe were detected by Elecsys instrumental platform (Roche diagnostic, Italy). Hepatitis B DNA (HBV DNA) were quantified by the Real time PCR AmpliPrep/COBAS TaqMan HBV test 2.0 (Roche Molecular Systems, NJ, USA).

Demographic characteristics of the patients, pathology results and descriptive analyzes were performed using the IBM SPSS statistical program (v 22).

RESULTS

554 liver biopsy results (Male:323, 58.4%; mean age: 45±14.3) were included in the study. Liver biopsies were performed in all of these patients by using the percutaneous technique.

The most common indications for liver biopsy are presented in **Figure 1**. The most common histopathological diagnoses in patients who underwent percutaneous liver biopsy were listed as; chronic hepatitis B (65%), Non-Alcoholic fatty liver disease/ Non-Alcoholic steatohepatitis (NAFLD/NASH)(16%), Autoimmune Hepatitis (AIH) (3%), Hepatitis C (HCV) (3%) respectively (**Figure 2**). Demographic characteristics and detailed results of the patients are presented in **Table 1**.

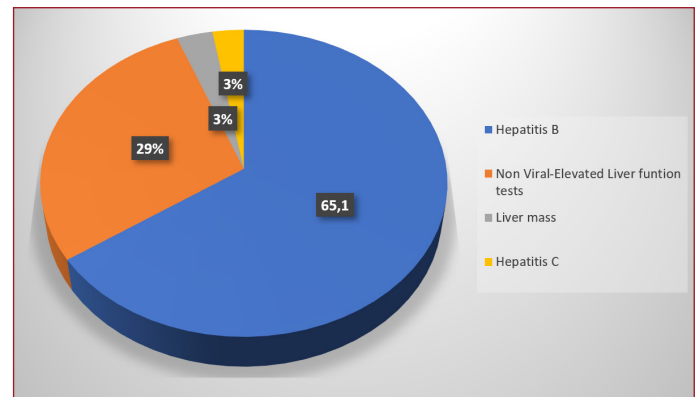


Figure 1. Liver biopsy indications

Table 1. Demographic characteristics of the patients and blood tests before liver biopsy

	Mean ± SD
Age	45±14.3
Gender (Male)	323
Hepatitis B DNA	2×10 ⁸ ±1×10 ⁸
ALT	70.6±119
AST	55.8±101
ALP	116.7±113
GGT	123.3±257
Albumin	4.1±0.8
Total Bilirubin	0.8±1.2
Direct Bilirubin	0.5±1
Na	137.4±2
K	4.2±0.6
Ca	8.8±0.7
Triglyceride	146.5±73
LDL	131.2±29
CK	125.8±111
LDH	192.1±146
Fasting Glucose	98.3±32
Creatine	0.7±0.3
Vitamine B12	390.2±233
Folic acid	6.2±2.2
Prothrombine Time	11.8±1.2
INR	1±0.1
TSH	2±3.3
FreeT4	1.2±0.4
Ferritin	278.7±277
Hemoglobin	13.9±1.5
Hematocrites	41.1±4.5
Platelet	241×10 ³ ±75×10 ³

SD,Standart deviation;AST, aspartate aminotransferase; ALT, alanine aminotransferase; ALP, alkaline phosphatase; GGT, gamma glutamyltransferase;LDL, low-density lipoprotein;CK,creatine kinase; LDH, lactate dehydrogenase;INR, Internationel Normalized Ratio;TSH, thyroid stimulating hormone

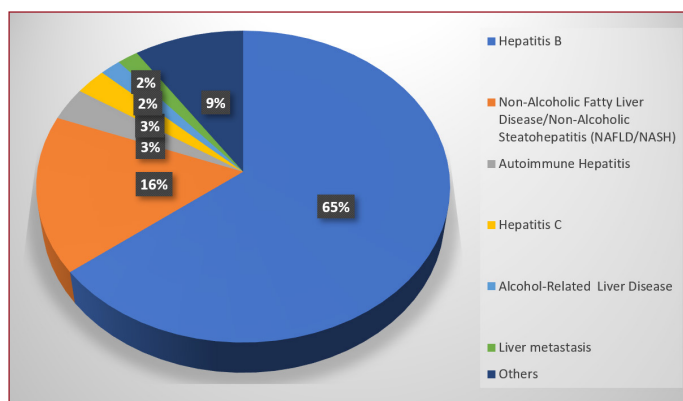


Figure 2. The results of histopathological examination results

DISCUSSION

Liver biopsies were performed using the conventional percutaneous method in our study. As in the whole world, the most common conditions in which we apply for liver biopsy are; staging of chronic liver diseases, determination of treatment indications in liver diseases, histopathological evaluation of treatment responses, diagnosis of liver diseases of unknown origin, diagnosis of lesions occupying space in the liver and evaluation of hepatic involvement of systemic diseases.^[7,8] In this study, the most common liver biopsy indications were found as; the diagnosis and the follow-up biopsies of patients with HBV, investigation of non-viral liver enzyme elevations, investigation of liver masses and the diagnosis and the follow-up biopsies of patients with HCV.

The risks of percutaneous liver biopsy include bleeding, organ perforation, sepsis, and death. Bleeding occurs in up to 10% and major bleeding in less than 2%. Risk factors for bleeding from percutaneous biopsy include advanced age, comorbidities, biopsy indication, and coagulation abnormalities. There is little conclusive evidence that the experience of the biopsy performer and the number of passes significantly affect the risk of bleeding.^[9,10] The biopsy-related death rate is less than 1 in 1000. In our study, no major bleeding and death after biopsy were detected.

There are few studies on liver biopsy indications and results in our country, and we do not have enough data on this subject. In a previous study in which 155 liver biopsies were evaluated by us at a liver transplant center, living donor evaluation for liver transplantation was found to be the most common cause of liver biopsy, this indication was followed by non-viral elevations in liver function tests. In the same study, the most common histopathological examination results were reported as; non-alcoholic fatty liver disease, chronic HBV, chronic HCV, toxic hepatitis, AIH, and liver cirrhosis respectively.^[11] According to another study from Turkey in which 409 liver biopsies were evaluated retrospectively; Although viral etiologies are at the forefront in pathology results, it has been reported that different pathology results such as nonspecific liver injury, steatohepatitis, autoimmune liver diseases and toxic hepatitis are also common, and

the HCV diagnosis is at the forefront when the elevation in liver function tests of unknown cause is investigated.^[12] In this study, according to the results of the histopathological examination, the most common diagnoses were; HBV, Nafld/Nash, autoimmune hepatitis, alcohol-related liver disease and liver malignant lesions respectively.

There are some limitations of our study, major limitations is the retrospective nature of the study. Limited access was provided for getting information about the demographic and the clinical characteristics of the patients. Since it is a single-centered study, the data reflect our region and may differ from country data.

There is a need for studies presenting epidemiological data in our country. In this study, we evaluated the results of cross-sectional liver biopsies performed in our center over 3 years. These data need to be supported by multicenter prospective randomized studies with larger populations.

ETHICAL DECLARATIONS

Ethics Committee Approval: The study was carried out with the permission of Istanbul University Medical Faculty Clinical Research Ethics Committee (Decision No: 70/18.11.2020/1127).

Informed Consent: Because the study was designed retrospectively, no written informed consent form was obtained from patients.

Referee Evaluation Process: Externally peer-reviewed.

Conflict of Interest Statement: The author has no conflicts of interest to declare.

Financial Disclosure: The authors declared that this study has received no financial support.

Author Contributions: All of the authors declare that they have all participated in the design, execution, and analysis of the paper, and that they have approved the final version.

REFERENCES

1. Bravo AA, Sheth SG, Chopra S. Liver Biopsy. *N Engl J Med.* 2001;344(7):495.
2. Tapper EB, Lok AS. Use of Liver Imaging and Biopsy in Clinical Practice. *N Engl J Med.* 2017;377(8):756.
3. Czaja AJ, Carpenter. Optimizing diagnosis from the medical liver biopsy. *Clin Gastroenterol Hepatol.* 2007;5(8):898.
4. Rockey DC, Caldwell SH, Goodman ZD, Nelson RC, Smith AD, American Association for the Study of Liver Diseases. Liver biopsy. *Hepatology.* 2009;49(3):1017.
5. Thomaidis-Brears HB, Alkhoury N, Allende D, Harisinghani M, Nouredin M, Reau NS et al. Incidence of Complications from Percutaneous Biopsy in Chronic Liver Disease: A Systematic Review and Meta-Analysis. *Dig Dis Sci.* 2021 Jun 15. doi: 10.1007/s10620-021-07089-w. Online ahead of print.
6. Neuberger J, Patel J, Caldwell H, et al. Guidelines on the use of liver Biopsy in clinical practice from the British Society of Gastroenterology, the Royal College of Radiologists and the Royal College of Pathology. *Gut* 2020;69:1382 LP – 1403.
7. Mıstık R, Balık İ. Türkiye'de viral hepatitlerin epidemiyolojik analizi. Tekeli E, Balık İ (eds). *Viral Hepatit 2003.* Ankara: Viral Hepatit Savaşım Derneği;2003:10-45.

8. John A, Al Kaabi S, Soofi ME, Mohannadi M, Kandath SM, Derbala M, et al. Liver biopsy for parenchymal liver disease - is routine real time image guidance unnecessary?. *Indian J Gastroenterol*. 2014 Jan. 33 (1):50-4.
9. Neuberger J, et al. *Gut* 2020;0:1–22. doi:10.1136/gutjnl-2020-321299.
10. Midia M, Odedra D, Shuster A, Midia R, Muir J. Predictors of bleeding complications following percutaneous image-guided liver biopsy: a scoping review. *Diagn Interv Radiol* 2019;25:71–80.
11. Gençdal G. Tek Merkez Deneyimi: Karaciğer Biyopsi Endikasyonları Ve Sonuçları. *Anatolian Clinic The Journal Of Medical Sciences*, 2019,24(1), 42-46.,
12. Cankurtaran M, Kav T, Özarslan E, Arslan S, Sökmensüer C, Batman F, Et al. Karaciğer Biyopsisi; Bir Gastroenteroloji Kliniğinin Retrospektif Çalışması Ve İç Hastalıklarına Yönelik Öneriler. *Türkiye Tıp Dergisi* 2003; 10(2): 55-59.