

AN UNUSUAL TUMOR OF THE PANCREAS: INSULINOMA

(Received 7 October, 1992)

Ö. Günal, M.D. **** / M. Ghaemi, M.D. **** / C. Yeğen, M.D. ***
Ö. Aktan, M.D.** / R. Yalın, M.D.*

- * Professor, Department of General Surgery, Faculty of Medicine, Marmara University, İstanbul, Türkiye.
** Associate Professor, Department of General Surgery, Faculty of Medicine, Marmara University, İstanbul, Türkiye.
*** Assistant Professor, Department of General Surgery, Faculty of Medicine, Marmara University, İstanbul, Türkiye.
**** Specialist, Department of General Surgery, Faculty of Medicine, Marmara University, İstanbul, Türkiye.

SUMMARY

We report a case of functioning islet cell tumor of pancreas presenting clinically with the Whipple's Triad. CT Scan was considered to be characteristic of insulinoma when evaluated together with the clinical signs and symptoms. The tumor was enucleated and pancreatic fistula developed on the second day of the operation. Fistula was successfully treated with a somatostatin analog SMS 201 - 995.

Key words: Insulinoma, Pancreatic Fistula, Whipple's Triad.

INTRODUCTION

Islet cell tumor prevalence of the pancreas has been reported to be 0.5 to 1.5 percent in unselected autopsy series (1,2). Identification of this tumor is usually related to the recognition of the endocrine syndrome. Clinical characteristics of this syndrome range from hypoglycemia to psychoneurologic manifestations. The Whipple's Triad is the major symptom complex and is characterized by collapse attacks precipitated by fasting or exertion, blood glucose levels under 50 mg/dl by fasting, and relief of symptoms by administration of oral or parenteral glucose. Our case was diagnosed with these symptoms. Insulinomas are occasionally a feature of multiple endocrine adenomatosis syndrome (MEA-I) (3). It has been shown that 4 % of insulinomas associated with MEN-I (4). Over 90 % of these tumors are solitary (4) and benign (3). In this paper a patient with a functioning islet cell tumor of pancreas is presented.

CASE REPORT

A-57-year old man was admitted to the hospital with a history of fainting provoked with fasting. The symptoms were improved by oral sugar intake. He has got occasional hypoglycemic blood glucose le-

vels under 50mg/dl on sequential analysis. His blood C-Peptid level was in normal range (3.2ng/ml, Normal <5ng/ml). Insulin level was 50 IU/ml (Normal=6-26 IU/ml). Computerized tomography revealed a suspicious mass within the anterosuperior aspect of the corpus of the pancreas. At the operation, a mass of 3x2.5x2 cm. in size was seen in the described portion of the pancreas (Figure-1). The tumor was enucleated. On the second postoperative day, abdominal ultrasonography revealed multiple intraabdominal collections. These collections were drained percutaneously and the amylase content of this fluid was 26000 IU/L. The initial volume of this fluid was 700 ml daily. Sandostatin SMS 201-995 100 microgam t.i.d. S.C. was begun on the second day and dose was increased to 200 microgram q.i.d. on the twentyninth day. The fistula output decreased and eventually stopped on the fortyfifth day. The blood glucose levels were normal after and initial increase after enucleation of the tumor.

DISCUSSION

Insulinoma is very rare tumor. It is recognized by the clinical feature described by Whipple as a triad. If blood sugar falls rapidly symptoms referable to epinephrine release caused by hypoglycemia is seen. A slower decrease in blood sugar produces cerebral and psychiatric symptoms, which can make the diagnosis harder (5). In our patient, all signs and symptoms of the Whipple Triad were seen.

Apart from the clinical signs, percutaneous transhepatic venography with sampling, ultrasound, computerized axial tomography, magnetic resonance imaging, Ga67-citrate scanning, secretin test, C-peptid suppression test and operative findings are also among the major diagnostic tools (5-7).

Also there are reports that advocate endoscopic ultrasound in the diagnosis (8). In our case ultrasonography was unyielding but CT was helpful in diagno-

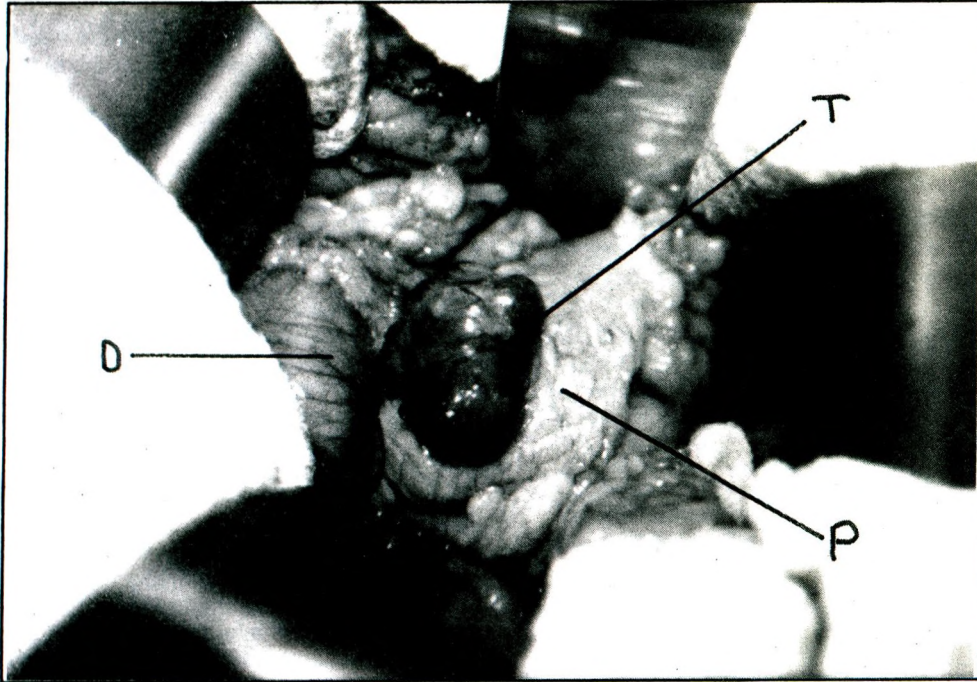


Fig.1: D: Duodenum T: Tumor P: Pancreas

sis. C-Peptid level was also normal. Apart from a few glucose levels fasting glucose measurements were normal. Although some of the glucose levels tests were normal the diagnosis was made with clinical findings and CT scan.

Even though there are few reports of successfully treated patients with diazoxide (6), in the treatment, surgery is the gold standard. We treated our patient with surgical therapy by simple enucleation. Medical therapy today is reserved for patients who do not benefit from surgical therapy (9). For an adenoma simple enucleation is the most convenient choice. When adenomas are multiple, distal subtotal pancreatectomy is preferable (1). A pancreaticoduodenal resection is recommended with preservation of the tail, when the tumor cannot be found after thorough exploration (3). It has been reported that 42.6 % of 129 patients were cured and 10.9 % were improved after blind distal pancreatectomy when no tumor was found at operation by Silen et al (3). However either preoperatively or intraoperatively to predict the tumor localisation is mandatory. This is very important for the outcome of the disease. Gorden(9) for this reason strongly suggests intraoperative ultrasonography for identifying the occult lesions with a specificity of 83-100 %. Operative localisation is very important to reduce the postoperative complications. We treated our complication due to cut off a pancreatic duct, with a somatostatin analogue SMS 201-995 successfully.

REFERENCES

1. Bradley EL, Zeppa R, The Pancreas. In: Sabiston DC, ed. *Textbook of Surgery; The biological basis of modern surgical Practlce*. Tokyo: WB Saunders Company / Igaku-Shoin, 1986: 1196.
2. Van Heerden JA. Pankreasın Adacık Hücre Tümörleri In: Sayek İ, ed. *Temel Cerrahi*. Ankara: Güneş Kitabevi, 1991:1010-1017.
3. Silen W, Steer ML. Panceras. In: Schwartz SI, Shires QT, Spencer FC, eds. *Principles of Surgery*. Singapore: Mc Graw Hill, 1988: 1434-1438.
4. Demeure MJ, Klonoff DC, Karam JH, Duh QY, Clark OH. Insulinomas associated with MEA-I: the need for a different surgical approach. *Surgery* 1991; 110 (6): 998-1004.
5. Berkow R. Gastrointestinal disorders. In: *The Merck Manual. Fourteenth Edition. U.S.A: Merck Sharp&Dohme Research Laboratories. 1982:752-753.*
6. Takeda H, Watanabe K, Suzuki D, et al. A Case of insulin-secreting tumor successfully treated with diazoxide. *Tokai J Exp Clin Med* 1991; 16 (1) : 73-76.
7. Imamura M, Hattori Y, Nishida O, et al. Unresponsiveness of insulinoma cells to secretin: significans of secretin test in patients with insulinoma. *Pancreas* 1990; 5(4): 467-473.
8. Bolondi L, Li Bassi S, Gainai S, Camplone O, Marrano D, Barbara L. Diagnosis of Islet Cell Tumor By Means of Endoscopic Ultrasonography. *J Clin Gastroenterol* 1990; 12 (2): 218-221.
9. Dt. Gorden P. Jensen RT. Localisation and surgical treatment of occult insulinomas. *Ann Surg* 1990; 212 (5):615-620.