

THE DISTRIBUTION OF THE NUCLEOLAR ORGANISER REGIONS IN THE DYSPLASTIC EPITHELIAL LESIONS AND IN THE EPIDERMOID CARCINOMAS OF THE VOCAL CORDS*

(Received 7 December, 1993)

Ç. Batman, M.D.** / A. Tutkun, M.D.**** / A. Sav, M.D.***
B. Mamikoğlu, M.D.***** / H. Dizdar, M.D.*****
C. Üneri, M.D.**** / M.A. Şehitoğlu, M.D.****

** Professor, Department of Otorhinolaryngology, Faculty of Medicine, Marmara University, İstanbul, Türkiye.

*** Associate Professor, Department of Pathology, Faculty of Medicine, Marmara University, İstanbul, Türkiye.

**** Associate Professor, Department of Otorhinolaryngology, Faculty of Medicine, Marmara University, İstanbul, Türkiye.

***** Assistant Professor, Department of Otorhinolaryngology, Faculty of Medicine, Marmara University, İstanbul, Türkiye.

***** Research Assistant, Department of Otorhinolaryngology, Faculty of Medicine, Marmara University, İstanbul, Türkiye.

***** Research Assistant, Department of Pathology, Faculty of Medicine, Marmara University, İstanbul, Türkiye.

SUMMARY

Silver-binding nuclear organizer regions (AgNORs) were counted in samples of normal, dysplastic and squamous cell carcinoma of the vocal cord. A significant difference in the mean number of AgNORs was found when squamous cell carcinoma samples were compared with dysplastic lesions (p less than 0.0001). Also the difference in the mean AgNOR count was significant when the lesion was compared with normal epithelium.

Key Words: AgNORs, dysplastic epithelial lesions, squamous cell carcinoma.

INTRODUCTION

Nucleolar Organizer Regions (NOR) are loops of DNA occurring within nucleoli that encode for ribosomal RNA (rRNA). Over the last few years an expanding body of literature has been devoted to the study of NOR and their associated proteins (AgNOR) as markers for cellular proliferation. Although some controversy still exists on the precise significance of AgNOR counts, many studies support the view that the number of AgNOR is higher in malignant tumors than in their benign counterparts (1-4).

This study is undertaken to determine whether the AgNOR counts per cell obtained from routine histological sections of squamous cell carcinoma (SCC) had a different range of AgNOR values than dysplastic laryngeal mucosa. Normal appearing mucosa obtained from the specimens of both SCC and dysplasia patients' samples were used as controls.

MATERIAL AND METHODS

Nine patients with squamous cell carcinoma and dysplastic laryngeal mucosa were selected in this study. In each case, adequate tissue in the form of

paraffin blocks was available in the pathology archives of Marmara University Hospital Pathology Department. The histopathologic diagnosis had been made on examination of hematoxylin-eosin stained sections. On histologic examinations, the dysplastic lesions demonstrated thickened or hyperplastic epithelium, surface maturation or keratinization, often a proliferation of small, immature cells in depths of the epithelium, and abnormal maturation as evidenced by focal areas of cytoplasmic keratinization in the lower portions of the mucosa. None of the patients had full-thickness mucosal replacement by undifferentiated small cells which is traditional histologic appearance of carcinoma in-situ. The normal epithelial tissue found within these samples were used as controls. All the SCC cases were stage I vocal cord tumors. Non-tumorous regions in SCC samples were also examined separately as another control group.

Nucleolar Organizer Region Staining:

Deparaffinized sections of 3-4 micron in thickness, were dehydrated through an ethanol series to distilled water. The sections were then postfixed in a 3:1 ethanol-acetic acid mixture for 10 minutes and then rehydrated. The tissue sections were reacted with a solution of two parts of 50% aqueous silver nitrate solution and one part of gelatine dissolved in 1% aqueous formic acid at a concentration of 2%. The reaction was continued for 30 minutes at humidified room temperature in the dark. The sections were then washed out with distilled water, dehydrated and mounted. No counterstain was used.

Cell counting:

AgNORs were counted using a X1000 oil-immersion lens in the preselected region of the tumor. In each case 100 nuclei that contained argyrophilic staining were counted. Counting procedure was done by focusing up and down in the planes of sections. The total AgNOR count was obtained by enumeration of both intra- and extra-nucleolar AgNOR dots (5). AgNORs were counted without knowledge of the

* Presented at 15th World Congress of Otorhinolaryngology Head and Neck Surgery, İstanbul - Türkiye, 20 - 25 June 1993.

histological diagnosis by a specialized pathologist. Difference between two group means is used for the statistical analysis (6).

RESULTS

AgNOR were seen as black dots of varying size within the nucleus (Figs 1,2). There was not much difference in the appearance of AgNOR in both squamous cell carcinoma (SCC) and in dysplastic laryngeal mucosa samples, but those in malignant tissue appeared less uniform in size and shape. The mean AgNOR count per cell was found to be higher in SCC (1.86 + 1.18) than in dysplastic laryngeal mucosa (1.66 + 0.90) (Table I). This difference was statistically significant (t value, 6.12; $p < 0.0001$). The

mean AgNOR count per cell was found 1.51 + 0.72 in nontumorous regions of the SCC samples and 1.32 + 0.61 in normal epithelial regions in the dysplastic laryngeal mucosa samples (Table II). The mean AgNOR count per cell of the normal epithelium obtained from dysplastic laryngeal mucosa samples differed significantly from the representative areas of dysplastic laryngeal mucosa (t value, 6.72; $p < 0.0001$) and SCC (t value, 11.96; $p < 0.0001$).

The difference between the mean AgNOR count per cell of the normal epithelium obtained from dysplastic laryngeal mucosa samples was also statistically significant from the mean AgNOR count per cell of the nontumorous regions of SCC samples (t value, 5.8; $p < 0.0001$).

Table I- Nucleolar organizer Region counts in laryngeal squamous cell carcinoma and laryngeal dysplastic mucosa.

	No	Mean	S.D.
SCC	9	1.86	1.18
DLM	9	1.66	0.90

SCC : squamous cell carcinoma

DLM : dysplastic laryngeal mucosa

Table I- Nucleolar organizer Region counts in normal epithelial regions of dysplastic laryngeal mucosa samples and in nontumours normal epithelial regions of laryngeal squamous cell carcinoma samples.

	No	Mean	S.D.
SCCN	9	1.51	0.72
DLMN	9	1.32	0.61

SCCN : nontumours normal epithelial regions of laryngeal squamous cell carcinoma

DLMN : normal epithelial regions of dyplastic laryngeal mucosa

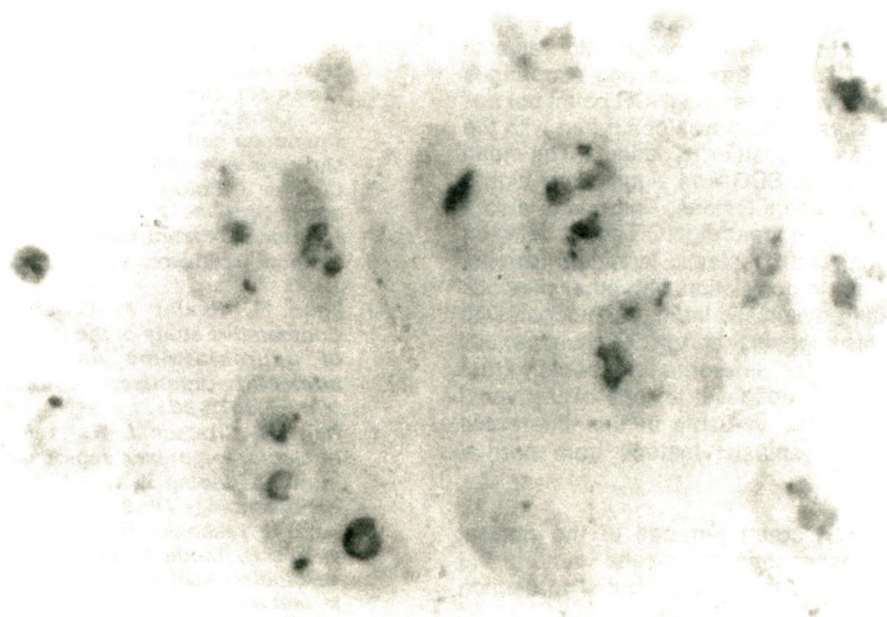


Fig. 1: AgNORs staining of squamous cell carcinoma of the vocal cords.

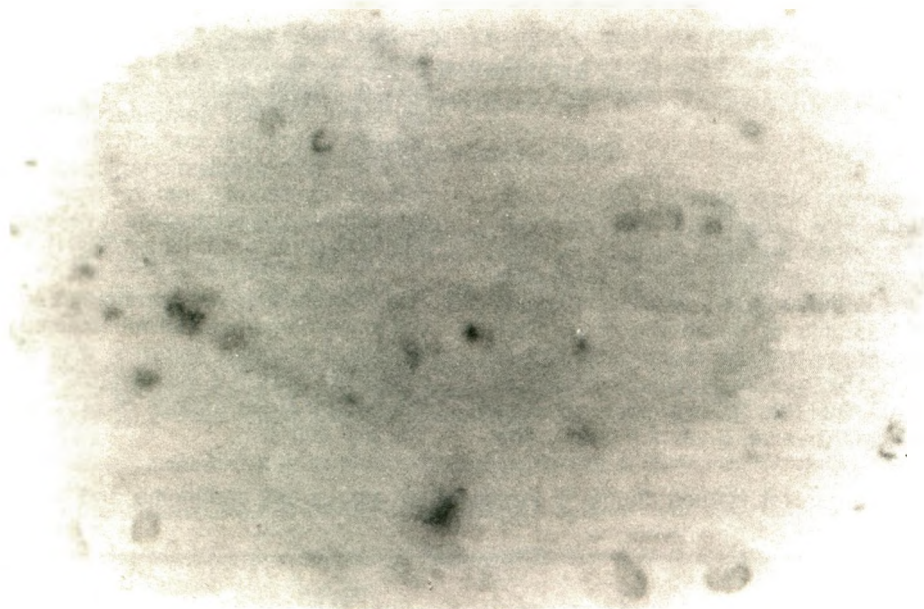


Fig. 2: AgNORs staining of dysplasia of the vocal cords

DISCUSSION

Many studies have demonstrated a positive correlation between AgNOR count per cell and rate of cell proliferation. AgNOR count per cell found higher in malignant melanomas versus benign (1), SCC of skin versus keratoacanthomas (2), adenocarcinoma versus villous adenoma of the colon (3). In addition, AgNOR count per cell was related to the tumour stage in SCC of the head and neck (4) and differentiation in neuroblastomas (7), and Hodgkin's lymphomas (8).

According to studies, high AgNOR count per cell is suggestive of poor prognosis in SCC of head and neck (4,9). In contrast, other studies failed to find the AgNOR technique to have any prognostic value in patients with SCC of the bronchus and esophagus (10,11). In this study, the mean AgNOR count per cell of stage I SCC of vocal cord was compared with the dysplastic laryngeal mucosa in 18 patients. The mean number of AgNORs in SCC was significantly higher than dysplastic laryngeal lesions. There was also a significant difference in mean AgNOR count between normal epithelium and dysplastic laryngeal lesions. These findings are in correlation with other previous studies comparing dysplastic laryngeal mucosa with SCC (12,13). This suggests that AgNOR count per cell might be of value for differentiating benign from malignant squamous epithelial lesions of the vocal cord. It might be also valuable in the differential diagnosis of the dysplastic lesions from normal epithelium.

The mean AgNOR count per cell of the normal epithelium was lesser than the results found in the previous studies. This may be attributed to section thickness and staining reaction time.

In conclusion, the use of AgNOR technique in differential diagnosis of SCC and dysplastic lesions of larynx should be evaluated and further studies are needed to demonstrate its prognostic value.

REFERENCES

1. Howat A, Qiri P, Cotton D, Slater D. Nucleolar organizer regions in Spitz nevi and malignant melanoma. *Cancer* 1989; 63: 474-478.
2. Kanitakis J, Hoyo E, Hermier C, Chourvet B, Thivolet J. Nucleolar organizer region enumeration in keratoacanthomas and squamous cell carcinomas of the skin. *Cancer* 1992;69:2937-2941.
3. Yang P, Huang QS, Zhu XS. Role of nucleolar organizer regions in differentiating malignant from benign tumours of the colon. *J Clin Pathol* 1990; 43:235-238.
4. Hirsch SM, Dulanto J, Caldarelli DD, Hutckinson JC, Coon JS. Nucleolar organiser regions in squamous cell carcinoma of the head and neck. *Laryngoscope* 1992;102:39-44.
5. Crocker J, Boldly DAR, Egan MJ. How should we count AgNORs ? Proposals for a standardized approach. *J Pathol* 1989;158:185-188.
6. Statgraf, software, V.2.1; Exec "U" graf, Laurer, 1986.
7. Egan M, Raafat F, Crocker J, Williams D. Comparative study of the degree of differentiation of neuroblastoma and mean numbers of nucleolar organiser regions. *J Clin Pathol* 1988;12:373-381.
8. Hall PA, Crocker J, Watts A. A comparison of nucleolar organizer regions staining and Ki67 immunostaining in non-Hodgkins's lymphomas. *Histopathology* 1988;12:373-381.
9. Sano K, Takahashi H, Fujita S, Inokuchi T, Pe MB, Okabe H, Tsuda N. Prognostic implication of silver-binding nucleolar organizer regions (AgNORs) in oral squamous cell carcinoma. *Oral Pathol Med* 1991;20:53-56.

10. Boldy DAR, Ayres JG, Crocker J, Waterhouse JAH, Gilthorpe M. Interphase nucleolar organiser regions and survival in squamous cell carcinoma of the bronchus: a 10 year follow up study of 138 cases. *Thorax* 1991;46:2937-2941.
11. Morita M, Kuwano H, Matsuda H, Moriguchi S, Sugimachi K. Prognostic significance of argyrophillic nucleolar organizer regions in esophageal carcinoma. *Cancer Res* 1991;51:5339-5341.
12. Muscara M, Giuffre G, Trombetta CJ, Bisantis F, Tuccari G. Nucleolar organizer regions (NORs) in dysplastic and neoplastic epithelial lesions of the conjunctiva. *Pathologica* 1991;83:281-288.
13. Mauri FA, Ferrero S, Barbareschi M, Scampini S, Muscara M, Motta M, Pignataro L. AgNOR distribution in normal and dysplastic laryngeal mucosa and in laryngeal epidermoid carcinomas. *Pathologica* 1990;82:493-497.