

## An Extraordinary Case Presentation: Right Iliac and Femoral Vein Thrombus

### Sıradışı Bir Olgu Sunumu: Sağ İliak Ve Femoral Ven Trombüsü

Sacit Akdeniz<sup>1</sup>, Bilge Ercan<sup>2</sup>, Yusuf Yürümez<sup>2</sup>, Ensar Durmuş<sup>2</sup>, Necip Gökhan Güner<sup>2</sup>, Veysel Yılmaz<sup>2</sup>

#### ABSTRACT

**Aim:** Abdominal pain is among the most common reasons for admission to the emergency department. Abdominal pain may be nonspecific, increasing the difficulty of accurately identifying the underlying cause. The classic symptoms of deep vein thrombosis are edema, redness, pain in the affected area, and tenderness on palpation. This case report aimed to demonstrate the thrombus observed in the right iliac and femoral vein in a young patient who applied to the ED with abdominal pain.

**Case:** An 18-year-old female patient applied to the emergency department with the complaint of abdominal pain that had worsened for the last three days. Abdominal ultrasound was requested to exclude acute appendicitis and adnexal pathologies. Abdominal ultrasound did not detect any pathology. Doppler ultrasound performed during obstetric and gynecological examination of the patient showed a suspicious thrombus image in the right femoral vein and contrast-enhanced abdominal computed tomography was requested. The patient, who was found to have thrombus in the right iliac and femoral veins, was hospitalized due to venous thromboembolism.

**Conclusion:** It is important for emergency physicians to keep venous thromboembolism in mind as a diagnosis in all patients (including young patients) presenting with abdominal pain.

**Keywords:** Emergency room, abdominal pain, venous thromboembolism, doppler, ultrasonography

#### ÖZ

**Amaç:** Karın ağrısı, acil servise en sık başvuru nedenleri arasındadır. Karın ağrısı spesifik olmayabilir ve altta yatan nedeni doğru bir şekilde belirleme zorluğunu artırır. Derin ven trombozunun klasik semptomları ödem, kızarıklık, etkilenen bölgede ağrı ve palpasyonda hassasiyettir. Bu olgu sunumunda karın ağrısı şikayeti ile acil servise başvuran genç bir hastada sağ iliak ve femoral vende saptanan trombüsü göstermeyi amaçladık.

**Olgu:** 18 yaşında kadın hasta son üç gündür şiddetlenen karın ağrısı şikayeti ile acil servise başvurdu. Akut apandisit ve adneksiyal patolojileri dışlamak için abdominal ultrason istendi. Abdominal ultrasonda herhangi bir patoloji saptanmadı. Hastanın obstetrik ve jinekolojik muayenesi sırasında yapılan Doppler ultrasonda sağ femoral vende şüpheli trombüs görüntüsü saptandı ve kontrastlı karın bilgisayarlı tomografisi istendi. Sağ iliak ve femoral venlerde trombüs tespit edilen hasta venöz tromboemboli nedeniyle hastaneye yatırıldı.

**Sonuç:** Karın ağrısı ile acil servise başvuran tüm hastalarda (genç hastalar dahil) venöz tromboemboli tanısının acil hekimleri için akılda tutulması önemlidir.

**Anahtar Kelimeler:** Acil servis, karın ağrısı, venöz tromboembolizm, doppler, ultrasonografi

Received: September 23, 2021

Accepted: February 8, 2022

<sup>1</sup> Yuksekova State Hospital, Emergency Medicine, Hakkari/Turkey.

<sup>2</sup> Sakarya University, Training and Research Hospital, Emergency Medicine Department, Sakarya/Turkey.

**Corresponding Author:** Sacit Akdeniz, MD **Address:** Yuksekova State Hospital, Emergency Medicine, Hakkari/Turkey. **Phone:** +905395723060 **e-mail:** [sacit.akdeniz@gmail.com](mailto:sacit.akdeniz@gmail.com)

**Atif için/Cited as:** Akdeniz S, Ercan B, Yurumez Y, Durmus E, Guner NG, Yilmaz V. An Extraordinary Case Presentation: Right Iliac and Femoral Vein Thrombus Anatolian J Emerg Med 2022;5(2):86-88. <https://doi.org/10.54996/anatolianjem.1077385>

## Introduction

Abdominal pain is among the most common causes of emergency department (ED) admissions and concerns all age groups (1). However, it can be caused by various illnesses, from mild cases to life-threatening conditions (2). Because abdominal pain may be nonspecific, this increases the difficulty of accurately identifying the underlying cause. The clinical evaluation is the first step of diagnosis. In practice, a preliminary diagnosis is decided based on medical history, physical examination, and laboratory parameters (3). Imaging modalities can raise diagnostic precision. Different imaging modalities such as plain radiography, ultrasound (USG), computed tomography (CT), and magnetic resonance imaging (MRI) have been used more over the years (4).

Venous thromboembolism (VTE) occurs due to excessive fibrin formation in the circulation and is the cause of pulmonary embolism and deep vein thrombosis (DVT). The main risk factors are genetic causes, immobilization, trauma, cancer, oral contraceptive (OCS) use, pregnancy, and major surgery (5). The classic manifestations of DVT are edema, redness, pain at the affected site, tenderness on palpation, and Homan's sign. The DVT produces subtle and nonspecific symptoms, including a mild cramping sensation or a feeling of fullness in the cruris (6,7). The clinical presentations of DVT can alter and may contain edema, erythema, the warmth of the affected extremity, tenderness to palpation throughout the distribution of the deep venous system, enlargement of the superficial collateral veins, and palpable venous cord. Because the left iliac vein is vulnerable to compression by the left iliac artery (May-Thurner syndrome), DVT occurs in the left extremity slightly more frequently than in the right extremity. Less than 10% of diagnosed patients have bilateral extremity DVT (8).

Due to the high number of patients who applied to the emergency department with the complaint of abdominal pain and the wide diagnostic spectrum, the diagnosis of DVT is not considered first when diagnosing these patients. In this case report, we aimed to show the thrombus observed in the right iliac and femoral vein in a young patient who applied to the emergency department with the complaint of abdominal pain.

## Case Report

An 18-year-old female patient applied to the ED with worsening abdominal pain for the last three days. According to patient history the pain had started around the umbilicus, but she felt the pain mostly in the right lower quadrant when she applied to the ED. Also the patient had polycystic ovary syndrome and uses OCS for this condition. However, there was no remarkable feature in her family history or any abnormality in the vital signs. Her general condition was good; also, she was conscious, cooperative, and oriented. In her physical examination, there were tenderness and

defense in the right lower quadrant of the abdomen. Other system examinations were normal. Tests results were; white blood cells: 12.300 / $\mu$ L, hemoglobin: 9.91 g/dL, hematocrit: 31.3%, and CRP: 83.48 mg/L. First of all, abdominal USG was requested to exclude acute appendicitis and adnexal pathologies. Since no feature was detected on USG, she was consulted to the obstetrics and gynecology department. Contrast-enhanced abdominal CT was requested because of suspicious thrombus image in the right femoral vein as a result of Doppler USG performed during obstetric and gynecological examination (Figure 1, 2). The patient, who was found to have thrombus in the right iliac and femoral veins as a result of CT, was consulted with cardiovascular surgery and then hospitalized for venous thromboembolism. The patient, whose medical treatment was arranged during hospitalization, was followed up with routine control recommendations. Written informed consent was obtained from the patient for publication of this case report and any accompanying images.

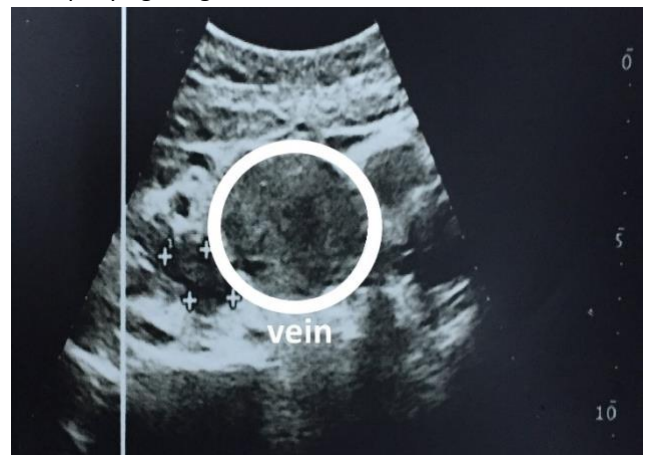


Figure 1: Doppler USG; Thrombus Image in The Right Femoral Vein

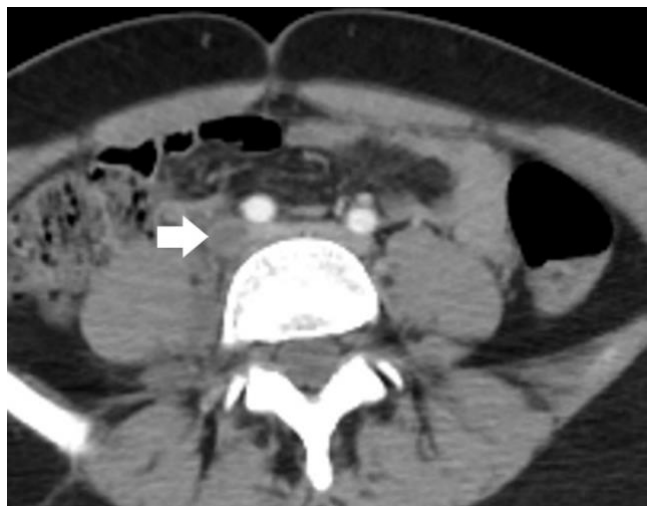

Figure 2: Abdominal CT; Thrombus in The Right Iliac Vein

## Discussion

Abdominal pain is one of the most common complaints of patients presenting to ED and constitutes 5-10% of all admissions. Evaluation of the ED patient with acute abdominal pain can be challenging as several factors may

obscure clinical findings that lead to misdiagnoses and subsequent adverse outcomes (9). In our case, the patient first had pain around the umbilicus and then in the right lower quadrant, so she had a wide range of pre-diagnosis. Acute appendicitis is the most common cause of right lower quadrant pain and is the focus of imaging evaluations in this area. Gynecological and obstetric causes of abdominal pain in women of reproductive age (eg, ectopic pregnancy, ovarian cyst, ovarian torsion, pelvic inflammatory disease) are important considerations in addition to common diagnoses in the general population. Transvaginal or transabdominal USG of the pelvis is the recommended imaging study in women of reproductive age with a suspected gynecological etiology (10). In our case, USG was performed first, as the patient was in childbearing age. Later, when thrombus was suspected, Doppler USG and contrast-enhanced abdominal CT were performed to confirm the diagnosis.

Factors for VTE include cancer, surgery, trauma or fracture, immobilization, pregnancy and postpartum period, long-distance travel, hospitalization, catheterization, acute infection and obesity, OCS or hormone therapy (11). In our case, only OCS was used as a risk factor for VTE. No other risk factors were found in the anamnesis and physical examination.

May-Thurner syndrome results from compression of the left iliofemoral vein by the right common iliac artery just after it exits the abdominal aorta and before the iliofemoral junction. Although May-Thurner syndrome primarily results in thrombosis of the left iliofemoral veins, 'right' sided May-Thurner syndrome has also been reported rarely (12). Although May-Thurner syndrome was not considered in our patient, the fact that the thrombus was in the right iliac and femoral veins and that it was seen more frequently in the left iliac and femoral veins in the literature still makes our case special.

## Conclusion

In patients who apply to the ED with abdominal pain, the initial diagnoses can be usually thought of by emergency physicians for acute appendicitis or adnexal pathologies in female patients, even though venous thromboembolism is not a common situation. Therefore, it is important for emergency physicians to keep venous thromboembolism in mind as a diagnosis in all patients (including young patients) presenting with abdominal pain. Clinicians should question patients' risk factors and should not miss specific findings for VTE on physical examination. An unnoticed case of VTE may later come to the emergency room with a mortal diagnosis.

**Conflict of Interest:** No conflict of interest was declared by the author.

**Financial Disclosure:** No financial disclosure was declared by the author.

**Authors Contribution:** All authors contributed equally to the preparation of the article.

**Informed Consent Statement:** Written informed consent was obtained from the patient for publication of this case report and any accompanying images. A copy of the written consent is available for review in this journal.

## References

1. Kamin RA, Nowicki TA, Courtney DS, Powers RD. Pearls and pitfalls in the emergency department evaluation of abdominal pain. *Emerg Med Clin North Am.* 2003;21(1):61-72. doi:10.1016/S0733-8627(02)00080-9.
2. Laméris W, van Randen A, van Es HW, et al. Imaging strategies for detection of urgent conditions in patients with acute abdominal pain: diagnostic accuracy study. *The BMJ.* 2009;338:b2431. doi:10.1136/bmj.b2431.
3. Guneyso F, Durmus E. Predictive role of serum markers in the evaluation of acute abdomen. *Journal of Contemporary Clinical Practice.* 2021;7(2):48-55. doi:10.18683/jccp.2021.1071.
4. Gans SL, Pols MA, Stoker J, Boermeester MA, Group OB of the ES. Guideline for the Diagnostic Pathway in Patients with Acute Abdominal Pain. *Dig Surg.* 2015;32(1):23-31. doi:10.1159/000371583.
5. Beckman MG, Hooper WC, Critchley SE, Ortel TL. Venous Thromboembolism: A Public Health Concern. *Am J Prev Med.* 2010;38(4):S495-S501. doi:10.1016/j.amepre.2009.12.017.
6. Kahn SR. The post-thrombotic syndrome: progress and pitfalls. *Br J Haematol.* 2006;134(4):357-365. doi:10.1111/j.1365-2141.2006.06200.x.
7. Schulman S, Lindmarker P, Holmström M, et al. Post-thrombotic syndrome, recurrence, and death 10 years after the first episode of venous thromboembolism treated with warfarin for 6 weeks or 6 months. *J Thromb Haemost.* 2006;4(4):734-742. doi:10.1111/j.1538-7836.2006.01795.x.
8. Enden T, Haig Y, Kløw NE, et al. Long-term outcome after additional catheter-directed thrombolysis versus standard treatment for acute iliofemoral deep vein thrombosis (the CaVenT study): a randomised controlled trial. *The Lancet.* 2012;379(9810):31-38. doi:10.1016/S0140-6736(11)61753-4.
9. Govender I, Rangiah S, Bongongo T, Mahuma P. A primary care approach to abdominal pain in adults. *South Afr Fam Pract.* 2021;63(1):5280. doi:10.4102/safp.v63i1.5280.
10. Cartwright SL, Knudson MP. Diagnostic Imaging of Acute Abdominal Pain in Adults. *Am Fam Physician.* 2015;91(7):452-459.
11. Crous-Bou M, Harrington LB, Kabrhel C. Environmental and Genetic Risk Factors Associated with Venous Thromboembolism. *Semin Thromb Hemost.* 2016;42(8):808-820. doi:10.1055/s-0036-1592333.
12. Mangla A, Hamad H. May-Thurner Syndrome. In: *StatPearls.* StatPearls Publishing; 2022. Accessed February 11, 2022. <http://www.ncbi.nlm.nih.gov/books/NBK554377/>.