

First Case of Enzootic Nasal Adenocarcinoma (ENA) in a Sheep in Turkey

Özlem ÖZMEN¹, Nilay SERPİN¹

¹ Mehmet Akif Ersoy University, Faculty of Veterinary Medicine, Department of Pathology, Burdur

Geliş Tarihi: 29-03-2016 Kabul Tarihi: 01-04-2016

Makale Kodu: 5000183436

ABSTRACT

A 2-year-old sheep presented with complains of nasal discharge and respiratory distress from a flock consisting 125 animals. Owner stated that the ewe started having clear nasal discharge more than three months and 15 sheep died with similar clinical symptoms in 3 years of period. During the clinical examination, depression and inappetence were observed to the sheep. Because of poor prognosis the ewe was euthanatized. At necropsy, bilateral tumors were seen in nasal cavity. Masses were soft, pinkish color, covered by mucinous exudate and completely filled the nasal cavity, invasion to the nasal sinuses were observed. The tumors localized in the right and left side of nasal cavity were 4,5x4x2 cm and 9,5x10x4 cm in diameters respectively. At the histopathological examination, the mass consisted of well-differentiated cuboidal to columnar cells with moderate amount of eosinophilic cytoplasm and round to oval nuclei. According to clinical and pathological findings the mass diagnosed as Enzootic Nasal Adenocarcinoma. This is the first Enzootic Nasal Adenocarcinoma report in a sheep in Turkey.

Keywords: *Enzootic Nasal Adenocarcinoma, Sheep, Pathology.*

TÜRKİYE'DE BİR KOYUNDA İLK ENZOOTİK NAZAL ADENOKARSİNOM (ENA) OLGUSU

ÖZET

İki yaşlı bir koyun, 125 hayvanlık bir sürden burun akıntısı ve solunum güçlüğü semptomları ile getirildi. Hayvan sahibi koyunda 3 aydan daha fazla devam eden, şeffaf bir burun akıntısı olduğu ve sürüde 3 yıllık bir sürede bu semptomlar ile 15 koyunun öldüğünü bildirdi. Klinik muayenede koyunda depresyon ve iştahsızlık gözlemlendi. Prognozun kötü olması sebebiyle hayvana ötenazi yapıldı. Nekropside, burun boşluğunda bilateral tümörler saptandı. Burun boşluğunu tamamen dolduran kitleler yumuşak, pembe renkli ve üzeri mukoid bir eksudatla kaplı görünümdeydi ve nazal sinuslara invazyon gözlemlendi. Sağ burun boşluğuna lokalize olan tümör kitlesi 4,5x4x2 cm ve sol taraftaki kitle ise 9,5x10x4 cm boyutlarındaydı. Histopatolojik incelemede kitlenin iyi diferensiyel kübik veya kolumnar şekilli, bol, eozinofilik sitoplazmalı ve yuvarlak veya oval çekirdekli hücrelerden oluştuğu gözlemlendi. Klinik ve patolojik bulgulara göre tümör Enzootik Nasal Adenokarsinom olarak teşhis edildi. Bu Türkiye'de bir koyunda saptanan ilk Enzootik Nasal Adenokarsinom raporudur.

Anahtar Kelimeler: *Enzootik Nasal Adenokarsinom, Koyun, Patoloji.*



İletişim / Correspondence

Mehmet Akif Ersoy University, Faculty of Veterinary Medicine, Department of Pathology, İstiklal Yerleskesi,
TR 15030 Burdur TURKEY



0248 213 21 70



ozlemozmen@mehmetakif.edu.tr

INTRODUCTION

Enzootic Nasal Adenocarcinoma (ENA) is a neoplasm of the secretory epithelial cells of the nasal cavity of small ruminants (1-5). The tumors can arise unilaterally or bilaterally, originating from the mucosal glands of ethmoidal area and often expanding to occlude the nasal cavity. The causal agent of ENA is a retrovirus (4). The main clinical finding is related with respiratory problems and the tumor easily diagnosed by pathological examination of nasal cavity. Pathoanatomic diagnosis of ENA is usually confirmed with the histopathological examination. ENA is classified as a low-grade adenocarcinoma and metastasis of the tumors are very rare but invasions may be seen (1,2). The classical clinical signs of ENA include persistent nasal discharge, stridor, nostril flaring, head shaking, sneezing, open mouth breathing, dyspnea and sometimes facial asymmetry. This tumor generally occurs in goats and has been reported from numerous countries (3,6-8). ENA cases in goats also diagnosed in Turkey but there is no report available about occurrence of this tumor in sheep in our country (9).

A 2-year-old sheep from a herd numbering 125 animals with a 3-year history of respiratory nasal problems and death with respiratory distress were presented to Mehmet Akif Ersoy University, Veterinary Faculty, Department of Pathology for diagnosis from Isparta Gelendost. Clinically, emaciation, respiratory distress and mucous nasal discharge were observed. Owner stated that 15 sheep died with similar clinical symptoms in 3 years period.

The sheep was depressed and humanely euthanized for differential diagnosis. At necropsy, bilateral expansile, friable intranasal tumors that localized in the nasal cavity were found. The nasal tumor localized

right side of the nasal cavity was originated from the ethmoidal mucosa and 4,5x4x2 cm in diameter. The tumor localized in left nasal cavity was 9,5x10x4 cm in diameter. Masses were soft, pinkish color and completely filled the nasal cavity, invasion to the nasal sinuses were observed (Fig.1). The surface of the tumoral masses was covered by clear mucous exudate. Tumors were in lobular appearance and some areas of the tumor were firm and friable. Slightly softening but not perforation was observed on the nasal bones. The mass compressed and invade in the frontal sinuses. No metastases detected in any organ both on gross and microscopical examination.

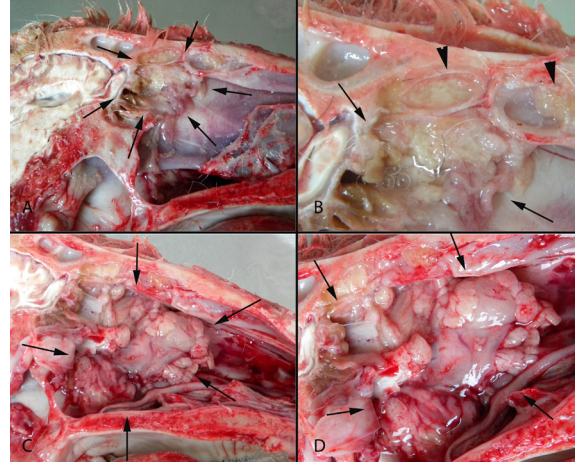


Figure 1. Sagittal section of the head of sheep with enzootic nasal adenocarcinoma. (A) Localization of the tumors in right nasal cavity (arrows), (B) Higher magnification of the Fig (1A), tumor (arrows), infiltrative masses in the nasal sinuses (arrow heads). (C) Gross appearance of the tumor localized and totally filled the left side of the nasal cavity (arrows) (D) Higher magnification of the Fig (1C), tumoral mass (arrows).

Figür 1. Enzootik nazal adeno karsinomlu koyun başının sagital kesiti. (A) Sağ burun boşluğunda tümörün yerleşimi (oklar), (B) Figür (1A)'nın yakın görünümü, tümör (oklar), nazal sinüslerde tümör infiltrasyonları (ok başları). (C) Burun boşluğu son tarafını tamamen dolduran Tümör kitlenin makroskopik görünümü (oklar) (D) Figür (1C)'nin yakın görünümü, tümör kitleler (oklar)

For histopathological examinations, tissue samples were taken from tumors and the visceral organs, fixed in 10% neutral formalin, routinely processed. Five micrometer section were taken by rotary microtome (Leica-2155)

and stained with Hematoxylin-Eosin (HE). At the histopathological examination, acinar type was diagnosed. A well-differentiated, epithelial cells contained acini and tubules supported by scant fibrovascular stroma. The tumoral cells were cuboidal or columnar with distinct cell borders and a moderate amount of eosinophilic cytoplasm. The nuclei were uniform round to oval and centrally located. No indication of pleomorphism and cellular atypia were observed (Fig.2). In well vascularized mass, slight necrosis, inflammatory infiltrations and mitoses were very rarely seen.

The ENA is a chronic and afebrile disease characterized by a profuse initial seromucous and then purulent nasal exudate associated with clinical signs of respiratory distress. In the late period of the disease, facial swellings, sometimes with seromucous exudation are found because of nasal bone erosion and skin ulceration (8,10). At necropsy, the tumors may be unilateral or bilateral. They present as polipoid to confluent masses originated from the ethmoid region with strong association with etmoidal mucosa. In most cases, they have a granular or papillary surface covered by mucus (1,8,11).

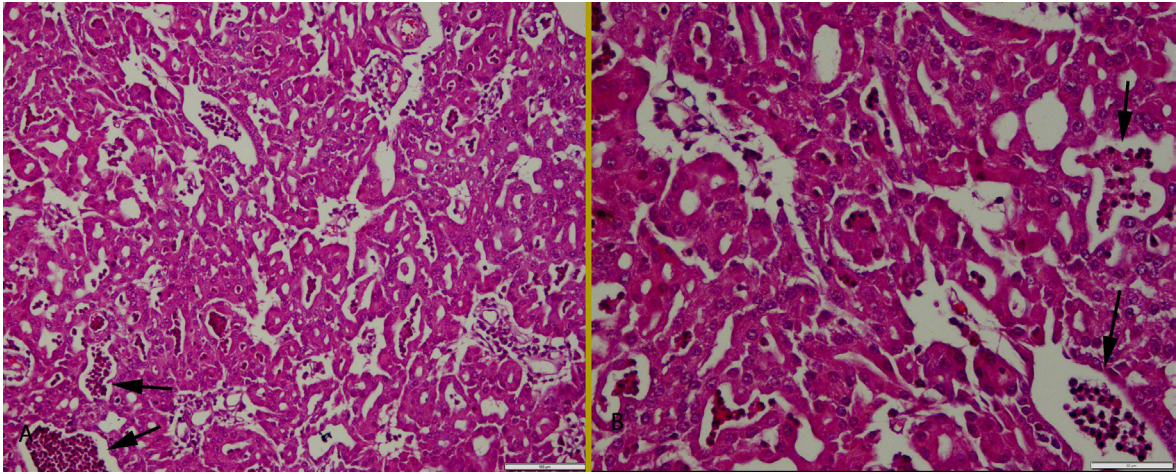


Figure 2. (A) Histopathological appearance of the acinar type ENA, slight inflammatory infiltrations (arrows) in the mass, HE, Bar= 100 μ m. (B) Higher magnification of the tumoral cells and inflammatory infiltrations (arrows), HE, Bar= 50 μ m.

Figür 2. (A) Asiner tip ENA'nın histopatolojik Görünümü, kitledeki belirgin yangısal infiltrasyonlar (oklar), HE, Bar= 100 μ m. (B) Tümör hücreleri ve yangısal infiltrasyonların yakından görünümü (oklar), HE, Bar= 50 μ m.

DISCUSSION

ENA is a contagious neoplasm of the nasal mucosal glands and occurs following infection by retrovirus in sheep or goats and caused important economical loses in small ruminant industry. ENA has been reported from Spain, Italy, Greece and Slovenia (2,4). This tumor has been also diagnosed in goats in Turkey (9). But there is no ENA report in sheep in Turkey.

Clinical and pathological findings in this case were characteristic and similar to those described previously. No facial deformities observed in this case.

The most common subtype is papillary type. In addition, mucinous, tubular, and acinar patterns are seen. The tumors in goats are interpreted to be well-differentiated (low grade) carcinomas, also with papillary, tubular, or acinar patterns (2,4,9). In this case the tumor had benign cellular appearance and at the histopathological examination acinar type was diagnosed.

ENA is a fatal viral disease of ruminants. It always should be taking into consideration of the differential diagnoses, when dyspnea

and chronic nasal discharge are noticed in the small ruminants. The suspicion of ENA can be easily confirmed by pathoanatomic examination of sagittal section of the head and histopathologic examination of the tumor. In this case, the owner stated contagious history of the disease but origin of the disease was unknown. Characteristic progressive respiratory clinical signs were described for this sheep because of the large size of the tumor. We report ENA in goats previously and now in a sheep in Turkey. The aim of this case report is to take attention of practitioner to ENA in respiratory distress problems in goats and sheep. This disease may be a problem in our small ruminant industry due to contagious and progressive behavior. The only way to control of ENA is the culling of the affected animals. For that reason, early diagnosis of the disease is very important. This study showed that ENA exists also in sheep in Turkey.

REFERENCES

1. De las Heras M, Garcia de Jalon JA, Balaguer L, Badiola JJ. Pathology of enzootic nasal tumor in thirty-eight goats. *Vet Pathol.* 1991; 28: 474-481.
2. Jones TC, Hunt RD, King NW. Nasal passages and paranasal sinuses neoplasms. In: *Veterinary Pathology*, 6th ed. Blackwell Publishing, Iowa. 2006
3. De las Heras M, Minguijon E, Ferrer LM, Ortin A, Dewar P, Cebrian LM, Pascual Z, Garcia L, Garcia de Jalon J, Sharp JM. Naturally occurring enzootic nasal tumor of sheep in Spain: pathology and associated retrovirus. *Eur J Vet Pathol.* 1998;4: 11-16.
4. Lopez A. Respiratory system. In: Carlton WW, McGavin MD, Zachary JF (Eds.) *Thomson's Special Pathology*, 3rd ed, Mosby-Year Book Inc, Missouri. 2001
5. De las Heras M, Ortin A, Cousens C, Minguijon E, Sharp JM. Enzootic nasal adenocarcinoma of sheep and goats. *Curr Top Microbiol Immunol.* 2003; 275: 201-223.
6. McKinnon AO, Thorsen J, Hayes MA, Misener CR. Enzootic nasal adenocarcinoma of sheep in Canada. *Can Vet J.* 1982; 23: 88-94.
7. Duncan JR, Tayler DE, Van der Maaten MJ, Andersen JR. Enzootic nasal adenocarcinoma in sheep. *JAVMA.* 1967; 151,732-734.
8. Svara T, Gombac M, Vrecl M, Jntes P, Kostanjsek R, Pogacnic R, Pogacnik M. Enzootic nasal adenocarcinoma of sheep in Slovenia. *J Vet Med A.* 2006; 53: 26-29.
9. Ozmen O, Sahinduran S, Haligur M, Demir N. Clinical, pathological, immunohistochemical and ultrastructural observations on Enzootic Nasal Adenocarcinoma in five goats. *Kafkas Univ Vet Fak Derg.* 2010; 16(4): 633-639.
10. Palmarini M, Mughetti L, Tollis M, Alunni L, Vitellozzi G. Il tumore intranasale enzootico della capra. *Summa.* 1994; 3: 49-53.
11. Wilson DW, Dungworth DL. Tumors of the respiratory tract. In: Meuten DJ (Ed), *Tumors in the Domestic Animals*, 4th ed. Iowa State Press, Iowa. 2002