

**Bilateral Tek Sistem Ektopik Üreter: Erken Tanı ve Başarılı Tedavi****Bilateral Single System Ectopic Ureter: Early Diagnosis and Successfully Treatment**<sup>1</sup>Sevim YENER, <sup>2</sup>Zekeriya İLÇE, <sup>2</sup>Aytekin KAYMAKÇI<sup>1</sup>Health Sciences University Umraniye Training and Research Hospital / Department of Pediatric Urology, Istanbul/Turkey<sup>2</sup>Health Sciences University Umraniye Training and Research Hospital / Department of Pediatric Surgery, Istanbul/TurkeySevim Yener: <https://orcid.org/0000-0002-7327-8228>Zekeriya İlçe: <https://orcid.org/0000-0002-3473-5051>Aytekin Kaymakçı: <https://orcid.org/0000-0002-6147-5566>**ÖZ**

Bilateral tek sistem ektopik üreter (BTSEÜ) ürolojideki en nadir durumlardan biridir. Şimdiye kadar 80'den daha az olgu bildirilmiştir. Altta yatan anomaliye göre değişkenlik göstermekle birlikte bu hastalarda inkontinansın yönetimi zordur. Trigon ve mesane boynu bölgesinin yetersiz gelişmesi nedeniyle üriner kontinans ve uzun kuru aralıkların elde edilmesi son derece nadirdir. Burada üriner diversiyona veya mesane boynu rekonstrüksiyonuna gerek kalmadan sadece üreterik reimplantasyon yapılarak tatmin edici üriner kontinans ve mesane kapasitesiyle birlikte normal böbrek fonksiyonları sağlanan BTSEÜ olgusu sunulmuştur.

**Anahtar Kelimeler:** Ektopik üreter, hidroureteronefroz, inkontinans

**ABSTRACT**

Bilateral single system ectopic ureter (BSSEU) is one of the rarest conditions in urology. Fewer than 80 cases have been reported so far. Although it varies according to the underlying anomaly, incontinence is difficult to manage in these patients. Urinary continence and long dry intervals are extremely rare due to insufficient development of the trigone and bladder neck region. Here, we present a case of BSSEU, with satisfactory urinary continence and bladder capacity, as well as normal renal functions, by ureteric reimplantation without the need for urinary diversion or bladder neck reconstruction.

**Keywords:** Ectopic ureter, hydroureronephrosis, incontinence

**Sorumlu Yazar / Corresponding Author:**

Sevim Yener  
Elmalıkent, Adem Yavuz Cd., 34764 Ümraniye/İstanbul  
Tel: +90 (216) 632 18 18  
E-mail: [sevimyener@msn.com](mailto:sevimyener@msn.com)

**Yayın Bilgisi / Article Info:**

Gönderi Tarihi/ Received: 01/03/2022  
Kabul Tarihi/ Accepted: 08/04/2022  
Online Yayın Tarihi/ Published: 01/06/2022

**Atf/ Cited:** Yener S and et al. Bilateral Single System Ectopic Ureter: Early Diagnosis and Successfully Treatment. *Online Türk Sağlık Bilimleri Dergisi*, 2022;7(2):329-332. doi: 10.26453/otjhs.1080441

**INTRODUCTION**

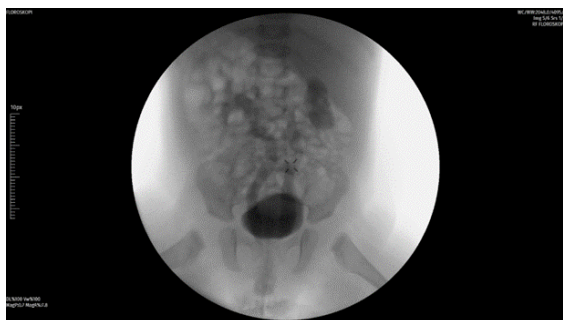
An ectopic ureter is an opening in a region other than the posterolateral aspect of the trigon.<sup>1</sup> Despite this embryological absence of the bladder neck and trigon, some patients achieve continence with bladder neck reconstruction or ureter reimplantation alone without urinary diversion. Here, we present a bilateral single system ectopic ureter case who became continent with bilateral ureter reimplantation and whose bilateral renal functions were preserved. In this case, we aimed to present a case with bilateral single system ectopic ureter, no dysplastic kidney, and postoperative continence.

**CASE**

Certificate of consent has been received. Ethics committee approval is not required for case report.

A three-month-old female patient presented with recurrent urinary tract infection and fever since birth. Renal function tests were found to be normal (creatinine 0.4 mg/dl). There was pyuria in the complete urinalysis and Escherichia Coli (100,000 CFU/ml) growth in the urine culture. Ultrasonography revealed bilateral grade 1 hydroureronephrosis. The bladder was found to be normal. Antibiotic prophylaxis treatment was started. Voiding cyst-

ourethrography was performed under sterile urine conditions. Grade 4 vesicoureteral reflux was observed on the left and grade 5 reflux on the right in the voiding phase. Bladder capacity was normal (Figure 1).



**Figure 1.** Voiding cystourethrography image (bilateral vesicoureteral reflux).

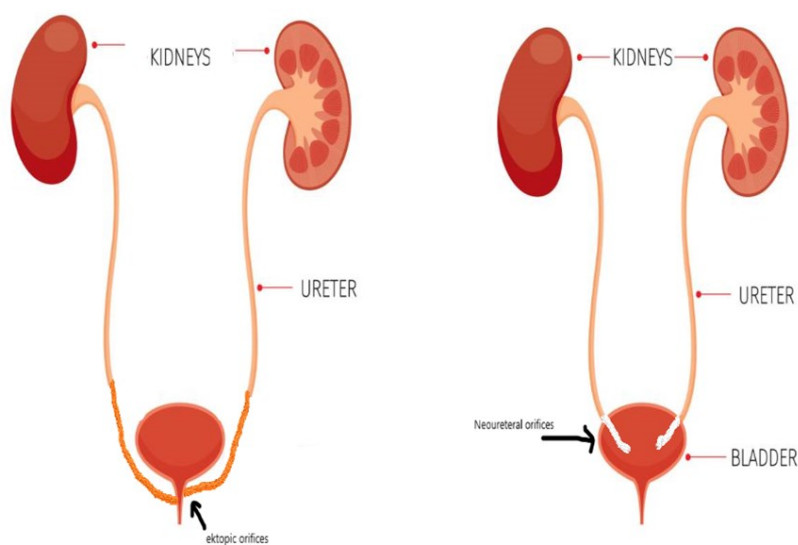
In the static kidney scintigraphy of the patient, radiopharmaceutical involvement in both renal parenchyma was sufficient and the contours of the kidneys were regular. There was a hypoactive area secondary to the medial side of the right kidney to the posterior pelvicalyceal structures. The contribution of the right kidney to the total renal function was 53.2%, and the contribution of the left kidney was 46.8%.

Diagnostic cystoscopy was performed at the age of 6 months in the patient whose symptomatic urinary tract infection continued under prophylaxis. Bilateral ectopic opening orifices was observed at the level of

the urethra-bladder neck at the level of 10 and 2 o'clock. No other intra vesical orifice was observed. Trigone development was not complete, but insufficient. Retrograde pyelography was performed by passing catheters through both very wide orifices with ectopic opening orifices. Bilateral wide tortuous ureter and dilated pelvicalyceal structures were observed. Bladder capacity was found to be approximately 40 ml, a volume suitable for the expected bladder capacity. Bilateral ureteral reimplantation was performed at the age of 12 months (Figure 2).

During the release of the patient's ectopic ureters, aggressive dissection of the bladder neck was avoided with an extravesical approach. In accordance with the Politano Leadbetter method, the ureters were first released with an extravesical approach and then ureteroneocystostomy was completed with an intravesical approach. No additional procedures were performed, except gentle dissection of the bladder neck to prevent incontinence.

Postoperative 6th and 12th months follow up while bilateral kidney sizes and parenchymal thicknesses were within normal limits, grade 2 pelvicaliectasia was observed in the right kidney in the urinary ultrasonography in the postoperative 6th month follow-up. In the DMSA control at the 12th and 18th months, bilateral renal scar was absent and its functions were normal. There was no reflux in her perioperative voiding cystourethrography. Bladder capacity was 110 ml (Expected bladder capacity:120 ml). It was observed that the patient's urinary continence was achieved at the age of 2 years.



**Figure 2.** Preoperative ectopic opening schematic drawing (left side), postoperative ureteral reimplantation schematic drawing (right side).

## DISCUSSION AND CONCLUSION

About 80% of ectopic ureters are associated with the duplex system. Single system ectopias are less common (10-20%), while BSSEU's are even rarer.<sup>1,2</sup> Ensuring continence is the most important issue in the management of BSSEU. This anomaly is seen more frequently in female patients.<sup>3,4</sup> The most common presentation symptoms are urinary tract infection, incontinence, and kidney failure.<sup>5</sup> Preservation of kidney functions is the main goal in these patients, as in other anomalies. Discussions continue about whether to use only ureteral reimplantation or augmentation and bladder neck reconstruction with ureteral reimplantation or continent-urinary diversion and bladder neck closure in treatment planning. Kesavan et al. reported that the bladder neck and trigone were not developed in 75% of bilateral ectopic ureter cases and in 54% of unilateral ectopic ureter cases.<sup>6</sup> Heuser reported that ureteral reimplantation alone cannot solve the problem of continence due to insufficient development of the trigone and bladder neck.<sup>7</sup> Therefore, when deciding on surgery in children with bilateral single system ectopic ureter, subsequent surgical procedures should be kept in mind. Various procedures have been described in the literature by Young-Dees-Leadbetter, Kropp, including the pubovaginal sling to increase the artificial sphincter and bladder neck resistance. Jayanthi et al. reported that all patients were incontinent in their series consisting of 6 female and 1 male patients.<sup>8</sup> To prevent incontinence, a total of 8 surgical interventions were performed to increase bladder outlet resistance; Young-Dees-Leadbetter in 3 patients, Kropp in 2 patients, Stamey in 1 patient, Burch in 1 patient, and pubovaginal sling procedure in 1 patient. According to this study, Jayanthi et al. suggested that day and night continence was achieved only with bladder neck closure, appendicovesicostomy and augmentation.

Shimada et al. successfully treated two cases with hypoplastic bladder and BSSEU with staged surgery.<sup>9</sup> In the staged surgery, ureterovesicostomy was first performed between the dilate ureter and the lateral wall of the bladder. The purpose of performing ureterovesicostomy is stated to increase bladder capacity. When sufficient bladder capacity was reached, ureterocystostomy was performed. In these two patients, urinary incontinence was achieved without bladder augmentation and bladder neck surgery. The first point that attracted attention in our case was the absence of scarring in the kidneys despite the presence of recurrent urinary tract infection and the preservation of both renal functions. Sufficient bladder capacity was also determined as the second noteworthy positive data. We did not need a surgical procedure to increase the bladder capacity since it was determined that the bladder capacity of

the patient was sufficient during the diagnosis process. We did not have the chance to evaluate the continence at the age when the surgical procedure was planned, but it was observed that continence was achieved by the age of 2 years in the follow-up. A study supporting our data and results has also been reported by Podesta. He reported that a bladder with BSSEU is not necessarily under-capacity and that most patients can achieve normal bladder function and capacity with satisfactory continence, urethral normal voiding pattern.<sup>10</sup>

Our patient underwent bilateral ureteral reimplantation (Politano Leadbetter technique) and it was observed that the patient was completely continent in the follow-up. Therefore, we think that aggressive reconstructive surgery can be avoided by performing ureteral reimplantation alone in some patients with BSSUE. In rare cases, the bladder may not develop enough storage capacity to prevent incontinence.

In conclusion, the bilateral extravesical approach provided a good assessment of the location of ectopic openings and a controlled bladder neck dissection. Ureteroneocystostomy was completed with intravesical and trigone evaluation. We think that aggressive surgery should be avoided while performing bladder neck dissection in order to preserve sphincter function in cases with bilateral ectopic ureteral opening. In addition, the trans sphincteric opening of the ectopic ureters provided sufficient bladder capacity. We think that this situation has a positive effect on ensuring continence. In cases with small bladder capacity we think that this problem can be solved by performing augmentation with colocoloplasty or cecocoloplasty to enlarge the bladder capacity.

**Ethics Committee Approval:** Ethics committee approval is not required for case report. The patient / relatives have signed an informed consent / consent form, and the study was conducted in accordance with international declaration, guideline, etc.

**Conflict of Interest:** No conflict of interest was declared by the authors.

**Author Contributions:** Concept – SY, AK; Supervision – AK, Zİ; Materials – SY; Data Collection and/ or Processing – SY, AK; Analysis and/ or Interpretation – SY, Zİ, AK; Writing –SY, AK.

**Peer-review:** Externally peer-reviewed.

**Other Information:** Congress presentation, 16th Turkish Pediatric Urology Congress, 26-28 November 2021 (Oral Presentation) Bilateral Single System Ectopic Ureter: Early Diagnosis and Successfully Treatment

## REFERENCES

1. Meisheri IV, Bhatnagar SN. Bladder capacity in single system ectopic ureter with solitary kidney. *BHJ*. 2006;48(1):168-171.

2. Redman JF, Lightfoot ML, Reddy PP. Bilateral single system ectopia in a boy. *Urology*. 2002;60(3): 514.doi:10.1016/S0090-4295(02)01820-4
3. Gangopadhyaya AN, Upadhyaya VD, Pandey A, et al. Single system ectopic ureters in females: A single centre study. *J Indian Assoc Paediatr Surg*. 2007;12(4):202–205.
4. Chowdhary SK, Lander A, Parashar K, Corkery JJ. Single system ectopic ureter: a 15-year review. *Pediatr Surg Int*. 2001;17:638-641.doi:10.1007/s003830100011
5. Ritchey ML, Kramer SA, Benson Jr RC, Kelalis PP. Bilateral single ureteral ectopia. *Eur Urol*. 1988;14(1):41-45. doi:10.1159/000472895
6. Kesavan P, Ramakrishnan MS, Fowler R. Ectopia in unduplicated ureters in children. *Br J Uro*. 1977;49(6):481-493. doi:10.1111/j.1464-410x.1977.tb04188.x
7. Heuser M, Zoller G, Seseke F, Zappel H. Bladder dysfunction in children with single ectopic ureters. *J Pediatr Surg*. 2002; 37(5):15-17.
8. Jayanthi VR, Churchill BM, Khoury AE, McLorie GA. Bilateral single ureteral ectopia: difficulty attaining continence using standard bladder neck repair. *J Urol*. 1997;158(5):1933-1936. doi:10.1016/s0022-5347(01)64184-3
9. Shimada KHS, Taguchi K, Ikoma F. Clinical analysis of children with bilateral single ectopic ureter and single ectopic ureter in a solitary kidney. *Jpn J Pediatr Surg*.1992;28:356-363.
10. Podesta E, Scarsi PL, Di Rovasenda E, Ferretis, Magillo, Doderò P. Vesical continence in bilateral ectopic single ureters. *J Urol*.2001;165:2363-2365. doi:10.1097/00005392-200106001-00036