

# Struma Ovarii Presented With Pseudo-Meigs' Syndrome: A Case Report and Review of The Literature

## Pseudo-Meigs Sendromu ile Başvuran Struma Ovarii: Bir Olgu Sunumu ve Literatürün Gözden Geçirilmesi

Yakup BAYKUŞ<sup>1</sup>, Rulin DENİZ<sup>1</sup>, Muhammet Bora UZUNER<sup>2</sup>, Alihan TIĞLI<sup>3</sup>  
Nazlı ŞENER<sup>3</sup>

<sup>1</sup> Bandırma Onyedi Eylül University, Department of Obstetrics and Gynecology, Bandırma Turkey

<sup>2</sup> Bandırma Onyedi Eylül University, Department of Anatomy, Bandırma Turkey

<sup>3</sup> Bandırma Teaching Hospital, Obstretic and Gynecology, Bandırma, Turkey

Yazışma Adresi / Correspondence:

**Yakup BAYKUŞ**

T: +90 266 738 00 22

E-mail : dryakup01@hotmail.com

Geliş Tarihi / Received : 17.11.2021 Kabul Tarihi / Accepted: 07.12.2021

Orcid

 Yakup BAYKUŞ <https://orcid.org/0000-0001-5730-8477>

 Rulin DENİZ <https://orcid.org/0000-0002-7306-8212>

 Muhammet Bora UZUNER <https://orcid.org/0000-0001-6557-3086>

 Alihan TIĞLI <https://orcid.org/0000-0002-9404-4869>

 Nazlı ŞENER <https://orcid.org/0000-0002-3931-9452>

(Hippocrates Medical Journal / Hippocrates Med J 2021, 1(1):28-33) DOI:

### Summary

Pseudo-Meigs' syndrome is a clinical condition characterized by ascites and pleural effusion, accompanied by pelvic tumors other than ovarian fibroma. Struma ovarii is a tumor that can lead to this syndrome and is a variant of mature cystic teratoma. When presented with Pseudo-Meigs' syndrome, it is important because it can be confused with malignant ovarian tumors, peritonitis carcinomatosa and malignant pleural effusion. Another important factor is the disappearance of the ascites and pleural effusion and rapid regression of symptoms after the removal of the tumor. Accompanying ascites and high CA-125 values with struma ovarii is very rarely seen. In the present report, a 53-year-old patient with histopathological diagnosis of struma ovarii who had been operated because of presumptive diagnosis of ovarian malignancy and whose symptoms and complaints rapidly resolved during the postoperative period was presented. Pseudo-Meigs' syndrome should be considered among differential diagnoses in the presence of CA125 elevation, ovarian mass, ascites, pleural effusion in postmenopausal period. In addition, Pseudo-Meigs' syndrome, though rarely, should be considered among differential diagnoses in patients who have not yet lost their fertility potential but whose cytological examination yielded negative results in terms of malignancy, especially in the presence of unexplained ascites and pleural effusion

### Keywords

Pseudo-Meigs' Syndrome, Ascites, Hydrothorax.

### Öz

Pseudo-Meigs sendromu, over fibromu dışındaki pelvik tümörlerin eşlik ettiği asit ve plevral efüzyon ile karakterize klinik bir durumdur. Struma ovarii, bu sendroma yol açabilen bir tümördür ve matür kistik teratomun bir çeşididir. Pseudo-Meigs sendromu ile sunulduğunda malign over tümörleri, peritonit karinomatosis ve malign plevral efüzyon ile karıştırılabilmesi nedeniyle önemlidir. Bir diğer önemli faktör ise tümörün çıkarılmasından sonra asit ve plevral efüzyonun kaybolması ve semptomların hızla gerilemesidir. Struma ovarii; yüksek CA-125 değerleri ve eşlik eden asit ile çok nadir görülür. Bu yazıda over malignitesi ön tanısı ile opere edilen ve postoperatif dönemde semptom ve şikayetleri hızla düzelen, histopatolojik struma ovarii tanısıyla opere edilen 53 yaşında bir hasta sunuldu. Postmenopozal dönemde CA125 yüksekliği, over kitlesi, asit, plevral efüzyon varlığında yalnızca Meigs sendromu ayırıcı tanılar arasında düşünülmelidir. Ayrıca fertilitite potansiyelini henüz kaybetmemiş ancak sitolojik incelemesi malignite açısından olumsuz sonuç veren hastalarda, özellikle açıklanamayan asit ve plevral efüzyon varlığında nadiren de olsa Pseudo-Meigs sendromu ayırıcı tanılar arasında düşünülmelidir.

### Anahtar Kelimeler

Pseudo-Meigs Sendromu, Asit, Hidrotraks.

## IMPACT STATEMENT

**What is already known on this subject?** The presence of ascites and pleural effusions associated with an ovarian or gynecological tumor other than fibroma/thecoma is called pseudo-Meigs' syndrome and struma ovarii is responsible for 5% of the cases with this syndrome.

**What do the results of this study add?** When struma ovarii is presented with pseudo-Meigs' syndrome, it is important because it can be confused with malignant ovarian tumors, peritonitis carcinomatosa and malignant pleural effusion.

**What are the implications of these findings for clinical practice and/or further research?** Pseudo-Meigs' syndrome, though rarely, should be considered among differential diagnoses in patients who have not yet lost their fertility potential but whose cytological examination yielded negative results in terms of malignancy, especially in the presence of unexplained ascites and pleural effusion.

## INTRODUCTION

Struma ovarii are mature ovarian teratomas derived from one type of germ cell; these monodermal variants account for >5% of mature teratomas and 0.3–1% of ovarian tumours(1). It is usually asymptomatic but may cause abdominal and pelvic pain. Although it is a benign tumor, malignant transformation may also develop. The presence of ascites and pleural effusions associated with an ovarian or gynecological tumor other than fibroma/thecoma is called pseudo-Meigs' syndrome and struma ovarii is responsible for 5% of the cases with this syndrome(2). In an extensive search of the literature, Obeidat et al. presented 26 struma ovarii cases associated with ascites and raised CA-125 levels. Pleural effusion was noted in 15 cases(3).

A 53-year-old postmenopausal case with left ovarian mass and findings of high CA125 levels, ascites, and pleural effusion was suspected for ovarian malignancy and total hysterectomy+bilateral salpingoophorectomy was performed. The case was reported as a benign lesion as a result of frozen section examination, and the final histo-

pathological diagnosis was struma ovarii. Because of rapid resolution of ascites, and pleural effusions in the postoperative period the case was discussed in the light of relevant literature.

## CASE REPORT

A 53-year-old patient weighing 75 kg with gravida 3 and parity 3 was referred to our clinic from an external center with a prediagnosis of ovarian malignancy. Her history revealed that she had been in her postmenopausal period for 3 years. Her complete blood count and other biochemical parameters including albumin, thyroid function tests, complete urinalysis and coagulation parameters were within normal limits. CA-125:1057 U/ml and other tumor markers were within normal limits (AFP:3.32U/ml, CEA:3.74U/ml, CA-15-3:39.1 U/ml, CA19-9:18.2U/ml,  $\beta$ -hCG:1U/ml).

Physical examination revealed a mobile palpable mass in the lower abdomen and abdominal distension. Pelvic ultrasonography revealed a cystic mass containing 10x9 cm solid components in the left adnexal area (Figure1) and widespread ascitic fluid in the abdominal cavity (Figure2). Thoracoabdominal CT revealed pleural fluid in the right hemithorax and prominent atelectasis in the neighborhood, a heterogeneous contrast-enhanced 102x91x78mm lesion with a lobulated contour and containing necrotic areas (ovarian carcinoma?), multiple millimetric lymph nodes in the paraaortic area and mesentery, diffuse free fluid in the abdominal cavity.

Right chest tube was inserted in the patient with prominent dyspnea and pleural effusion. Serous fluid was drained, 2000 mL on the first, 1300 mL on the second and 1500 ml on the third day, and samples for cytologic examination were obtained. Cytology was reported as negative for malignancy.

Due to the decrease in dyspnea on the 4th day, and presumptive diagnosis of ovarian malignancy based on preexisting evidence, laparotomy was performed under general anesthesia. In exploration, uterus and right ovary were in normal appearance. A 9x8x7cm semisolid mass

with smooth surface without adhesions to the surrounding tissues was observed. On the surfaces of peritoneum, and intraabdominal organs tumoral implants and palpable retroperitoneal lymph nodes were not detected.

A sample was taken from the abdominal effusion for cytologic examination, left salpingo-oophorectomy was performed and the excised organ was sent for frozen section examination. Frozen section result was reported as a benign lesion, so total hysterectomy together with right salpingo-oophorectomy was performed.

The chest tube was removed because the amount of fluid coming from the chest tube decreased to 300 mL on the postoperative 1st day and any discharge was not observed on the second day. Repeated abdominal ultrasonography also revealed that ascites was completely resolved. The result of the final histopathology examination was reported as struma ovarii and the thyroid function test results on the 3rd postoperative day were found to be within normal limits, while the CA125 value decreased to 159 U/ml. In the postoperative period, and any complication did not occur, the patient was accepted as having pseudo-Meigs' syndrome and discharged on the 5th postoperative day.

## DISCUSSION

The association of benign ovarian fibroma, hydrothorax and ascites is defined as Meigs' syndrome. Pseudo-Meigs' syndrome is characterized by the association of other ovarian or pelvic tumors except the presence of ascites, hydrothorax and fibroma. It has been reported that leiomyomas are the most common cause of pseudo-Meigs' syndrome and struma ovarii are responsible for 5% of this syndrome(2). Tumor is typically seen in the reproductive period, but also peaks in the 5th and 6th decades. Struma ovarii is a rare tumor that was first described by Von Klden and Gottschalk in 1895 and it is a variant of mature cystic teratoma(4).

Although approximately 15% of mature cystic teratomas contain normal thyroid tissue, in struma ovarii more than 50% of the tumor is composed of thyroid tissue.

Despite the presence of this high proportion of thyroid tissue and the secretion of thyroid hormones from the tumor, only 5-8% of the patients who are usually asymptomatic manifest findings of hyperthyroidism and often present with a pelvic mass(5). Although the patients are asymptomatic, it has been also reported that they may enter into a state of hypothyroidism after removal of the tumor(6). In the light of this information, the patient who had no findings of hypothyroidism in the postoperative period was followed up with thyroid function tests.

In the cases of struma ovarii, ascites is present in about 15-20 of all cases, but rarely they lead to pseudo-Meigs' syndrome(7). As in our case, ascites and pleural fluid in Meigs' and pseudo-Meigs' syndromes are generally of transudative and rarely exudative type. However, the pathophysiology of ascites and pleural fluid is not clear. The possible cause of the ascites may be the transudative mechanism of the tumor surface that exceeds the resorptive capacity of the peritoneum(8). Meigs et al. reported that the pressure of the lymphatics of the tumor itself could cause fluid leakage from the lymphatics on the surface of the tumor(9). Pleural effusion is thought to be due to the passage of ascites fluid through openings in diaphragm, it is also stated that fluid secretion from the peritoneum, venous and/or lymphatic obstruction, decreased serum proteins and vascular endothelial growth factor, fibroblast growth factor and Interleukin 6 may play a role. Pleural effusion may be bilateral but it is usually on the right side as in our case and it is thought that the lymphatics are usually on the right side of the diaphragm(10).

The symptoms of struma ovarii are nonspecific, and resemble those of other ovarian tumors. In differential diagnosis, all benign and malignant ovarian tumors should be considered. Preoperatively its clinical diagnosis is very challenging, and the tumor is seen as a multicystic mass in the CT or as a moderate cyst wall thickness in the MRI. While as is reported its definitive diagnosis is based on histopathological examination results(11). In cases presenting with pseudo-Meigs' syndrome, progressively growing mass and increased abdominal distension

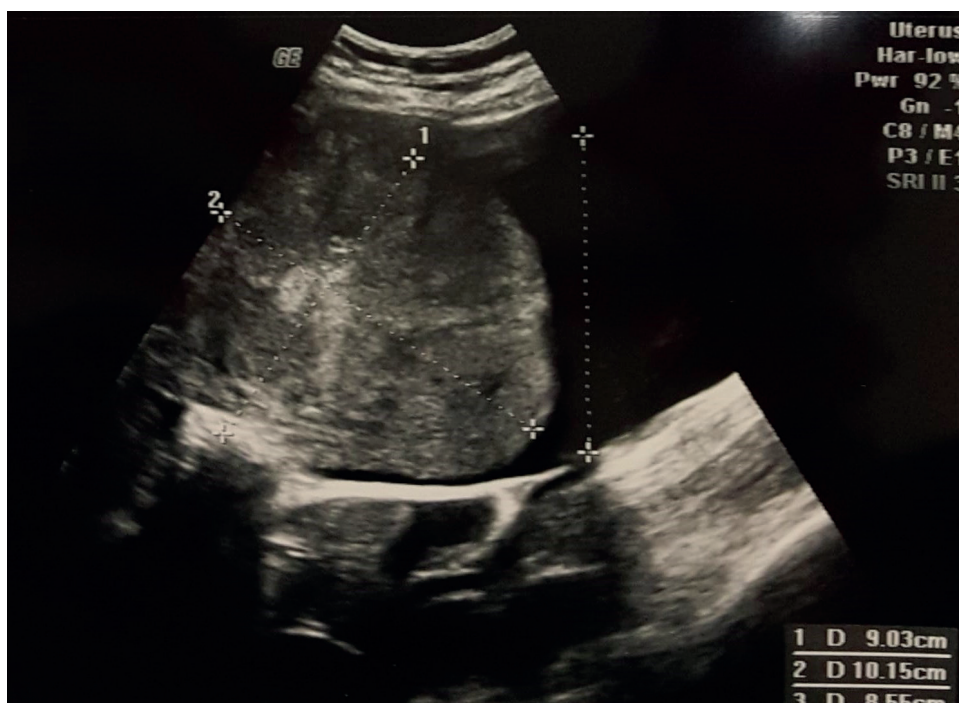


Figure 1. A cystic mass containing 10x9 cm solid components in the left adnexal area in pelvic ultrasonography

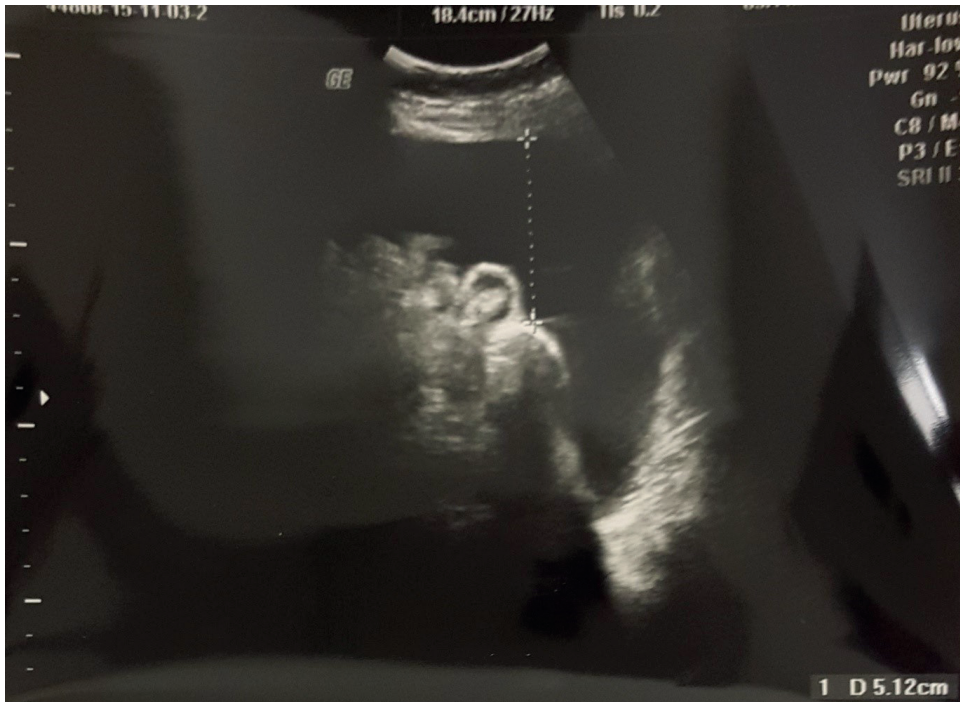due to ascites are frequently seen in patients with respiratory failure caused by pleural effusion(12). Patients may also present with symptoms and complaints of abdominal pain, weight loss, and fatigue(6). In our case, whose main complaints were generalized abdominal distention and dyspnea, the diagnosis was made based on histopathology results in the postoperative period in accordance with the literature.

Considering that pleural effusion is an inadequate prognostic factor in predicting the pelvic mass, patients with unexplained pleural effusion and ascites should be investigated in terms of possible presence of a pelvic tumor. Since data related to pseudo-Meigs' syndrome are very limited, they may be confused with malignant ovarian tumors with similar clinical data causing pleural metastasis and effusion. It may also lead to formulation of different diagnostic and therapeutic approaches. Therefore, increase in the information about these syndromes will also clarify the diagnosis, treatment and follow-up approaches. Since it is known that with the removal of the tumor, the ascites and pleural fluid disappear and symptoms rapidly regress,

a dramatic improvement will be achieved in the general health status of the patients and thus their quality of life may rapidly return to the pre-disease period(10). In our case, with the disappearance of ascites and pleural effusion, symptoms regressed rapidly in the postoperative period and a significant decrease in CA-125 value was also detected.

Association between struma ovarii and increased CA-125 levels is rarely seen. The mechanism behind raised CA-125 levels in cases of pseudo-Meigs' syndrome is still not understood, although Mui et al. have postulated that it is the result of free fluid irritation leading to inflammation of the pleural and peritoneal surfaces(13). Elevated serum CA-125 levels for a postmenopausal woman presenting with solid adnexal mass, ascites, and pleural effusion can be interpreted as highly suspicious case of malignancy(14). Surekha et al noted that the monodermal teratoma struma ovarii is a rare ovarian tumour; however, struma ovarii presenting with pseudo-Meigs' syndrome and raised cancer antigen CA-125 levels is even rarer. In another case hydropic leiomyoma presenting with pseu-





**Figure 2.** Widespread ascitic fluid in the abdominal cavity in pelvic ultrasonography.

do-Meigs' syndrome and raised CA-125 levels is reported. In elderly patients, this presentation can potentially lead to a misdiagnosis of a malignant ovarian carcinoma, resulting in unnecessary extensive surgery(15,16). Because of the presence of the ovarian mass, higher CA-125 levels, ascites and pleural fluid in the postmenopausal period, ovarian malignancy was considered, and surgery was planned for our case. However, when frozen section result was reported as a benign lesion, we proceeded with total hysterectomy together with bilateral salpingo-oophorectomy.

In postmenopausal cases, and in premenopausal patients who have lost their fertility potential total hysterectomy and bilateral salpingo-oophorectomy are apparently appropriate approaches. However, cystectomy or oophorectomy is an adequate treatment for women in reproductive period who have not yet lost their fertility potential.

In conclusion, in postmenopausal women with findings of CA-125 elevation, ovarian mass with ascites, pleural effusion who are scheduled for surgery considering priorly the presence of malignancy, frozen section examination should be performed with the thought of a preexisting tumor that

probably will lead to the development of pseudo-Meigs' syndrome. However, pseudo-Meigs' syndrome should be kept in mind in patients who have not yet lost their fertility potential, especially in the presence of unexplained ascites and pleural fluid yielding negative cytological examination results as for malignancy.

#### *Legends To Figures*

Figure 1. Pelvic ultrasonography showing a cystic mass containing 10x9 cm solid components in the left adnexal area.

Figure 2. Pelvic ultrasonography showing widespread ascitic fluid in the abdominal cavity.

#### *Acknowledgements*

We would like to thank our esteemed teacher, Professor Dr. Hüsnü Celik, for which we have benefited from their knowledge and skills.

#### *Declaration Of Interests*

None

## REFERENCES

1. Md Nor NB, Kusumoto T, Inoue S, Nakamura K, Seki N, Hongo A, et al. Three cases of struma ovarii underwent laparoscopic surgery with definite preoperative diagnosis. *Acta Med Okayama* 2013; 67:191–195.
2. Loizzi V, Cormio G, Resta L, Fattizzi N, Vicino M, Selvaggi L Pseudo-Meigs syndrome and elevated CA125 associated with struma ovarii. *Gynecol Oncol* 2005;97: 282-284. doi:10.1016/j.ygyno.2004.12.040
3. Obeidat R, Perren TJ, Saidi SA, Struma Ovarii Associated with Pseudo-Meigs' Syndrome and Elevated Serum CA 125: A Case Report and Literature Review, *Gynecol Obstet* 2012, 2:4. DOI: 10.4172/2161-0932.1000129
4. Szyfelbein WM, Young RH, Scully RE Struma ovarii simulating ovarian tumors of other types. A report of 30 cases. *Am J Surg Pathol* .1995; 19: 21-29. DOI:10.1097/00000478-199501000-00003
5. Yoo SC, Chang KH, Lyu MO, Chang SJ, Ryu HS, Kim HS. Clinical characteristics of struma ovarii. *J Gynecol Oncol*.2008; 19: 135-138. DOI:10.3802/jgo.2008.19.2.135
6. Jiang W, Lu X, Zhu ZL, Liu XS, Xu CJ Struma ovarii associated with pseudo-Meigs' syndrome and elevated serum CA 125: a case report and review of the literature. *J Ovarian Res*.2010;29; 3- 18. doi: 10.1186/1757-2215-3-18.
7. Amr SS, Hassan AA. Struma ovarii with pseudo-Meigs' syndrome: report of a case and review of the literature. *Eur J Obstet Gynecol Reprod Biol*. 1994; 55: 205-208. DOI:10.1016/0028-2243(94)90039-6
8. Samanth KK, Black WC 3rd Benign ovarian stromal tumors associated with free peritoneal fluid. *Am J Obstet Gynecol*. 1970; 107: 538-545. DOI:10.1016/s0002-9378(16)33939-4
9. Meigs JV. Fibroma of the ovary with ascites and hydrothorax; Meigs' syndrome. *Am J Obstet Gynecol*.1954; 67: 962-985. DOI:10.1016/0002-9378(54)90258-6
10. Chen A, Ho YS, Tu YC, Tang HS, Cheng TC. Diaphragmatic defect as a cause of massive hydrothorax in cirrhosis of liver. *J Clin Gastroenterol*. 1988; 10: 663-666. DOI:10.1097/00004836-198812000-00019
11. Jung SI, Kim YJ, Lee MW, Jeon HJ, Choi JS, Moon MH. Struma ovarii: CT findings. *Abdom Imaging*.2008;33: 740-743. doi: 10.1007/s00261-008-9362-1.
12. Kebapci M, Aslan O, Kaya T, Yalcin OT, Ozalp S. Pedunculated uterine leiomyoma associated with pseudo-Meigs' syndrome and elevated CA-125 level: CT features. *Eur Radiol*. 2002; 12: 127-129. DOI:10.1007/s00330-002-1464-5
13. Mui MP, Tam KF, Tam FK, Ngan HY. Coexistence of struma ovarii with marked ascites and elevated CA-125 levels: Case report and literature review. *Arch Gynecol Obstet*. 2009; 279:753–757. doi: 10.1007/s00404-008-0794-1.
14. Mitrou S, Manek S, Kehoe S: Cystic struma ovarii presenting as pseudoMeigs' syndrome with elevated CA125 levels. A case report and review of the literature. *Int J Gynecol Cancer* 2008, 18:372-375. doi: 10.1111/j.1525-1438.2007.00998.x.
15. Surekha Yadav, Reena Tomar, \*Nidhi Verma, Nita Khurana, Rewa Triathi. Struma Ovarii with Pseudo-Meigs' Syndrome and Raised Cancer Antigen-125 Levels Masquerading as an Ovarian Carcinoma Sultan Qaboos University. *Med J*, 2017, Vol. 17, Iss. 2, pp. e229–233, Epub. 20 Jun 17 doi: 10.18295/squmj.2016.17.02.017
16. Mehrnoosh Pauls, Heather MacKenzie, Ravi Ramjeesingh. Hydropic leiomyoma presenting as a rare condition of pseudo-Meigs syndrome: literature review and a case of a pseudo-Meigs syndrome mimicking ovarian carcinoma with elevated CA125. *BMJ Case Rep*. 2019;11:e226454. doi:10.1136/bcr-2018-226454