



## RESEARCH ARTICLE

### Comparison of the effects of intraocular pressure with phacoemulsification and extracapsular cataract extraction methods in dogs with cataract

Mustafa Arıcan<sup>1</sup>, Hanifi Erol<sup>2</sup>, Kurtuluş Parlak<sup>1</sup>, Ümit Kamış<sup>3</sup>, Nuri Yavru<sup>1</sup>

<sup>1</sup>Department of Surgery, Faculty of Veterinary Medicine, University of Selcuk, <sup>3</sup>Department of Ophtamology, Faculty of Medicine, Konya,

<sup>2</sup>University of Erciyes, Faculty of Veterinary Medicine, Department of Surgery, Kayseri, Turkey

Received: 17.05.2014, Accepted: 29.05.2014

\*marican@selcuk.edu.tr

#### Özet

**Arıcan M, Erol H, Parlak K, Kamış Ü, Yavru K.** Kataraktlı köpeklerde fakoemülsifikasyon ve ekstrakapsüler katarakt ekstraksiyon yöntemlerinin intraoküler basınçta etkilerinin karşılaştırılması.

#### Abstract

**Arıcan M, Erol H, Parlak K, Kamış U, Yavru K.** Comparison of the effects of intraocular pressure with phacoemulsification and extracapsular cataract extraction methods in dogs with cataract.

**Eurasian J Vet Sci, 2014, 30, 4, 188-194**  
DOI:10.15312/EurasianJvetSci.201447375

**Amaç:** Bu çalışmada intraoküler lens (IOL) konularak veya konulmadan yapılan ekstrakapsüler ekstraksiyon (EKKE) ve fakoemülsifikasyon (FAKO) yöntemlerinin 28 gün süre içinde göz içi basınçlarına etkilerini araştırılması amaçlanmıştır.

**Aim:** The aim of this study was to investigate the effects of intraocular pressure (IOP) in extracapsular extraction (ECCE) and phacoemulsification (PHACO) methods with or without intraocular lens (IOL) on dogs with cataract for a 28-day period.

**Gereç ve Yöntem:** Materyal olarak her iki cinsiyetten farklı yaşlarda vücut ağırlıkları 10 ile 30 kg arası olan katarakt teşhisi konulan 20 köpek kullanıldı. Katarakt teşhisi, direkt ve indirekt oftalmoskop, ultrasonografi, biyomikroskop ile yapıldı. Katarakt olguları klinik muayene ve ultrason ile immatür (7 olgu), matür (7 olgu) ve hipermatür (6 olgu) olarak sınıflandırıldı. Köpekler 10'arlı iki gruba ayrıldı. Katarakt teşhisi konulan 10 köpeğe EKKE ve diğer 10 köpeğe ise FAKO operasyonları gerçekleştirildi. Her iki grup için 41 dioptrilik tek parça akrilik intraoküler lens kullanıldı.

**Materials and Methods:** Twenty adult dogs of both sexes with cataracts, weighing between 10 to 30 kg and at different ages were used as materials. Cataracts were diagnosed by direct and indirect ophthalmoscopy, ultrasonographic examination and biomicroscopy. Cataracts were classified as immature (7 animals), mature (7 animals) and hypermature (6 animals). Dogs were divided into two groups each consisting of 10 animals. Ten dogs with cataract were operated on for ECCE and the other group of 10 dogs underwent a phacoemulsification procedure. In the two groups, 10 animals were used for 41 dioptre single-piece acrylic intraocular lens.

**Bulgular:** Göz içi basıncı IOL kullanılmayan EKKE grubunda 14. günde en düşük seviyede ölçüldü. IOL uygulanan grupta ise düzensiz seyir gösterdi. Fakoemülsifikasyon IOL uygulanmayan grupta ise göz içi basınçları 21. günde en düşük seviyede ölçüldü. Bununla birlikte 28. gün sonunda bütün değerlerin referans aralığında olduğu tespit edildi.

**Results:** Intraocular pressure was felt at the lowest level 14 days after the operation in the ECCE without IOL implanted group. The IOL implanted group showed irregular levels. Intraocular pressure level was the lowest on the 21st day, without IOL implanted group in phacoemulsification. However, all values remained within the reference values at the end of a 28-day period postoperatively.

**Öneri:** Kataraktlı olgularda göz içi basınçları dikkate alındığında her iki cerrahi uygulamanın kullanılabilmesi kanısına varılmıştır. Cerrahinin başarısı doğru hasta seçimi, doğru cerrahi teknik, doğru ekipman ile olmaktadır. Bunun yanı sıra katarakt immatür dönemde teşhis edilirse fakoemülsifikasyonun başarı oranı artmaktadır.

**Conclusions:** Both surgeries could be used for cataract cases in terms of IOP effects. Selection of the patient, correct surgical technique and adequate equipment are important for the success of a surgery. But, it has been also concluded that success of phacofragmentation surgery increased when the animals are in immature stages.

**Anahtar kelimeler:** Köpek, katarakt, fakoemülsifikasyon, göz içi basınç

**Keywords:** Dog, cataract, phacoemulsification, intraocular pressure





## Introduction

Cataracts are the most frequent causes of blindness in dogs. The remove of the lens for the repair of vision lost due to a cataract has become an ordinary procedure and technique in veterinary medicine (Honsho et al 2007). The success rate of cataract surgeries has risen significantly during the recent decades, especially due to the development of phacoemulsification and intra ocular lens (IOL) implantation (Gelatt and Gelatt 2001, Kecova and Necas 2004). The use of intraocular lenses is currently the treatment of choice (Kecova and Necas 2004) IOL implantation improves visions and reduces the formation of posterior capsule opacity (PCO) after surgery (Gelatt and Gelatt 2001).

Cataract extraction procedures are known to cause of increase in intraocular pressure (IOP) within the first few hours after surgery in dogs (Honsho et al 2007). The reason of ocular hypertension in these cases that was to blockage of the iridocorneal angle by lenticular remnants, soluble proteins, pigments and vitreous humor, trauma during the surgical procedure. It was breakdown of the blood aqueous barrier and the presence of inflammatory cells, presence of viscoelastic material, hemorrhage and synechiae (Smith et al 1996, Sigle and Nasisse 2006).

A great advantage of ultrasound is that it can be used to evaluate the internal structure of the eye. The knowledge of the dimensions of optical components is required to better understand many studies and clinical problems related to vision. Both A-mode and B-mode ultrasound have been used for ocular biometry (Paunksnis et al 2001). Ultrasonography is obligatory for a good selection of patients for cataract surgery because it offers valuable information especially of the posterior segment, which is not always visible by semiotic ophthalmic techniques.

The purpose of this research was to investigate the effects of IOP in extra capsular extraction (ECCE) and phacoemulsification methods with or without IOL on dogs with cataracts over a 28-day period. Ultrasonography was used to evaluate the condition of the lens and fundus of the eye with a cataract.

## Materials and Methods

### Animals

Twenty adult dogs of both sexes with cataracts, weighing between 10 to 30 kg and at different ages were used as materials. The study was carried out according to the criteria of the Ethical committee of Selcuk University. The dogs were randomly selected on the basis of on assessment of their general clinical condition with significance on hematimetric indexes and biochemical outline. Cataracts were diagnosed

by direct and indirect ophthalmoscopy, Schirmer tear test, ultrasonographic examination and, for in some cases (immature cataracts), biomicroscopy. Cataracts were classified as immature (7 animals), mature (7 animals), and hypermature (6 animals) (Figure 1) through clinical examination and ultrasonography. Dogs were divided into two groups each consisting of 10 animals. Ten dogs with cataract were operated on for ECCE and the other group of 10 dogs underwent a phacoemulsification (PHACO) procedure. In the two groups, 10 animals (5 for ECCE and 5 for PHACO) were used for 41 dioptre single-piece acrylic intraocular lens. One eye (left eye) of all dogs with cataracts was used as material during the research period.

### Ultrasonography examination

Ultrasonography was performed using ophthalmic examination B mode probes convex mechanical transducer of 7.5 MHz (Esaote Piemedikal, Model 410477) (Martins et al 2010) (Figure 2). The transducer was positioned to scan the entire globe. The lens was evaluated with respect to echogenicity. Alterations in the posterior segment were investigated and assessed. The lens of each eye was classified as having hyperechoic or hypoechoic areas. At the end of the examination, the eyes were rinsed with sterile 0.9% sodium chloride solution.

### Preoperative procedures

The preoperative procedures were started 24 hours before the surgery with topical administration of corticosteroids/antibiotics (0.1% Dexamethasone, Maxidex 0.1 mg 5 mL oft. sol/lomefloxacin, Okacin 3 mg 5 mL, Novartis) every 2 hours. Twenty-four hours before the treatment, daily therapy was initiated with (600 000 IU Penicillin G Procain flk 800.000) in IM. One hour before the surgery, sikloplegic/midriatic (Siklopentolat HCl, Sikloplejin 1%, Fenilefrin HCl, Mydrin® 2.5%) were instilled at 15 minute intervals the dogs were intravenously preanesthetized with xylazine hydrochloride (Alfazyne 2%) and ketamin hydrochloride (Alfamane 10%). After 10 minutes, anaesthesia was induced by isoflurane (AErrane, Baxter 2-4%).

### Extracapsular extraction (ECCE)

Extracapsular extraction techniques were followed by Gelatt and Gelatt (2001). The anterior chamber was entered with a blade (Figure 3). After cornea-scleral incision, the anterior chamber was then filled with Trypan blue to stain the anterior crystalline capsule (Figure 4). Two minutes after application of the dye and its contact with the anterior capsule of the lens, the remaining dye was removed by washing the anterior chamber with balanced salt solution (BSS®, Alcon Laboratories). The anterior chamber was then supplied with a viscoelastic substance of hydroxypropylmethylcellulose

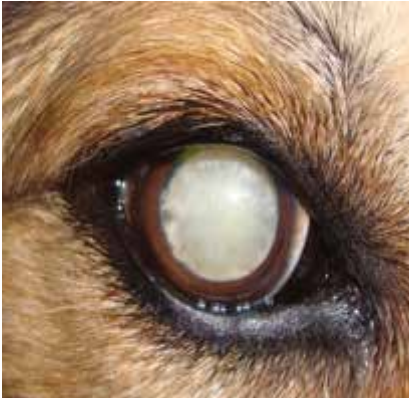

Figure 1. Cataracts were classified as immature, mature and hypermature through clinical examination and ultrasonography.

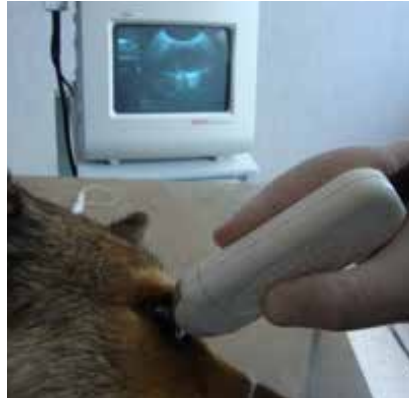

Figure 2. Ultrasonography was performed using ophthalmic examination B mode probes convex mechanical transducer of 7.5 MHz.

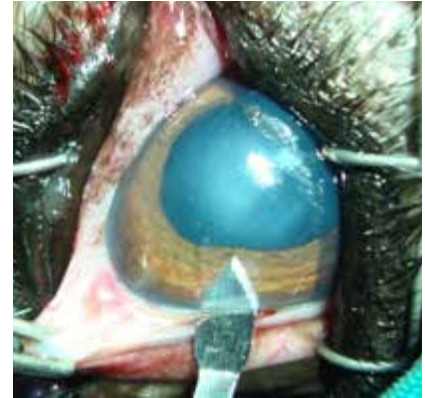


Figure 3. The anterior chamber was entered with a blade.

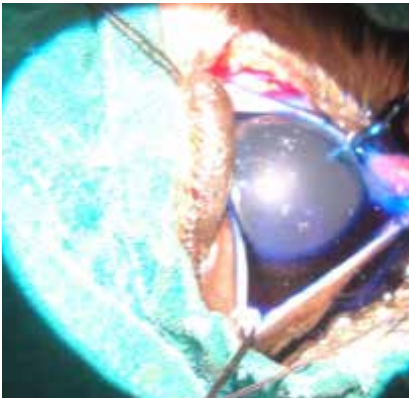


Figure 4. The anterior chamber was then filled with trypan blue to stain the anterior crystalline capsule.

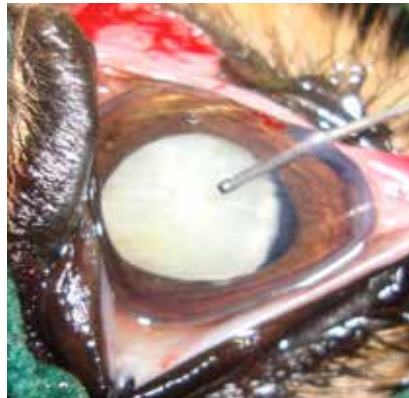

Figure 5. The anterior chamber was then filled with a viscoelastic substance of hydroxypropyl methylcellulose.

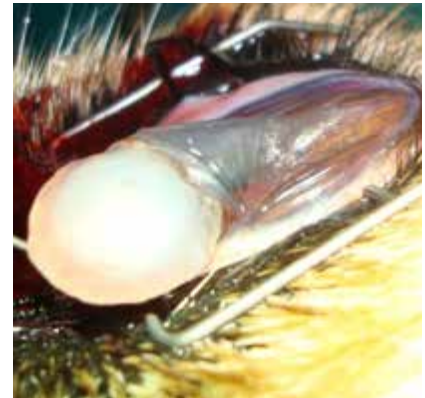

Figure 6. A wide incision was made in the limbus and the anterior lens capsule.

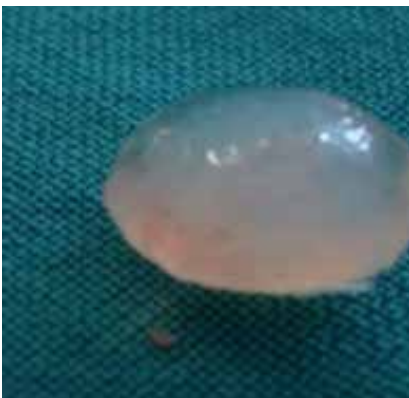

Figure 7. Nucleus and cortex were extracted manually.

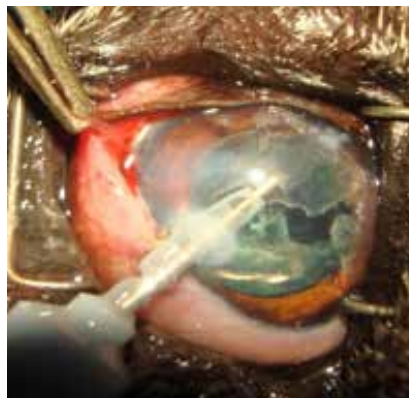


Figure 8. A phacofragmentation tip was introduced through the corneal incision via the anterior lens capsule.

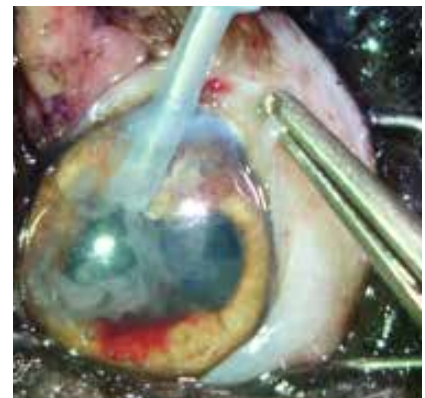

Figure 9. Irrigation and aspiration were used towards the end of the surgery to remove the remaining lens materials from the equatorial and posterior lens capsules.





(Crown gel 2.4%, Nanotech ophtalmic) (Figure 5). A continuous curvilinear capsulorhexis was done with forceps. The corneal incision was made large with corneal scissors. A wide incision was made in the limbus and the anterior lens capsule, nucleus and cortex were extracted manually (Figures 6 and 7), followed by flushing to remove any remaining lens particles. Corneal incision was closed with interrupted nylon 8/0 sutures (Surgicryl®, Polyglycolic Acid). Dexamethasone 0.1 mL was injected subconjunctivally. Topical administration of corticosteroids/antibiotics (0.1% Dexamethasone, Maxidex 0.1 mg 5 mL oft. sol /lomefloksasin, Okacin 3 mg 5 mL, Novartis) every 2 hours.

*Phacoemulsification technique*

After cornea-scleral insicion, the anterior chamber was then filled with Trypan blue to stain the anterior crystalline cap-

sule. Two minutes after application of the dye and its contact with the anterior capsule of the lens, the remaining dye was removed by washing the anterior chamber with balanced salt solution (BSS®, Alcon Laboratories). The anterior chamber volume was filled with viscoelastic material (hydroxypropylmethylcellulose (Crown gel 2.4%, Nanotech ophtalmic). Modified capsulorhexis penses were used to cut into the anterior lens capsule. Part of the anterior lens capsule was carefully torn and removed. A phacofragmentation tip (Alcon Universal USA S/N 1077 Alcon Surgical, INC, IRVINE, CA) was established through the corneal incision via the anterior lens capsule (Figure 8). Irrigation and aspiration systems were used assisting the end of the surgery to eliminate the remaining lens materials from the equatorial and posterior lens capsules (Figure 9). Corneal incision was closed with interrupted nylon 8/0 sutures (Surgicryl®, Polyglycolic Acid). The anterior chamber was filled with balanced salt solution.



Figure 10. Acrylic hydrophilic monomer (Lens Teco, Lenstec) optic IOL of 41 D was used.

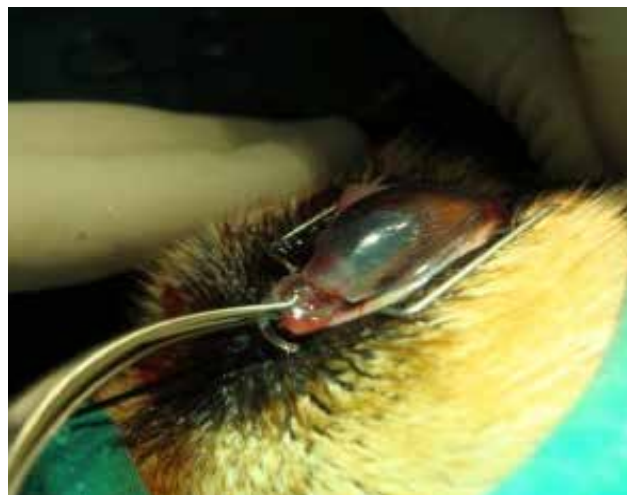

Figure 11. The IOL optic was holding by forceps and inserted into the IOL cartridge

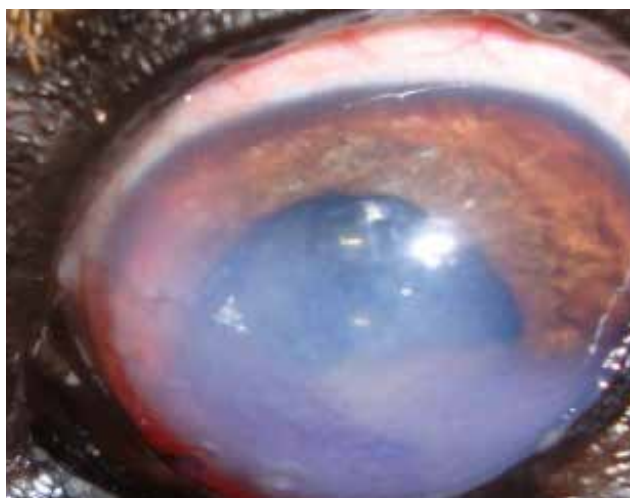


Figure 12. Eyes were examined postoperatively until at least 1 month after the surgery.

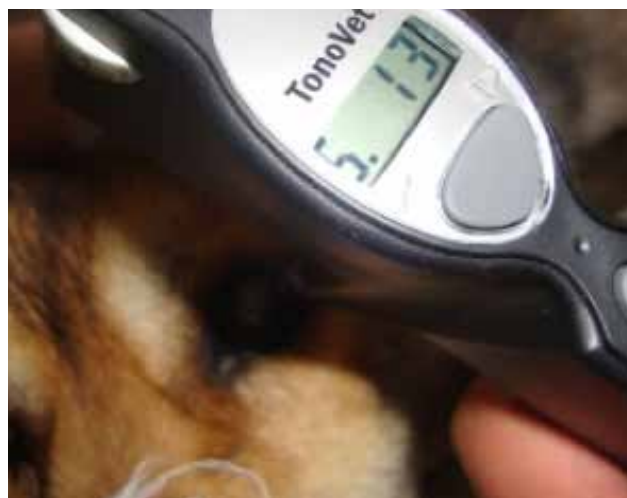

Figure 13. Preoperative and postoperative intraocular pressures were measured and recorded on the 7th, 14th, 21st and 28th days with a rebound tonometer.



Table 2. Intraocular pressure (IOP) of the dogs that underwent surgery according to the follow-up periods (mean±SD, Reference values 15-30 mmHg).

	Pre-operative	7. Day	14. Day	21. Day	28. Day
ECCE (-)	38.72±5.51 <sup>a</sup>	27.84±4.03 <sup>b</sup>	16.52±1.56 <sup>c</sup>	23.96±2.23 <sup>bc</sup>	21.08±1.72 <sup>bc</sup>
ECCE(+)	15.36±0.92 <sup>b</sup>	23.56±3.69 <sup>a</sup>	23.44±3.68 <sup>a</sup>	13.72±1.06 <sup>b</sup>	16.76±1.37 <sup>ab</sup>
PHACO (-)	26.76±1.87 <sup>a</sup>	12.20±1.30 <sup>bc</sup>	11.52±1.41 <sup>bc</sup>	9.28±0.87 <sup>c</sup>	14.32±1.33 <sup>b</sup>
PHACO(+)	29.12±3.95 <sup>a</sup>	18.52±1.90 <sup>b</sup>	17.56±1.65 <sup>b</sup>	18.80±1.47 <sup>b</sup>	17.76±1.57 <sup>b</sup>

ECCE (-); Extracapsular extraction without IOL; ECCE (+); Extracapsular extraction with IOL; PHACO (-) Phacoemulsification without IOL; PHACO (+) Phacoemulsification with IOL; The letters a, b, c in each row shows statistical significance ( $P < 0.05$ ).

Postoperatively, similar procedures such as ECCE were performed for PHACO group.

#### *Intraocular lenses (ILO)*

Acrylic hydrophilic monomer (Lens Teco, Lenstec) optic IOL of 41 D was used. The IOL optic was holding by forceps and placed into the IOL cartridge (Figure 10). After supplying the capsular bag and anterior chamber with a hydroxypropylmethylcellulose (Crown gel 2.4%, Nanotech ophtalmic), the IOL in the cartridge was put in the capsular bag with the IOL inserter without enlarging the corneal incision (Figure 11).

#### *Postoperative care*

Topical administration of antibiotics Okacin (Iomefloksasin, Okacin 3 mg 5 mL, Novartis) was performed every 2 hours for two weeks. Corticosteroids (0.1% Dexamethasone, Maxidex 0.1 mg 5 mL oft. sol) were administered every 3 hours for two weeks and afterwards daily used. Carprofen (Rimadyl®, Pfizer Co., Ltd) 2 mg/kg was orally given once dexamethasone had stopped. Medications and doses were changed based on intraocular complications. All dogs were instructed to wear Elizabethan collar at all times during the first 2 months to prevent self trauma. Eyes were examined postoperatively until at least 1 month after the surgery (Figure 12).

#### *Intraocular pressure*

Preoperative and postoperative intraocular pressures were measured and recorded on the 7th, 14th, 21st and 28th days with a rebound tonometer (TonoVet®, Figure 13). The correct results for intraocular pressure were measured for the animal standing positions. The following changing was compared for intraoperative complications, variations in IOP and photophobia and blepharospasm, conjunctival hyperemia, corneal oedema, aqueous humor transparency, and iridocyclitis for the surgical duration of each technique.

#### *Statistical analysis*

IBM SPSS 19 Pearson correlation test was used for the evaluation of postoperative vision after surgery was performed for

immature, mature and hypermature eyes. IOP values were compared between animals by replicated measures analysis of variance using IBM SPSS 19, one-way ANOVA and Duncan test. It should be noted that eyes were eliminated from the statistical analysis of the IOP changing since complications might interrupt with the results.

## **Results**

#### *Ultrasonography examination*

Hypermature cataract with resorption of the axial regions of the anterior cortex and of the nucleus was observed in 6 animals. The axial diameter of the eyes with immature and mature cataracts was smaller in size compared to hypermature cataracts. But, there were no statistically significant differences. On clinical examination, posterior and anterior capsular cataract was detected in the dog with hypermature cataract in both eyes. Nucleus and posterior capsule of lens was hyperechoic echogenicity. However, the posterior capsule was impossible given the degree of opacification of the lenses in the other animals. Different ultrasonography alterations were observed in the posterior segment in some cases. Hypoechoic echogenicity of lens was detected in dogs with mature and hypermature cataract. The biometric measurements were shown in Table 1.

#### *Operation results*

Photophobia and blepharospasm were detected in both eyes immediately after the surgery. However, these situations were more severe in eyes submitted to ECCE. Conjunctival hyperaemia was demonstrated in all eyes, moderate at the beginning and becoming severe by the second hour after surgery. Moderate to severe corneal oedema was observed in the eyes submitted to ECCE. In the eyes submitted to phacoemulsification, oedema was limited to region close to and above the suture lines. Ocular discomfort was observed in ECCE groups animals compared to those submitted to phacoemulsification.





### *Intraocular pressure*

ECCE without IOL applied group was showed statistical differences ( $P<0.05$ ) on the 7th and 14th days. Intraocular pressure was getting lower compared to the day 7th, 14th, 21st and 28th. But all the data were seen to be within normal values. The assessment regarding postoperative intraocular pressure was higher on the 7th and 14th days compared to the 21st day. But all the data were seen to be between normal values. PHACO without IOL group also showed statistical differences on the 21st day, they were seen within normal values. PHACO with IOL applied group showed statistical differences in the range from 0 to the 7th, 14th, 21st and 28th days ( $P<0.05$ ). The results were also seen within normal values for this group in Table 2.

### **Discussion**

The present study shows that there are a lot of advantages of phacoemulsification (Chahory et al 2003), such as short continuance of surgery, a low risk of vitreous loss, conservation of the IOP during surgery and less extreme iridocyclitis, in addition to a smaller incision and smaller scar attended by greater corneal transparency and less astigmatism as supported by previous studies (Lannek and Miller 2001, Sigle and Nasisse 2006, Yi et al 2006). In addition, during the surgery, corneal oedema, posterior capsule rupture and corneal thermal injuries were also observed.

In the study, IOP measurements were seen reference values for ECCE and PHACO with or without IOL groups. Hypermature cataract cases showed a positive correlation with established anterior chamber depth, posterior lens surface to retina and a higher IOP. It is reported that IOP is known to stay on elevated during the first 24 hours after surgery, especially in eyes submitted to phacoemulsification (Smith et al 1996, Lannek and Miller 2001, Sigle and Nasisse 2006, Yi et al 2006). Small incisions and highly viscous composition contribute to the incident of postoperative ocular hypertension. Small incisions supported better cooptation of the surgical wound but ruined drainage of the viscoelastic agents, contributing to the happening of ocular hypertension as supported by Chahory et al (2003). Decreased drainage of the aqueous humor due to mechanical obstruction of the drainage corner with lenticular remnants, plasma proteins and inflammatory cells, as well as narrowing of the trabecular network as a result of oedema, favour an increase in IOP. Yi et al (2006) showed that in the presence of intraocular inflammation, the IOP demonstrates to decrease after some hours. In the present study, IOP started to be measured 7 days after the surgery and pressure was within reference levels for PHACO and ECCE groups. It is also in support of the result of previous studies where IOP was getting normal values within 24 hours after surgery (Miller et al 1997, Gaiddon et al 2000).

In the present study, ultrasonography examination showed the differences in lens thickness in some stages of cataract. Axial thickness of lenses with immature and mature cataracts was also demonstrated. Previous studies showed that while mature cataracts and hypermature cataracts increase in size through intumescences, immature cataracts could be decrease in thickness owing to loss of soluble lens material from the lens capsule (Hamidzada and Osuobeni 1999, Paunksnis et al 2001, Williams 2004). Biometry of the globe is normally assumed with a mode ultrasonography to concluded axial length prior to intraocular lens implantation. It has been reported that A-mode and B-mode ultrasonography to give axial measurements were not statistically significantly contrary and thus B-mode ultrasonography can be as accurate as A-mode biometry (Hamidzada and Osuobeni 1999, Paunksnis et al 2001, Martins et al 2010). In this study, B-mode ultrasonography was used. Lens thickness expands with age, a feature noted in previous reports in humans and in the dog. In the present study, thickness of lens with age was not compared because there were not enough cases for statistical analysis. But, this finding was repeated in several studies and it was shown that lens thickness in each group increased with age. On the other hand, the finding of decreased anterior chamber depth in eyes with immature cataract suggests that narrow iridocorneal angle could be result in to increased intraocular pressure (Van der Woerd et al 1993).

### **Conclusions**

Both surgeries could be used for cataract cases in terms of IOP effects. Selection of the patient, correct surgical technique, adequate equipment was important for the success of a surgery. But, it was also concluded that success of phaco-fragmentation surgery increased when the animals were in immature stages. There was a possibility of faster postoperative rehabilitation of patients with minimal intraoperative damage of ocular tissues with foldable materials. Thus, ultrasonographic examination was always very helpful to support postoperative term.

### **Acknowledgments**

We would like to thank for financial support by University of Selcuk (Scientific Research Projects (BAP) (Project No. 084001073).

### **References**

- Chahory S, Clerc B, Guez J, Sanaa M, 2003. Intraocular pressure development after cataract surgery: a prospective study in 50 dogs (1998-2000). *Vet Ophthalmol*, 6, 105-112.
- Gaiddon J, Lallement PE, Peiffer RL Jr, 2000. Implantation of a foldable intraocular lens in dogs. *JAVMA*, 216, 875-877.
- Gelatt KN, Gelatt, JP, 2001. Surgical procedures of the lens





- and cataracts. In: Gelatt KN, Gelatt JP (eds.). *Small Animal Ophthalmic Surgery: Practical Techniques for the Veterinarian*, Butterworth-Heinemann, Oxford, UK, pp: 286-334.
- Hamidzada WA, Osuobeni EP, 1999. Agreement between A-mode and B-mode ultrasonography in the measurement of ocular distances. *Vet Radiol Ultrasound*, 40, 52-57.
- Honsho CS, Oria AP, Pigatto JAT, Laus JL, 2007. Modified extracapsular extraction versus endocapsular phacoemulsification: Intraoperative and immediate postoperative events. *Braz J Vet Res Anim*, 59, 105-113.
- Kecova H, Necas A, 2004. Phacoemulsification and intraocular lens implantation: Recent trends in cataract surgery. *Acta Vet Brno*, 73, 85-92.
- Lannek EB, Miler, PE, 2001. Development of glaucoma after phacoemulsification for removal of cataracts in dogs: 22 cases (1987-1997). *JAVMA*, 218, 70-76.
- Martins BC, Rodrigues Jr EF, Souza ALG, Almeida DE, Brito FLC, Canola JC, Laus DBJL, 2010. A and B mode ultrasonography in preoperative evaluation of lens and posterior segment of dogs eyes with cataract. *Pesquisa Vet Brasil*, 30, 121-126.
- Miller PE, Stanz KM, Dubielzig RR, Murphy CJ, 1997. Mechanisms of acute intraocular pressure increases after phacoemulsification lens extraction in dogs. *Am J Vet Res*, 5, 1159-1165.
- Paunksnis A, Svaideniene E, Paunksniene M, Babrauskiene V, 2001. Ultrasonographic evaluation of the eye parameters in dogs of different age. *Ultragarsas*, 2, 39.
- Sigle KJ, Nasisse MP, 2006. Long-term complications after phacoemulsification for cataract removal in dogs: 172 cases (1995-2002). *JAVMA*, 2006, 228, 74-79.
- Smith PJ, Brooks DE, Lazarus JA, Kubilis PS, Gelatt KN, 1996. Ocular Hypertension following cataract surgery in dogs: 139 cases (1992-1993) *JAVMA*, 209, 105-111.
- Van der Woerd A, Wilkie DA, Myer CW, 1993. Ultrasonographic abnormalities in the eyes of dogs with cataracts: 147 cases (1986-1992). *JAVMA*, 15: 838-841.
- Williams DL, 2004. Lens morphometry determined by B-mode ultrasonography of the normal and cataractous canine lens. *Vet Ophthalmol*, 7, 91-95.
- Yi NY, Park SA, Jeong MB, Kim WT, Kim SE, Chae JM, Seo KM, 2006. Phacoemulsification and acryl foldable intraocular lens implantation in dogs: 32 cases. *J Vet Med Sci*, 7, 281-285.

