



## RESEARCH ARTICLE

### Protective effects of vitamin E in experimentally induced rhabdomyolysis

Javad Tajik<sup>1\*</sup>, Reza Kheirandish<sup>2</sup>, Hamideh Rohani<sup>1</sup>, Shima Abbasi<sup>1</sup>

<sup>1</sup>Department of Clinical Studies, <sup>2</sup>Department of Pathobiology, School of Veterinary Medicine, Shahid Bahonar University of Kerman, Kerman, Iran

Received: 07.07.2013, Accepted: 05.09.2013

\*tajik@uk.ac.ir

#### Özet

**Tajik J, Kheirandish R, Rohani H, Abbasi S.** Deneysel rabdomiyolizde vitamin E'nin koruyucu etkileri. *Eurasian J Vet Sci*, 2013, 29, 4, 180-184

**Amaç:** Ratlarda deneysel olarak oluşturulan rabdomiyoliz olgularında vitamin E uygulamasının koruyucu etkilerini değerlendirmektir.

**Gereç ve Yöntem:** Yirmi bir adet rat üç eşit gruba ayrıldı: kontrol (Grup 1), gliserol (%50 gliserol, 7 mL/kg, IM) ve gliserol (%50 gliserol, 7 mL/kg, IM) + vitamin E grup (100 mg/kg, IP, SID). Gliserol uygulamasından doksan altı saat sonra kan örnekleri alındı. Serumdan kreatinin, kan üre nitrojen, kreatin kinaz, aspartat aminotransferaz, alanin aminotransferaz ve laktat dehidrogenaz düzeyleri ölçüldü. Karaciğer ve böbrek dokusunun histopatolojik incelemesi yapıldı

**Bulgular:** Gliserol + vitamin E grubu kreatinin, laktat dehidrogenaz ve kreatin kinaz düzeyleri gliserol grubundan düşük ( $p<0.05$ ) belirlendi. Vitamin E uygulamasının gliserolün neden olduğu renal tübuler hasarı azalttığı tespit edildi.

**Öneriler:** Vitamin E uygulamasının rabdomiyoliz vakalarında gözlenen renal ve kas hasarını azaltabileceği ifade edilebilir.

**Anahtar kelimeler:** Vitamin E, böbrek hasarı, rabdomiyoliz

#### Abstract

**Tajik J, Kheirandish R, Rohani H, Abbasi S.** Protective effects of vitamin E in experimentally induced rhabdomyolysis. *Eurasian J Vet Sci*, 2013, 29, 4, 180-184

**Aim:** Evaluation of the protective effects of vitamin E administration in a rat model of rhabdomyolysis.

**Material and Method:** Twenty one rats were divided to three equal groups; control (Group 1), glycerol (50% glycerol, 7 mL/kg, IM) and glycerol (50% glycerol, 7 mL/kg, IM) + Vitamin E (100 mg/kg, IP, SID). Ninety-six hours after glycerol injection, blood samples were collected. Serum creatinine, blood urea nitrogen, creatine kinase, aspartate aminotransferase, alanine aminotransferase and lactate dehydrogenase levels were measured. Histopathologic pattern of hepatic and renal tissue damages was also evaluated.

**Results:** Glycerol + vitamin E groups had lower ( $P<0.05$ ) creatinine, lactate dehydrogenase and creatine kinase levels than the glycerol group, and the administration of vitamin E caused lesser renal tubular damages in glycerol + vitamin E group rather than in glycerol group.

**Conclusions:** Vitamin E administration may decrease the muscle injury and renal damage in rhabdomyolysis cases.

**Keywords:** Vitamin E, renal damages, rhabdomyolysis





## Introduction

Rhabdomyolysis occurs both human and animals. Disease is associated with widespread muscle injury accompanied by the release of myoglobin (Mb) into the circulation. Hence, released Mg may cause secondary renal failure. Rhabdomyolysis may occur due to different causes, such as trauma, malignant hyperthermia, seizures, muscle ischemia, drug overdose, intense exercise, heat stroke, metabolic disorders and genetic disorders. It is estimated that renal failure occurs in 30% of human rhabdomyolysis cases, which in about 5% of these cases result in death. Rhabdomyolysis has been introduced as the cause of 7% of human acute renal failure cases (Moore et al 1998, Boutaud and Roberts 2011). Renal vasoconstriction, tubular obstruction and necrosis due to direct heme protein-induced cytotoxicity have been introduced as the main pathophysiologic mechanisms of rhabdomyolysis-associated renal damages (Boutaud et al 2010). Deposition of the released Mb in the kidney and generates free radicals, which play an important role in the rhabdomyolysis-associated renal damages and cause renal tubular cells injury via lipid peroxidation (Boutaud and Roberts 2011). Lipid peroxidation also produces very potent renal vasoconstrictors, which have been proposed as the main cause of renal vasoconstriction during myoglobinuria (Moore et al 1998). Additionally, following rhabdomyolysis induction, hepatic dysfunction and hepatic tissue damage due to oxidative injuries have been reported (Coelho et al 1996).

Although, a relationship between rhabdomyolysis occurrence and vitamin E deficiency has not yet been found (Kirschvink et al 2007), there is numerous *in vivo* and *in vitro* evidence regarding the critical role of oxygen and non-oxygen-based free radicals in renal and extrarenal injuries in rhabdomyolysis affected cases (Zager 1996). On the other hand, it has been shown that inhibitors of lipid peroxidation decrease rhabdomyolysis-induced renal injuries (Nath et al 1995). It is generally accepted that vitamin E act as an efficient inhibitor of lipid peroxidation (Burton and Ingold 1981) and protective effects of vitamin E in various types of injuries involving oxidative stress have been shown (Brigelius-Flohe and Traber 1999). However, there is little information regarding the evaluation of the probable protective effects of vitamin E in rhabdomyolysis cases.

This study was undertaken to investigate the protective effects of vitamin E administration in the rat model of rhabdomyolysis

## Materials and Methods

Twenty one male Sprague–Dawley rats (180–200 g) were acclimatized to the animal room condition 14 days before the beginning of the experiment. The rats were kept under constant conditions of temperature (25–27°C), relative humidity (20–30%), and a 12-h light/dark cycle. There was free access to food (standard laboratory rodent pellet diet, Razi, Iran) and water. The experiment was approved (1391-M-21) by School of Veterinary Medicine, Shahid Bahonar University of Kerman. The animals were randomly divided into 3 groups as follows: control (n:7, saline solution, 7 mL/kg, IM), glycerol (Gly, n:7, 50% glycerol 7 mL/kg, IM) and glycerol (Gly, n:7, 50% glycerol 7 mL/kg, IM, Shiminab Chemical, Iran) + vitamin E (Vit E, n:7, 100 mg/kg, IP, OSVAH Pharmaceutical, Iran). Experimental rhabdomyolysis was induced by a single intramuscular injection of 50% glycerol (7 mL/kg) divided into both lower hind limbs (Homsy et al 2010). Ninety-six hours after glycerol injection, the animals were sacrificed using ether anesthesia. Blood samples (2–3 mL) were collected by heart puncture. Subsequently, the right kidney and right lobe of liver were removed.

After blood serum was separated, serum biochemical analysis was done for measuring creatinine concentrations with the modified Jaffe method, blood urea nitrogen (BUN) by diacetyl monoxime method (Burtis and Ashwood 1994), aspartate aminotransferase (AST) and alanine aminotransferase (ALT) activities by the modified method of Reitman and Frankel, lactate dehydrogenase (LDH) activity by the Sigma colorimetric (Cabaud Wroblewski) method and creatine kinase (CK) by the Sigma colorimetric method (modified by Hughes) (Thrall et al 2004).

The tissue samples were fixed in 10% neutral formalin, embedded in paraffin, cut at 5 µm, and stained with hematoxylin and eosin (H&E). Renal tubular damages were classified as one of five types using the grading criteria described by Wei et al (2011). Tubular injury was indicated by necrotic lysis, tubular dilation, cast formation, and sloughing of cellular

Table 1. The serum concentrations (mean ± SEM) of blood urea nitrogen (BUN), creatinine, aspartate aminotransferase (AST), alanine aminotransferase (ALT), creatine phosphokinase (CK) and lactate dehydrogenase (LDH) in different groups.

Group	BUN (mg/dL)	Creatinine (mg/dL)	AST (U/L)	ALP (U/L)	CK (U/L)	LDH (U/L)
Control	71.1±6.57	0.72±0.02 <sup>a</sup>	220±29.5	140±14.5	676±80.1 <sup>a</sup>	865±257 <sup>a</sup>
Glycerol	97.2±12.9	0.91±0.05 <sup>b</sup>	254±24.4	154±9.77	1190±163 <sup>b</sup>	1681±184 <sup>b</sup>
Gly+Vit E	74.8±7.80	1.00±0.22 <sup>b</sup>	225±14.5	143±7.20	1084±73.0 <sup>a</sup>	1065±98.3 <sup>a</sup>

Gly; glycerol, Vit E; vitamin E, <sup>a, b</sup> Different letters in the same column are statistically significant (P<0.05).



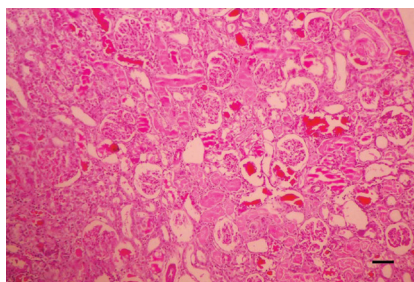


Figure 1. Glycerol group. Severe tubular degeneration and necrosis (arrows) with hyaline cast formation (open arrows) (H&E, 100  $\mu$ m).

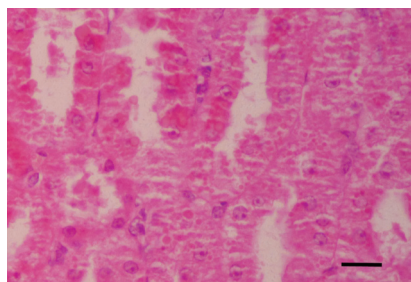


Figure 2. Glycerol group. Presence of fine eosinophilic granules (arrows) in the cytoplasm of tubular epithelial cells (H&E, 25  $\mu$ m).

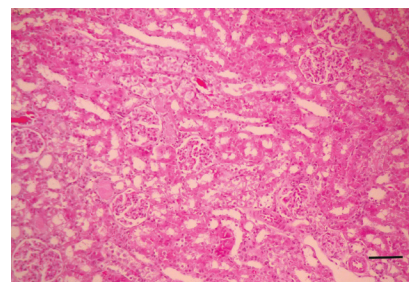


Figure 3. Glycerol + Vitamin E group. Mild tubular degeneration and minimum of hyaline cast (arrows) are seen (H&E, 100  $\mu$ m).

debris into the tubular lumen. Briefly, tubular injury score was indicated by the percentage of renal tubule injury: 0: no damage, 1: < 10%, 2: 11-25%, 3: 25-50%, 4: 50-75%, and 5: >75%.

Study data were evaluated by ANOVA and Bonferroni, a posthoc test. Values of Gly group were tested with Pearson correlation test (SPSS.12, Illinois, Chicago, USA). Differences were considered significant at  $P \leq 0.05$ .

## Results

The results of the measured serum factors in different groups are shown in Table 1. Serum creatinine in control group was significantly lower ( $P < 0.05$ ) than in Gly and Gly+Vit E groups. Gly+Vit E group had lower ( $P < 0.05$ ) serum CK and LDH than the Gly group.

No change was found in histopathologic evaluation of liver in any of the groups. Histopathologic evaluation of kidney revealed also no change in control group. In Gly group, typical

myoglobinuric nephrosis was evident in 50-100% of renal tubules in different cases, and included tubular degeneration and necrosis (especially in proximal convoluted tubules), tubular dilation, hyaline cast formation, sloughing of necrotic epithelial cells into tubular lumen and presence of fine eosinophilic granules in the cytoplasm of tubular epithelial cells (Figures 1 and 2). Hyaline casts were more often observed in renal medulla than cortex. In the Gly+Vit E group, the severity of renal tissue damage was relatively decreased and 10-50% of tubules were affected in different cases (Figure 3). In this group, a small amount of hyaline casts was evident and renal Mb deposition was lesser in comparison to Gly group. Comparison of tubular injury scores revealed that the Gly+Vit E group had lower ( $P < 0.05$ ) tissue damage than the Gly group.

Correlation between GLY and Gly-Vit E groups are presented in Table 2. Pearson correlation test showed significant relationships between serum concentrations of AST, ALP, LDH and CK in glycerol-treated rats. However, serum concentrations of these enzymes, BUN and creatinine showed no significant correlation with renal damage score.

Table 2. The correlations between serum concentrations of blood urea nitrogen (BUN), creatinine, aspartate aminotransferase (AST), alanine aminotransferase (ALT), creatine phosphokinase (CK), lactate dehydrogenase (LDH) and renal damage score in glycerol-treated

Values	KDS	LDH	CK	ALP	AST	Creatinine
BUN	$r = -0.313$ $P > 0.05$	$r = -0.084$ $P > 0.05$	$r = -0.101$ $P > 0.05$	$r = 0.056$ $P > 0.05$	$r = 0.171$ $P > 0.05$	$r = 0.957^*$ $P < 0.01$
Creatinine	$r = -0.353$ $P > 0.05$	$r = -0.144$ $P > 0.05$	$r = -0.131$ $P > 0.05$	$r = -0.131$ $P > 0.05$	$r = 0.041$ $P > 0.05$	
AST	$r = 0.306$ $P > 0.05$	$r = 0.676^*$ $P < 0.01$	$r = 0.794^*$ $P < 0.01$	$r = 0.914^{**}$ $P < 0.01$		
ALP	$r = 0.393$ $P > 0.05$	$r = 0.560^*$ $P = 0.037$	$r = 0.618^*$ $P = 0.018$			
CPK	$r = 0.485$ $P > 0.05$	$r = 0.908^*$ $P < 0.01$				
LDH	$r = 0.484$ $P > 0.05$					

KDS: Kidney damage score, \*, Significant correlation.





## Discussion

Study results showed that rhabdomyolysis caused the expected rise in serum creatinine and BUN (Table 1), which confirm the occurrence of relative renal failure due to rhabdomyolysis induction. Histopathologic evaluation also confirmed the occurrence of rhabdomyolysis induced renal damages (Figure 1 and 2). After lysis of myocytes, a large amount of Mb is released into blood circulation. The released Mb deposits in the kidney and causes renal damage. Renal vasoconstriction, tubular obstruction by Mb casts and tubular cell necrosis due to direct heme protein-induced cytotoxicity have been proposed as the main pathophysiologic mechanisms of rhabdomyolysis-associated renal damages (Boutaud et al 2010). Recent studies have revealed the causative role of Mb-mediated oxidative injury in renal pathogenesis during rhabdomyolysis. It has been suggested that the Mb deposited in the kidney catalyze the lipid peroxidation, which is responsible for rhabdomyolysis-associated renal oxidative injuries (Moore et al 1998, Boutaud and Roberts 2011). Additionally, the role of reactive oxygen species and hydroxyl radical in renal tubular damage has been proven (Zager 1996). On the other hand, it has been shown that renal lipid peroxidation during myoglobinuria produces very potent renal vasoconstrictors that has been proposed as the main cause for the intense renal vasoconstriction that occurs in myoglobinuria (Moore et al 1998). Lipid peroxidation can cause both renal cells oxidative injury and renal vasoconstriction, as a result, it could be expected that antioxidants, especially with lipid solubility, decrease renal injuries in rhabdomyolysis cases.

Vitamin E is a strong, lipid-soluble and chain-breaking antioxidant agent. Numerous *in vivo* and *in vitro* studies demonstrated the effects of vitamin E in prevention of damages in free radicals related diseases (Brigelius-Flohe and Traber 1999). It has been shown that vitamin E prevents mitochondrial dysfunction during oxidative stress, and is a potent inhibitor of lipid peroxidation (Hafeman and Hoekstra 1977, Brigelius-Flohe and Traber 1999). According to this study results, administration of vitamin E decreased the rhabdomyolysis induced renal damages (Figure 3) and partially improved renal dysfunction, which may be partially due to its preventive effects on lipid peroxidation in kidney. Vitamin E is the major lipid soluble antioxidant and presents in all cellular membranes. It is believed that presence of antioxidants in cellular membrane facilitates the inactivation of extracellular free radicals (Machlin and Bendich 1987). As a result, vitamin E can effectively protect tubular cells from oxidative damage induced by intratubular released Mb. In addition to its role as an oxygen radical scavenger, vitamin E complements glutathione function, and protects cellular lipids, DNA and proteins from oxidative damage (Brigelius-Flohe and Traber 1999). It has been shown that manipulations in renal glutathione status altered the rhabdomyolysis-associated renal damages (Zager 1996). Additionally, vitamin E administration causes concomitant vasodilatation and lipid per-

oxidation reduction (Machlin and Bendich 1987, Brigelius-Flohe and Traber 1999).

On the other hand, administration of vitamin E in rhabdomyolysis cases seems to cause a decrement in muscles injury, which caused lesser serum concentrations of serum CK and LDH, and renal Mb deposition in the Gly-Vit E group in comparison to the Gly group. Similar to this study results, Zurovsky and Grossman (1992) reported that although preventive treatment of vitamin E in glycerol-induced rhabdomyolysis in rats did not affect survival rate, decreased the muscular injuries. Free radicals produced as a result of muscular cell damage and later by migrated leukocytes can cause additional damage to the muscular cells (Odeh 1991, O'Connor and Deuster 2007). Administration of antioxidant, such as vitamin E in rhabdomyolysis cases seems to prevent increasing production of free radicals during muscular damage. Decrement in rhabdomyolysis severity due to vitamin E supplementation has been reported by some practitioners (Valberg 2005). On the other hand, a decreasing muscular damage causes lesser Mb release into blood circulation, fewer renal Mb depositions, and less renal damage.

Blood urea nitrogen and creatinine are used routinely as the indicators of renal damage and renal failure (Haschek et al 2009), however, the current study showed that serum concentrations of BUN and creatinine have no relationship with the severity of renal damages in rhabdomyolysis cases (Table 2). As a result, serum BUN and creatinine seems not to be good indicators for evaluation of renal damage in rhabdomyolysis cases.

Histopathologic evaluation of liver revealed no change due to rhabdomyolysis induction in Gly and Gly+Vit E groups. However, Coelho et al (1996) reported periportal necrosis and centrilobular degeneration due to rhabdomyolysis induction in rats. It is believed that Mb-related lipid peroxidation and cytotoxicity are contributed to hepatic pathogenesis during rhabdomyolysis, and oxidative stress has key role at its pathogenesis (Coelho et al 1996).

## Conclusions

Although no specific therapy in patients suffering from myoglobinuria is available, the results of the current study revealed that vitamin E administration in rhabdomyolysis cases may decrease the muscular and renal injuries and improve renal function. However, more sophisticated work is required on a larger number of animals from different species before the importance of these findings can be assessed.

## References

- Boutaud O, Moore KP, Reeder BJ, Harry D, Howie AJ, Wang S, Carney CK, Masterson TS, Amin T, Wright DW, Wilson MT, Oates JA, Roberts LJ, 2010. Acetaminophen inhibits



- hemoprotein-catalyzed lipid peroxidation and attenuates rhabdomyolysis-induced renal failure. *Proc Natl Acad Sci USA*, 107, 2699-2704
- Boutaud O, Roberts LJ, 2011. Mechanism-based therapeutic approaches to rhabdomyolysis-induced renal failure. *Free Radic Biol Med*, 51, 1062-1067.
- Brigelius-Flohe R, Traber MG, 1999. Vitamin E: function and metabolism. *FASEB J*, 13, 1145-1155.
- Burtis CA, Ashwood ER, 1994. *Tietz Textbook of Clinical Chemistry*, 2nd edition, W. B. Saunders, Philadelphia, USA, pp: 561-834, 1002-1093.
- Burton GW, Ingold KU, 1981. Autoxidation of biological molecules. 1. The antioxidant activity of vitamin E and related chain-breaking phenolic antioxidants in vitro. *J Am Chem Soc*, 103, 6472-6477.
- Coelho AM, Machado MC, Masuda Z, de Cleve MR, Abdo EE, Carvalho ME, Pinotti HW, 1996. Hepatic dysfunction in myoglobinuria acute renal failure (rhabdomyolysis): Experimental study in rats. *Rev Hosp Clin*, 51, 228-231.
- Hafeman DG, Hoekstra WG, 1977. Protection against carbon tetrachloride-induced lipid peroxidation in the rat by dietary vitamin E, selenium, and methionine as measured by ethane evolution. *J Nutr*, 107, 656-665.
- Haschek WM, Rousseaux CG, Wallig MA, 2009. *Fundamentals of Toxicologic Pathology*, Second edition, Academic press, San Diego, USA, p: 56.
- Homs E, de Brito SM, Janino P, 2010. Silymarin exacerbates p53-mediated tubular apoptosis in glycerol-induced acute kidney injury in rats. *Ren Fail*, 32, 623-632.
- Kirschvink N, de Moffarts B, Lekeux P, 2008. The oxidant/antioxidant equilibrium in horses. *Vet J*, 177, 178-191.
- Machlin LJ, Bendich A, 1987. Free radical tissue damage: Protective role of antioxidant nutrients. *Fed Am Soc Exp Biol J*, 1, 441-445.
- Moore KP, Holt SG, Patel RP, Svistunenko DA, Zackert WE, Godier D, Reeder BJ, Clozel M, Anand R, Cooper CE, Morrow JD, Wilson MT, Darley-Usmar V, Roberts LJ, 1998. A causative role for redox cycling of myoglobin and its inhibition by alkalization in the pathogenesis and treatment of rhabdomyolysis-induced renal failure. *J Biol Chem*, 273, 31731-31737.
- Nath KA, Balla J, Croatt AJ, Vercellotti GM, 1995. Heme protein-mediated renal injury: A protective role for 21-aminosteroids in vitro and in vivo. *Kidney Int*, 47, 592-602.
- O'Connor FG, Deuster PA, 2007. Rhabdomyolysis. In: *Cecil Medicine*, Eds; Goldman L, Ausiello D, Twenty third edition, Saunders Elsevier, Philadelphia, USA, pp: 798-803.
- Odeh M, 1991. The role of reperfusion-induced injury in the pathogenesis of the crush syndrome. *N Engl J Med*, 324, 1417-1422.
- Thrall M, Baker AD, Lassen E, Campbell DT, Denicola D, Fettman M, Alan R, Weiser G, 2004. *Veterinary Hematology and Clinical Chemistry*, Ed: Thrall MA, Lippincott Williams and Wilkins, Philadelphia, USA, pp: 355-377.
- Valberg SJ, Geor RJ, Pagan JD, 2005. Muscle disorders: Untying the knots through nutrition. In: *Advances in Equine Nutrition III*, Pagan JD, Geor RJ, Nottingham University Press, Nottingham, UK, pp: 473-483.
- Wei Q, Hill WD, Su Y, Huang S, Dong Z, 2011. Heme oxygenase-1 induction contributes to renoprotection by G-CSF during rhabdomyolysis-associated acute kidney injury. *Am J Physiol Renal Physiol*, 301, 162-170.
- Zager RA, 1996. Rhabdomyolysis and myohemoglobinuric acute renal failure. *Kidney Int*, 49, 314-326.
- Zurovsky Y, Grossman S, 1992. Evidence against oxidant injury and endotoxin underlying fatal glycerol-induced rhabdomyolysis in rats. *J Basic Clin Physiol Pharmacol*, 3, 239-251.

