

VINCULA TENDINEUM AND VASCULARISATION OF THE FLEXOR POLLICIS LONGUS TENDON

(Received 10 March, 1994)

A. Yalın, Ph.D. / S. Çavdar, Ph.D.* / S. Arbak, Ph.D.*****

* Associate Professor, Department of Anatomy, Faculty of Medicine, Marmara University, Istanbul, Turkey.

** Assistant Professor, Department of Anatomy, Faculty of Medicine, Marmara University, Istanbul, Turkey.

*** Assistant Professor, Department of Histology and Embryology, Faculty of Medicine, Marmara University, Istanbul, Turkey.

SUMMARY

In the present study, the vascularization of flexor pollicis longus tendon of the thumb was investigated.

As a result, the long flexor tendon was supplied by two major sources. Primarily by extrinsic blood vessels which were converged to the tendon via vinculum longum and breve from its dorsal surface. Secondly, by small intrinsic vessels which entered the tendon through the muscular tendinous end and coursed parallel to the collagenous bundles of the tendon.

The vinculum longum was present in 38% of specimens observed whereas the vinculum breve existed in all cases.

Key Words: Morphological, Vascularization, Flexor, Tendon, Study

INTRODUCTION

The blood supply to the tendon of flexor pollicis longus muscle is controversial. The vinculum longum and breve are specialized types of mesotendineum in the synovial space. They provide vascular supply to the long tendons of digits. Although numerous studies have demonstrated the vascular supply of the long tendons of the fingers, (1-4) few of them investigated the blood supply of the flexor pollicis longus tendon (2).

In this study, the morphology of the long flexor tendon was carried out because of its clinical importance in hand surgery and physical therapy (5,6).

MATERIALS AND METHODS

In this study, 12 male and 6 female cadavers were used at the Marmara University, Faculty of Medicine, Department of Anatomy. Thirty-six flexor pollicis longus tendons were dissected. Morphometric measurements were taken by using a compass. Tendon specimens from the below regions were investigated light microscopically.

- 1) From proximal part of vinculum longum;
- 2) At the level of vinculum longum;
- 3) Between the vinculum longum and breve,
- 4) At the level of vinculum breve;
- 5) From the distal part of vinculum breve.

Then tissue specimens were fixed in 10% formalin

solution. The sections from paraffin blocks (4-5 um) were stained with Haematoxylin-Eosin dye. Then, they were investigated at Olympus BH-12 light microscope.

RESULTS

The results of the macroscopic and microscopic observations are as follows;

Two types of vincular systems were encountered;

A- Vinculum longum (VL) and B- Vinculum breve (VB)

A- VL belonging to flexor pollicis longus were found in 14 of 36 cases (38,8%). Its approximate length was 10 to 19 mm.

An extremely large vinculum longum was observed in 2 cases (5,5%) (Fig.1).

B- Vinculum breve belonging to flexor pollicis longus were present in all specimens (Fig.2), but at 2 cases (5.5%) distal part of vinculum breve was absent (Fig.3). While VL and VB were continuous in one case (2.7%) (Fig.4), fenestrated structure of VB was observed in a single case (2.7%) (Fig.5).

Following morphometric measurements performed in 35 of 36 cadavers (except in one whom vinculum breve and vinculum longum are interconnected), the height of VB was found to range between 6 to 11 mm and the basement length ranged between 16 to 21 mm.

Histological findings are the following:

- 1- At the section taken from the proximal part of VL, intrinsic vessels were observed in the connective tissue between the collagen bundles of the tendon. They usually run parallel to the collagenous fibers (Fig.6).
- 2- At the section taken from the level of VL, extrinsic vessels within the vinculum longum reaching the tendon entered through its dorsal surface and were spread out between the collagen bundles. Additionally, small intrinsic vessels were observed between the collagenous bundles. (Fig.7).
- 3- At the section between VL and VB, small intrinsic vessels run in the connective tissue between the collagenous bundles of the tendon (Fig.8).
- 4- At the section from the level of vinculum breve, together with numerous extrinsic vessels entering the tendon from its dorsal surface, intrinsic vessels with a parallel arrangement to the collagenous bundles were noticed (Fig.9).
- 5- At the distal part of vinculum breve, intense network of extrinsic vessels entered the tendon (Fig.10).

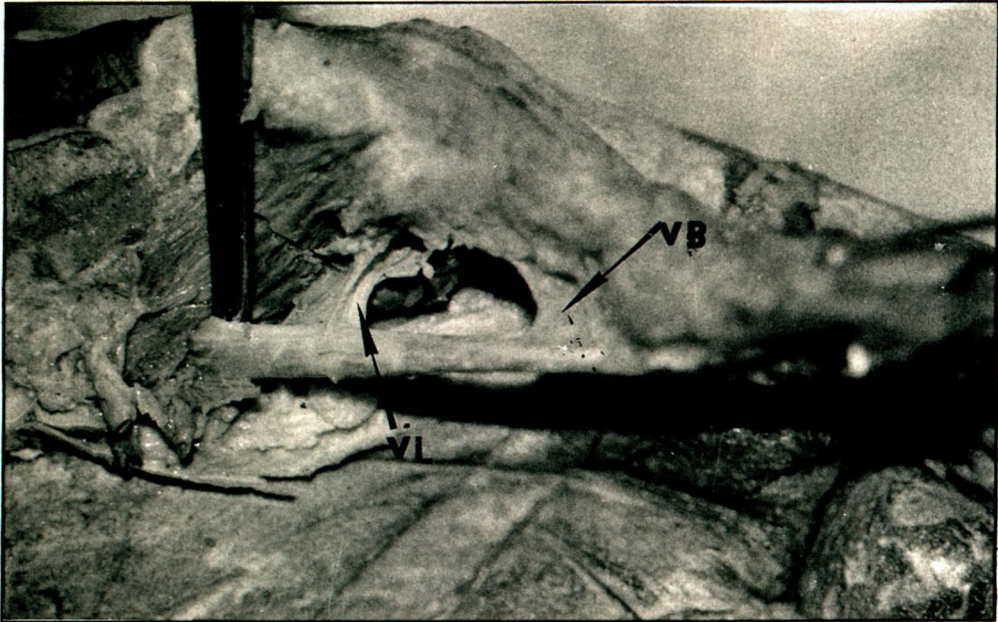


Fig 1. Vinculum breve (VB) and Vinculum longum (VL) of the musculus flexor pollicis longus in thumb.

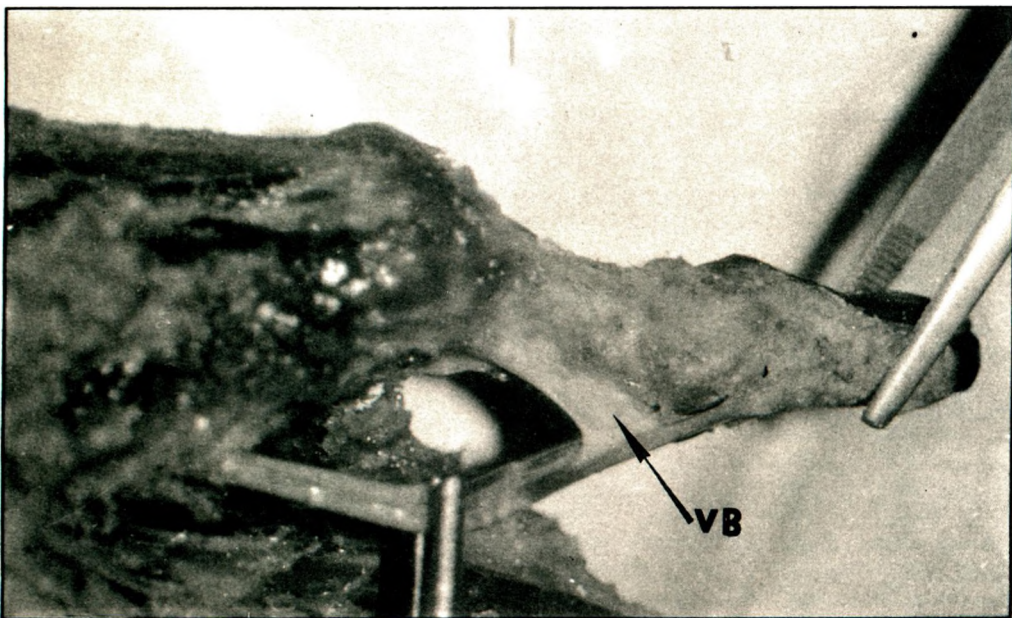


Fig 2. Vinculum breve (VB) of flexor pollicis longus.

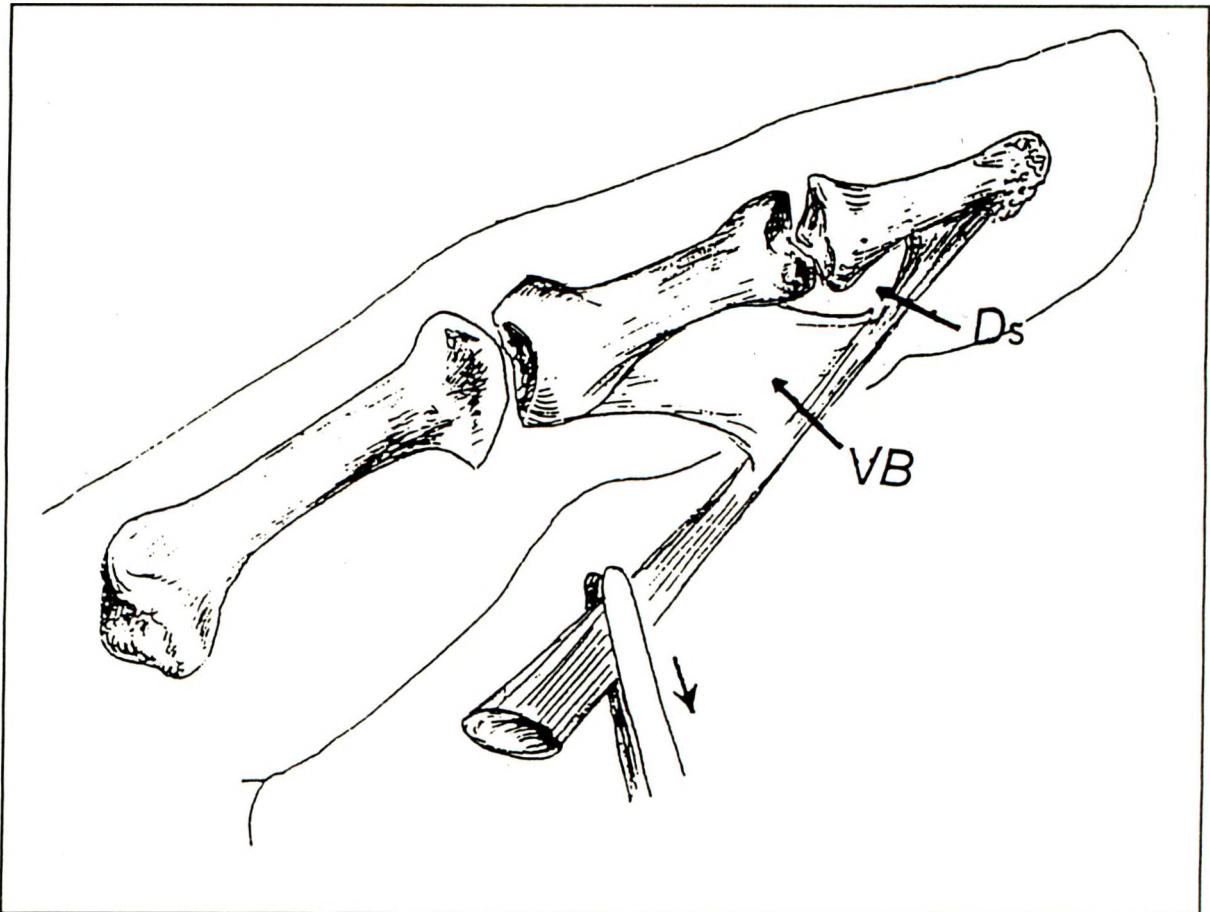


Fig 3. Schematic diagram shows absence of Vinculum breve at its distal end. Distal space (Ds), Vinculum breve (VB).

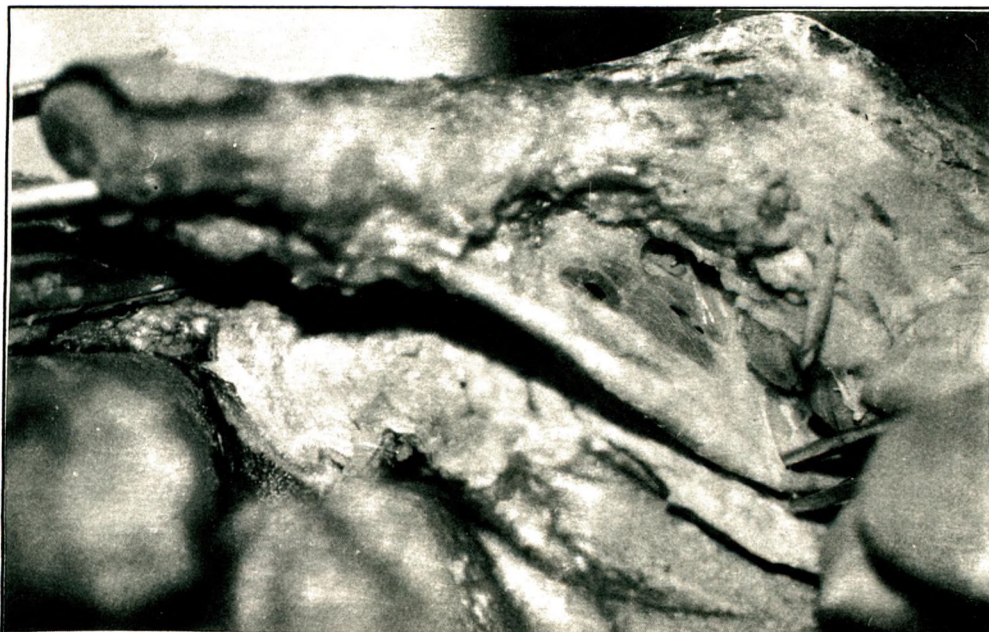


Fig 4. Vinculum longum and Vinculum breve of the flexor pollicis longus were continuous in one case.

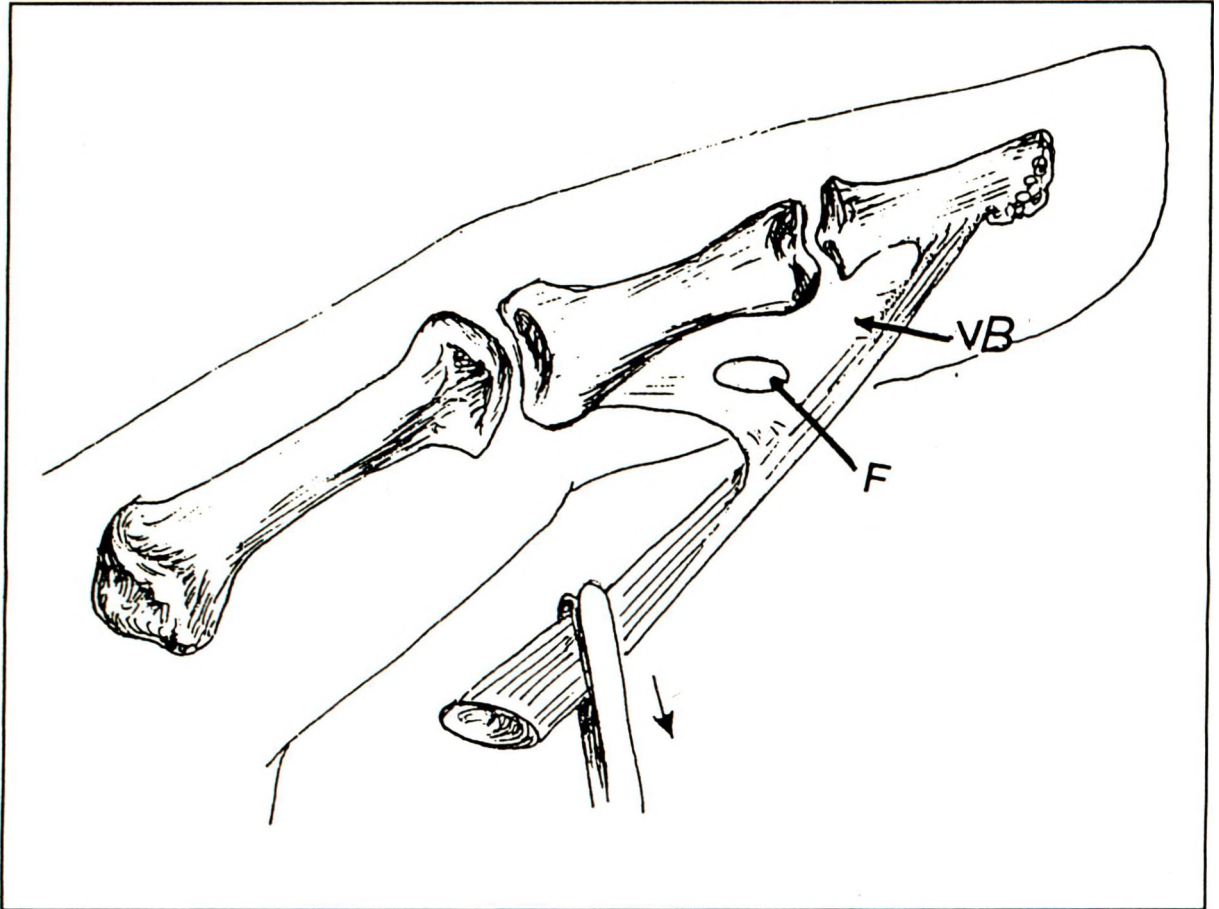


Fig 5. A single case representing fenestrated vinculum breve Fenestration (F); Vinculum breve (VB).

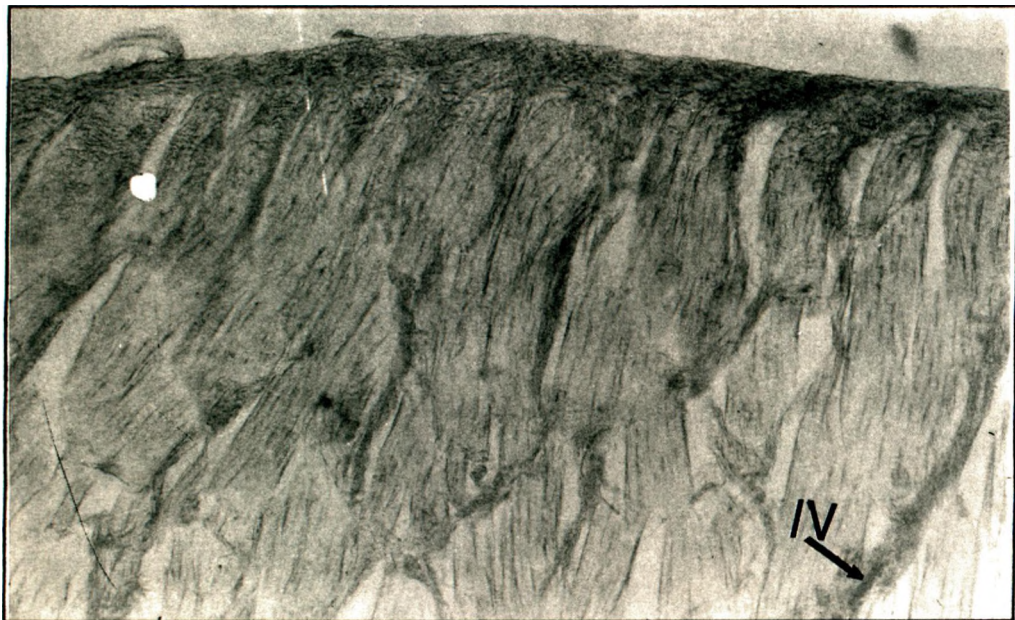

Fig 6. Section from the proximal part of Vinculum longum represents intrinsic blood vessels (IV). Haematoxylin-Eosin staining X 33

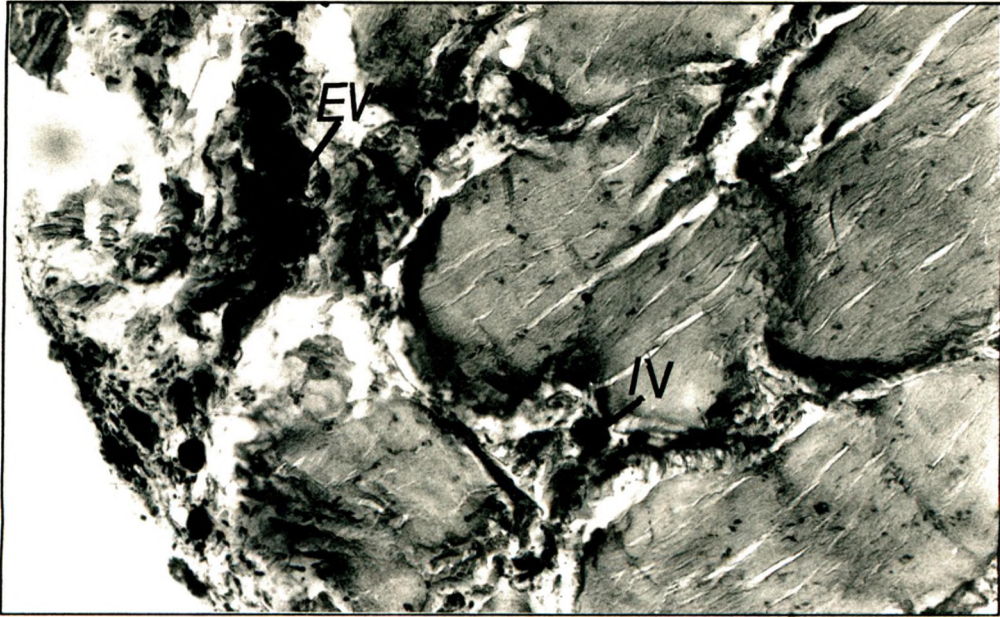


Fig 7. Micrograph of the histologic section taken at the Vinculum longum level: Extrinsic (EV) and Intrinsic (IV) blood vessels. Haematoxylin-Eosin staining X 33

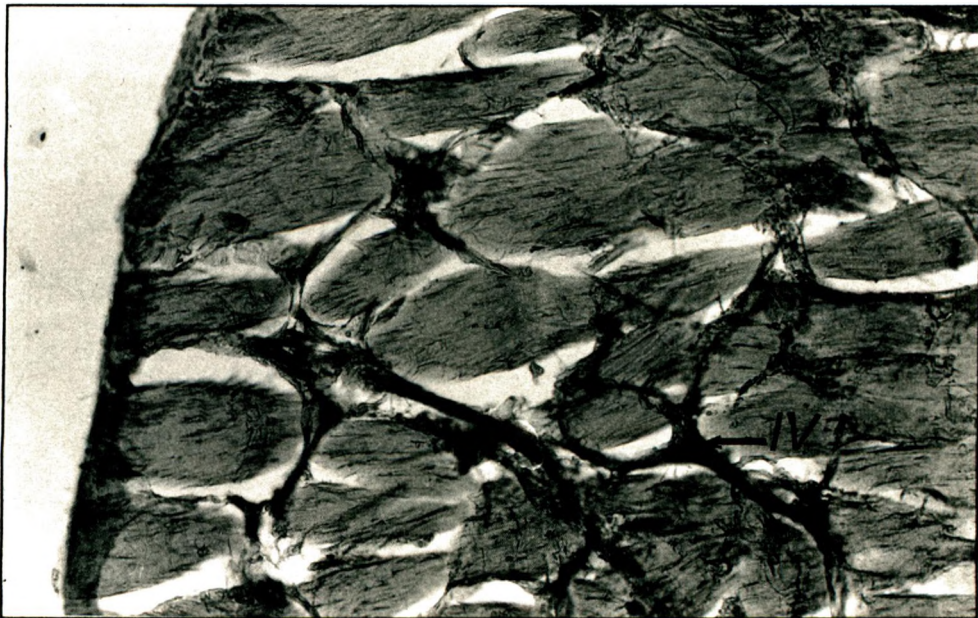


Fig 8. Section between Vinculum longum and Vinculum breve. Intrinsic blood vessels (IV). Haematoxylin-Eosin staining X 33.

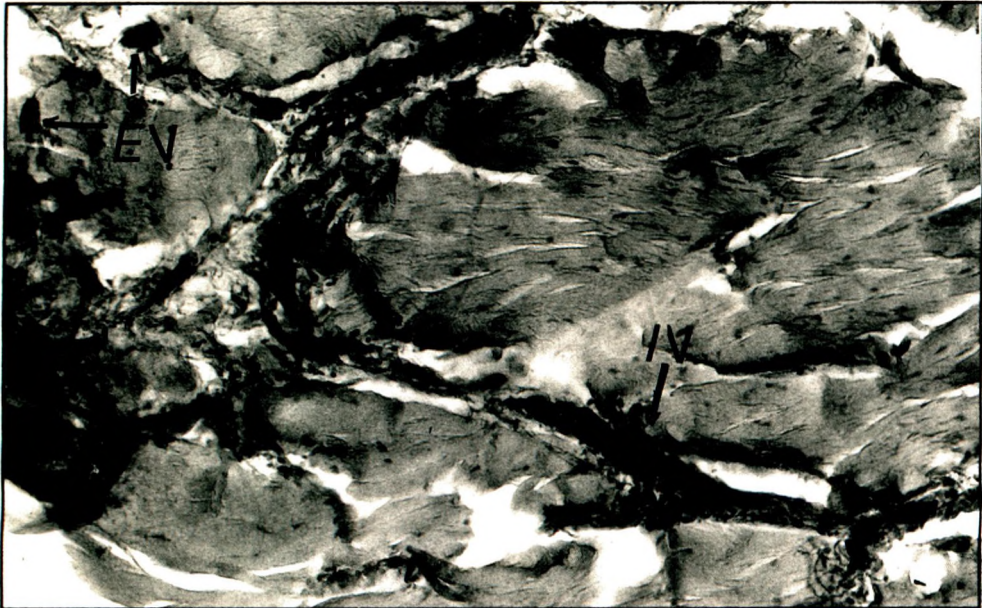


Fig 9. Numerous Extrinsic (EV) and Intrinsic (IV) blood vessels at the level of Vinculum breve were seen. Haematoxylin-Eosin staining X 33.

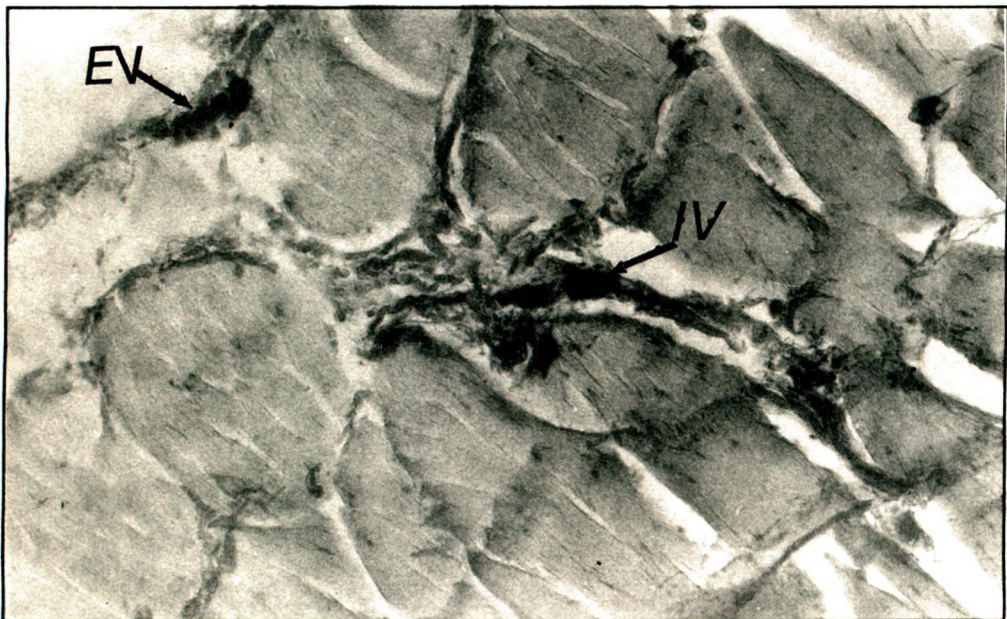


Fig 10. Extrinsic (EV) and Intrinsic (IV) blood vessels at the distal part of Vinculum breve. Haematoxylin-Eosin staining X 33.

DISCUSSION

Investigations on the blood supply of long tendons of the digits are clinically important especially for hand surgery by means of tendon revascularization.

It is well known that the thumb is one of the most essential finger for hand functions and thus, revascularization of the long tendon of flexor pollicis longus muscle of the thumb bears major importance for a complete functional hand.

The source of the arterial supply to the flexor pollicis longus tendon is of lack of agreement. While some investigators pointed out the major role of the vincular system for the vascularization of the long tendon, nutrient supply through synovial fluid was also mentioned by others (1-4,7). The vincular system is also thought to transmit flexion force to the digits (2).

In this study, long tendon supply was observed through two major sources. As a primary route the presence of extrinsic vessels entering from the dorsal surface of the tendon was described. In the secondary one the minute intrinsic vessels were parallel within the collagenous bundles, extending throughout the length of the tendon.

Armenta et al (2) pointed out the importance of the vincular system for the transmission of flexion force to the digits. Surgical treatment of this system is of critical importance to both the revascularization of tendon and its contribution to the flexion action.

The nutrient pathway of long tendons and intratendinous arrangement of vessels are important for hand surgery in analysing the prognosis of primary suture of the flexor tendon injuries. We think that the present study could contribute to both the hand surgery and the post-operational rehabilitation programs which are gaining more and more significance.

REFERENCES

1. Azar CA, Culver JE, Fleegler JE. Blood supply of the flexor pollicis longus tendon. *J Hand Surgery* 1983;8(4):471-475.
2. Armenta E, Fisher J. Anatomy of flexor pollicis longus vinculum system. *J Hand Surgery* 1984;9(2):210-212.
3. Armenta E, Lehrman A. The vincula to the flexor tendons of the hand. *J Hand Surgery* 1980;5(2):127-133.
4. Ochiai N, Matusi T, Miyaji N, Merklin RJ, Hunter JM. Vascular anatomy of flexor tendons. I. Vincular system and blood supply of the profundus tendon in the digital sheath. *J Hand Surg* 1979;4(4):321-330.
5. Verden CE. Half a century of flexor - tendon surgery. Current status and changing philosophies. *J Bone Joint Surg* 1972;54:472.
6. Zhang ZZ, Zhong SZ, Sun B, Ho QT. Blood supply of the flexor digital tendon in the hand and its clinical significance. *J Clin Anat* 1990;12:113-117.
7. Manske PR, Lesker PA. Nutrient pathways of flexor tendons in primates. *J Hand Surg* 1982;7(5):436-444.