



Case Report / Olgu sunumu

A Giant Hepatic Hydatid Cyst: Case Report

Karaciğer Yerleşimli Dev Kist Hidatik: Olgu Sunumu

İlhan Paltacı¹, Serdar Gümüş²

¹General Surgery Clinic, Hatay Research and Training Hospital, Hatay, Türkiye
²Surgical Oncology Clinic, Hatay Research and Training Hospital, Hatay, Türkiye

Abstract

Hydatid cyst is a general health problem that can be seen in every country, with a higher prevalence in some certain areas. Liver is the most involved organ. The disease is usually asymptomatic. The cyst may enlarge and lead to compressive symptoms or complications through opening to THE biliary system. Although medical agents and surgical interventions have long been used in the treatment of hydatid cyst, minimally invasive percutaneous interventions and laparoscopic surgical interventions are also safely applied in selected patients. In this paper, we presented a case of a giant hepatic hydatid cyst for which we preferred open surgery.

Keywords: Hydatid cyst, liver, giant, surgery

INTRODUCTION

Hydatid cyst is a parasitic disease caused by a cestode known as echinococcus.^[1] Four out of 12 types of the parasite cause human disease. These include Echinococcus granulosus, Echinococcus multilocularis (alveolar hydatid cyst), Echinococcus vogeli (polycystic echinococcus) and Echinococcus oligarthrus.^[2,3] The first two have clinical importance. Echinococcus granulosus is the most common type. Dogs, foxes and wolves are the main host of Echinococcus granulosus, and cattle, sheep and goats are the intermediate host. The disease is prevalent in the Middle East, Middle Europe, Australia and South America where intermediate hosts are commonly bred. The parasite egg, which is ingested by mouth, reaches the liver through the portal system and located there or causes disease in other organs by passing to the systemic circulation. Internal organ involvement is frequently observed, mainly involving the liver (70%) and the lungs (10-15%).

Öz

Kist hidatik dünya üzerinde belli bölgelerde yoğun olmakla beraber her ülkede görülebilen genel bir sağlık sorunudur. En sık görülen organ tutulumu karaciğerdir. Genellikle asemptomatik seyretmektedir. Kist boyutları büyüyerek bası semptomlarına veya biliyer sisteme açılarak komplikasyon gelişimine neden olabilir. Kist hidatik tedavisinde medikal ajanlar ve cerrahi girişimler kullanılmakla beraber, son dönemde minimal invaziv özelliğe sahip olan perkutan girişimler ve laparoskopik cerrahi girişimler seçilmiş hastalarda güvenle uygulanmaktadır. Biz bu yazımızda açık cerrahi prodedür tercih ettiğimiz dev boyuta ulaşan, karaciğer kist hidatik olgusunu sunduk.

Anahtar Kelimeler: Kist hidatik, karaciğer, dev, cerrahi

CASE

A 19-year-old female patient was admitted to the General Surgery Clinic of Hatay Research and Training Hospital with complaints of abdominal distention, loss of appetite, intermittent vomiting and weight loss. On physical examination, a mass lesion extending from the right subcostal space to the pelvic region and leading to swelling in the abdomen was palpated. On laboratory examination, aspartate aminotransferase (AST) was 23 IU/L, alanine aminotransferase (ALT) was 51 IU/L and alkaline phosphatase (ALP) was 112 IU/L. Computed tomography of the abdomen revealed a cystic mass lesion measuring 236 mm in the cranio-caudal plain and 109x90 mm in the transverse plain, showing an intra-abdominal extension in the left lobe of the liver and consistent with Type III hydatid cyst (**Figure 1**).



The patient underwent surgery under general anesthesia after having obtained approval for anesthesia. The abdomen was entered through a midline incision. The cyst was seen to extend from the left lobe of the liver to the pelvic region and omental and intestinal loop adhesions were observed (**Figure 2**). To prevent contamination, the intra-abdominal organs and the vicinity of the cyst were washed with hypertonic solution (10% NaCl). The cyst content was aspirated and it was seen to be cyst hydatid rockwater(?). Cystotomy was applied and the germinative membrane and the daughter vesicles were evacuated (**Figure 3**). The inner surface of the cyst was washed with hypertonic solution and 10 minutes were awaited. After cystectomy had been applied to the hepatic margin, omentoplasty was applied to the cavity. Drains were placed into the pelvic region and the subhepatic region and the operation was terminated. On post-operative follow-ups, hemorrhagic material was drained and 2 units of erythrocytes were transfused. The control hemoglobin and hematocrit values were seen to be stable on the follow-ups. The drainage content was observed to convert to sero-hemorrhage. The patient's vital signs and laboratory parameters were stable, and hence, she was discharged with per-oral albendazole on the post-operative 9th day. Written informed consent was obtained from the patient to publish this case report and accompanying images.

DISCUSSION

Most hydatid cysts do not cause symptoms. The disease is usually asymptomatic; however, clinical symptoms may be seen depending on the size or the location of the cyst or due to the compression caused by the enlarged cyst.^[5] Our patient had symptoms such as abdominal distention, vomiting and loss of appetite due to compression onto the gastrointestinal organs.

Rupture into the bile ducts is the most common complication of hydatid cyst and seen in 5-17% of the patients.^[6] In our patient, the cyst was not in connection with the biliary system. Intra-peritoneal free rupture may be spontaneous or due to trauma, and in these cases, the rate of anaphylaxis and death has been reported as 25%.^[7] In our case, the cyst was not ruptured although it extended to the pelvic region.

Diagnosis of hydatid cyst is made by imaging methods and may be confirmed with serological tests; however, negative test results do not exclude the disease.^[8] IHA was found to be 1/2560 positive in our case.

There are some laboratory tests in the differential diagnosis between liver hydatid cyst and simple cyst. Blood eosinophilia values may be 39 percent higher in liver hydatid cyst.

Other serological indicator tests, such as EgAg5, EgAgBs, endophilin B1, and rEgAgB2, whose applicability has been studied, are among the tests that will be used in differential diagnosis in the future.^[9]

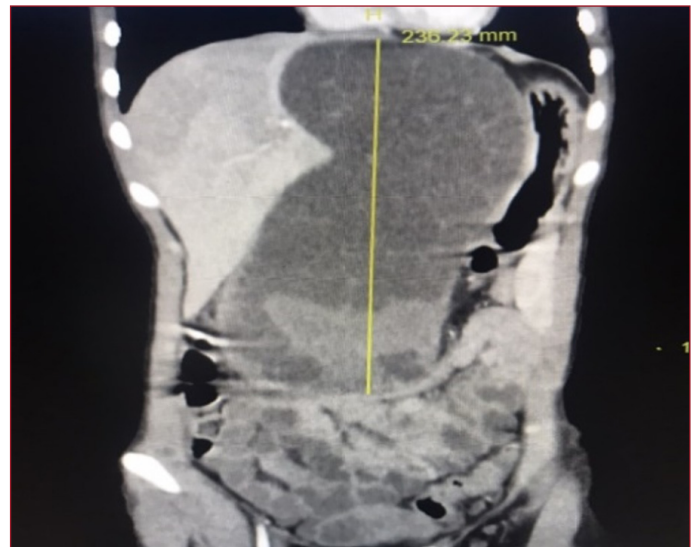


Figure 1. CT image of the lesion

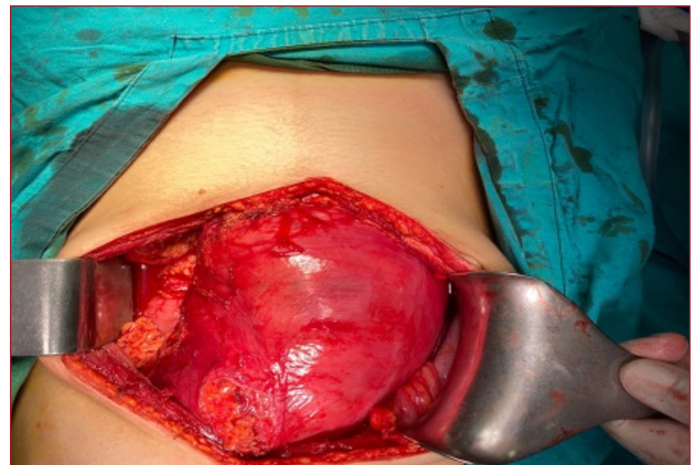


Figure 2. The incision and appearance of the cyst (?)

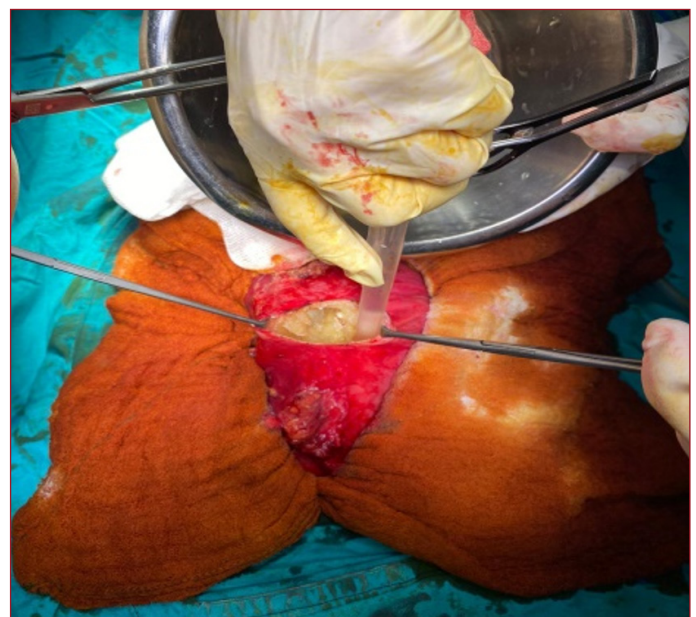

Figure 3. Intra-operative appearance (?)

Some studies report that the recurrence rate of liver hydatid cyst after primary surgery is between 6% and 30%, and that there is no significant difference in postoperative complications between laparoscopic surgery and open surgery. However, open surgery is still the main method of surgical treatment today, and an increasing number of studies hope to achieve therapeutic goals with more minimally invasive methods such as piercing-grinder-aspirator-apparatus (PGAA) and nanosecond pulsed electric field (nsPEF). However, laparoscopic surgery also has some shortcomings, such as difficulty in exposing partial cysts and an increased risk of fluid leakage.^[10]

Surgical procedures may be divided to two as conservative and radical. While the cyst is totally removed in radical interventions (regular hepatectomy, total pericystectomy, etc.), residual cyst cavity remains in conservative interventions. In hepatic hydatid cyst disease, unroofing and drainage operations that are deemed conservative are preferred more often and radical resections are performed in selected patients.^[11] It should be kept in mind that intra-operative complications may develop more frequently in radical approaches.^[12] The aim of surgical interventions is to inactivate the cyst, to prevent the spread of the cyst content in the abdomen, to clear cyst content and to reduce the cyst cavity as much as possible. In our case, we performed subtotal cystectomy-omentoplasty up to the hepatic margin.

CONCLUSION

In endemic regions for hydatid cyst, the importance of evaluating the suspected patients for hydatid cyst disease, which may lead to liver and other intra-abdominal organ involvement, should be considered. The primary treatment is interventional and the spectrum lies between percutaneous drainage and open radical surgery. The lesion should be evaluated with radiological methods before any intervention. Individualized treatment plans should be made. Surgical treatment should be supported by albendazole treatment.

ETHICAL DECLARATIONS

Informed Consent: All patients signed the free and informed consent form.

Referee Evaluation Process: Externally peer-reviewed.

Conflict of Interest Statement: The authors have no conflicts of interest to declare.

Financial Disclosure: No financial support was received from any organisation in this study.

Author Contributions: All of the authors declare that they have all participated in the design, execution, and analysis of the paper, and that they have approved the final version.

REFERENCES

1. Akhan O, Ozmen MN, Dinçer A, Sayek I, Göçmen A. Liver hydatid disease: long-term results of percutaneous treatment. *Radiology* 1996;198:259-64.
2. Merkle EM, Schulte M, Vogel J, et al. Musculoskeletal involvement in cystic echinococcosis: report of eight cases and review of the literature. *AJR Am J Roentgenol* 1997;168:1531-4.
3. Parola P, Mathieu D, Panuel M, Poitout D, Brouqui P. Photo quiz. Diagnosis: hydatid bone disease (cystic echinococcosis). *Clin Infect Dis* 2000;31:543-4.
4. Sayek I, Tirnaksiz MB, Dogan R. Cystic hydatid disease: current trends in diagnosis and management. *Surg Today* 2004;34:987-96.
5. Schwartz S et al. Principles of Surgery, (Çeviri e. İ. Ethem Geçim), Bölüm:28, VII.Baskı, Antip, Ankara. 2004 s:1425.
6. Zargar SA, Khuroo MS, Khan BA, Dar MY, Alai MS, Koul P. Intrahepatic rupture of hepatic hydatid cyst: sonographic and cholangiographic appearance. *Gastrointest Radiol*. 1992;17(1):41-5.
7. Ozturk G, Aydinli B, Yildirgan MI, et al. Posttraumatic free intraperitoneal rupture of liver cystic echinococcosis: a case series and review of literature. *Am J Surg*. 2007;194(3):313-6.
8. Morar R, Feldman C. Pulmonary echinococcosis. *Eur Respir J* 2003;21:1069-77.
9. Botezatu C, Mastalier B, Patrascu T. Hepatic hydatid cyst – diagnose and treatment algorithm. *J Med Life*. 2018;11:203–9.
10. Ormeci N, Soykan I, Bektas A, et al. A new percutaneous approach for the treatment of hydatid cysts of the liver. *Am J Gastroenterol*. 2001;96:2225–30.
11. Tuxun T, Zhang JH, Zhao JM, et al. World review of laparoscopic treatment of liver cystic echinococcosis – 914 patients. *Int J Infect Dis*. 2014;24:43-50.
12. Atmatzidis KS, Pavlidis TE, Papaziogas BT, Mirelis C, Papaziogas TB. Recurrence and long-term outcome after open cystectomy with omentoplasty for hepatic hydatid disease in an endemic area. *Acta Chir Belg*. 2005;105:198-202.