

Distraction chondroneogenesis on rabbit's ear cartilage

Tavşan kulak kıkırdığında distraksiyon kondroneogenezi

Fatma Nihal DURMUŞ KOCAASLAN, Özhan ÇELEBİLER, Ayhan NUMANOĞLU, Hüseyin Kemal TÜRKÖZ

ABSTRACT

Objective: Application of distraction is an alternative to bone graft or flap operations for repairing bone defects. Bone can be extended in width and length without using a new donor area. Operation time is shortened and failures are reduced without any concern about graft or flap loss. However, there are no distraction methods known for generating new cartilage as an alternative to graft or flap applications in repairs of cartilage defects. This experimental study was planned to determine whether or not chondroneogenesis can be obtained via application of distraction.

Methods: Fourteen New Zealand rabbits were used in this study. Distractions at a rate of 0.50 mm/day, 0.25 mm/day and 0.25 mm on alternate days were applied on 3 rabbits consecutively and the ideal distraction rate was determined as 0.25 mm once every two days. On alternate days 0.25 mm of distraction was applied for two months aiming to generate 7.5 mm of new cartilage.

Results: In the rabbits in which 0.25 mm of distraction on alternate days had been applied, regular new cartilage formation was observed.

Conclusions: According to these findings, the slow metabolic rate of avascular cartilage tissue affects distraction rates and rhythms. However, by applying distraction and taking advantage of the regenerative capacity of the perichondrium, it is possible to generate new and regular chondrocytes and extend the cartilage.

Key words: Cartilage, Distraction, Rabbit.

ÖZET

Amaç: Distraksiyon, kemik defektlerinin onarımı için kullanılan, kemik grefti ya da flebi ameliyatlarına alternatif bir uygulamadır. Yeni bir donör alan kullanılmadan kemik hem enine hem de boyuna uzatılabilmektedir. Ameliyat süresi kısaltılmakta ve greft veya flep kaybı endişesi olmaksızın başarısızlık düşmektedir. Oysa kıkırdak defekti onarımında greft ya da flep uygulamasına alternatif olarak yeni kıkırdak oluşturacak bir distraksiyon yöntemi bilinmemektedir. Distraksiyon yöntemi ile kondroneogenezis oluşturulup oluşturulamayacağını araştırmak amacıyla bu deneysel çalışma planlanmıştır.

Yöntem: Bu çalışmada toplam 14 adet Yeni Zelanda tavşanı kullanıldı. Ardişık 3 adet tavşanda 0,50 mm/gün, 0,25 mm/gün ve gūnaşırı 0,25 mm'lik distraksiyonlar yapıldı ve ideal distraksiyon hızının iki günde bir kez 0,25 mm olmasına karar verildi. İki ay boyunca gūn aşırı 0,25 mm distraksiyon uygulandı ve toplam 7,5 mm yeni kıkırdak oluşması planlandı.

Bulgular: Gūnaşırı 0,25 mm hızda distraksiyon yapılan hayvanlarda distraksiyon alanında düzenli yeni kıkırdak dokusu oluşumu izlendi.

Sonuç: Bu deneysel çalışmada elde edilen bulgulara göre, avasküler kıkırdak dokusunun metabolizmasının yavaş olması, distraksiyon hızını ve ritmini etkilemektedir. Ancak distraksiyon yöntemiyle, perikondriumun rejenerasyon kapasitesinden de faydalanılarak, yeni ve düzenli kondrosit oluşturmak ve kıkırdakta uzatabilmek mümkündür.

Anahtar kelimeler: Kıkırdak, Distraksiyon, Tavşan

Introduction

Application of distraction is an alternative to bone graft or flap operations for repairing bone defects [1]. The patient's bone can be extended in width and length without using a new donor area. Operation time is shortened and failure rate of the operation is reduced without any concern about graft/flap loss. Besides this, surrounding tissues also participate to the distraction. Therefore, distraction osteogenesis (DO) has become an important alternative treatment for repairing the long bones with muscle, nerve, vein and skin. Thus, flap or graft loss risk is eliminated and the tissue is repaired on its own. There are no distraction methods known to generate new cartilage as an alternative to graft or flap applications in the repair of cartilage defects.

Fatma Nihal Durmuş Kocaaslan (✉), Özhan Çelebiler, Ayhan Numanoğlu,
Department of Plastic and Reconstructive Surgery, School of Medicine,
Marmara University, Istanbul, Turkey
e-mail: dr-nihal@hotmail.com

Hüseyin Kemal Türköz
Department of Pathology, School of Medicine,
Marmara University, Istanbul, Turkey

Submitted/Gönderilme: 20.05.2013 - Accepted/Kabul: 01.07.2013

Lengthening of long bones by distraction was introduced and defined in the era of Hippocrates [2] and was applied in various experiments and clinical settings. Basic principles were set forth by the Russian orthopedic surgeon Ilizarov in 1951. Afterwards, distraction became popular and is commonly and widely applied today in many areas [3, 4]. Based on the basic principles of the method, which is defined as the distraction osteogenesis (DO), experimental and clinical applications were carried out on many tissues such as the maxillofacial region, nerve, vertebrae, etc [5-9].

Cartilage tissue is a specialized support tissue playing an important role in the distribution of the loads at the joints (hyaline cartilage), transfer of the loads between tendon and bone (fibrocartilage) and formation of a flexible support against external structures (elastic cartilage) [10,11]. It shapes the overlying skin such as the nose, ear and the eyelids. It prevents friction between joint surfaces as well as consequent wear of the bone; it gives mobility to the joints. Furthermore, it is found where bones connect such as the rib and the sternocostal joints (10). In addition to these functions, it is clinically important that cartilage grafts can be harvested from these areas.

Cartilage is an avascular tissue. Nutrients enter by diffusion from perichondrial capillaries or synovial fluids of the joints. Therefore, the passage of nutrients is limited by the thickness of the cartilage. In some cases, veins pass through the cartilage in order to nourish another tissue; however, they do not deliver nutrients to the cartilage. Like cells of all avascular tissues, chondrocytes also display a low metabolic activity. Cartilage does not have lymphatic veins or nerves [12].

Damaged cartilage is mostly repaired incompletely and regeneration is implemented by perichondrial activity. In 1959, Lester announced that separation of the perichondrium from the cartilage causes new cartilage formation [10]. The clinical importance of this fact was not recognized until 1972, when the cartilage generating capacity of perichondrium was noticed during an investigation of the etiology of wrestler's ear. It is thought that, separation of the perichondrium from the cartilage prevents the contact inhibition, thus, leading to formation of new cartilage [13-15].

In cartilage defects, distraction of the cartilage areas by the use of surrounding tissues can also be considered as a reconstruction method instead of repairing with cartilage graft. Although there is no clinical or experimental study using the regenerative capacity of the perichondrium and the adaptation of the surrounding tissues to the distraction, the defect can be repaired and additional morbidity of the donor area is spared.

In order to eliminate the risk of graft loss and to repair the cartilage defect with surrounding tissues, we present a study of cartilage based on the osteoneogenesis principle and the generation and histopathological demonstration of new cartilage tissue.

Methods

The study was conducted at Marmara University, School of Medicine, Experimental Research and Animal Laboratory with the approval of the Marmara University, School of Medicine and Ethics Committee for Experimental Animals.

In this study 14 male New Zealand type white rabbits, average weight of 2500-3500 grams of similar ages (6 months) were used. The rabbits were fed in their cages with rabbit feed and tap water in the laboratory. During the study, the rabbits were observed in single large cages under conditions determined as suitable for these experimental animals.

Excision Group

Four rabbits were left for secondary healing after a cartilage segment, 1cm in width, was removed from one ear of each rabbit. Samples of the region of new tissue formation were taken from two animals at the end of four weeks and from the other two animals at the end of eight weeks for examination of the newly generated cartilage.

Pilot Study Group

In order to determine the ideal rate of distraction for cartilage, distraction was applied on 3 different rabbits at 0.50 mm/day for 15 days, 0.25 mm/days for 30 days and 0.25 mm every other day for 60 days, respectively [15], intending a total of 7.5mm. Partial necrosis and "cheese cuttings" were observed in rabbits that had daily distraction applied. Therefore, it was decided that the ideal distraction rate should be 0.25 mm once every two days. At the end of the distraction period cartilage samples were taken from the distraction zone of the ear cartilage of the distraction group.

Distraction Group

Seven rabbits were used. External distraction devices were placed on one ear following the chondrotomy. We aimed to achieve a new cartilage of 7.5mm by applying 0.25 mm of distraction every two days for two months. At the end of two months, sagittal cross sections of the samples from the distraction zone were examined.

Distraction devices were prepared by embedding the 35 mm long distraction bar (MODUS MDO 2.0 Medartis®, Basel, Switzerland) into melted silicone in a manner to comply with the surface and the weight of the rabbit's ear. A silicone plaque of the same size was prepared in order to determine the device which will settle on the auricle externally and which will be determined in the auricle internally as well and was divided into two parts with the same size as silicone in which distraction device was embedded. Totally 4 modules were produced; i.e. two parts embedded into the distraction device and the other two parts to be placed into the internal surface of the auricle. Thus, it was ensured that the two parts

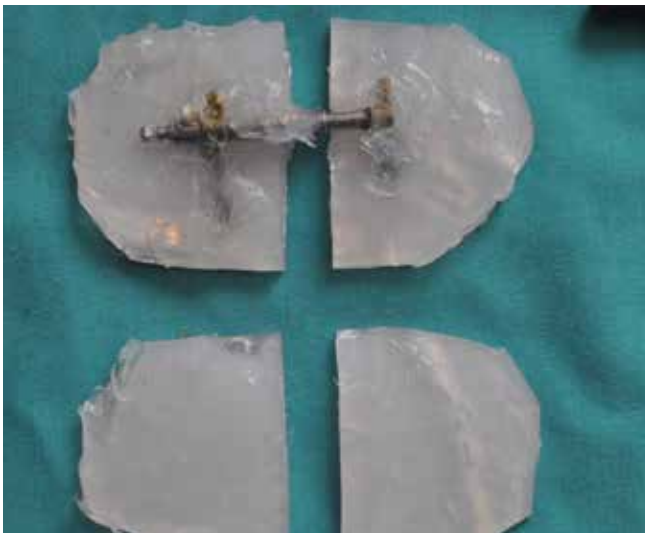


Figure 1. Distraction device. Support pieces that will be placed on the posterior surface of the ear and the distraction device screwdriver

to be placed on auricle externally would be fastened into two parts on the auricle internally (Figure 1).

The external surfaces of each rabbit's ear were shaved with an electrical device. A drawing was made according to the incision plan following cleaning with Polyvinylpyrrolidone iodine (Polyvidone iodine) 7.5% (ISOSOL Scrub, Adeka®) (Figure 3). Following sedation with 3-5mg/kg IM xylazine hydrochloride (Rompun 2%, Bayer®) tumescent anesthesia which contains 3-4cc lidocaine with adrenaline (Jetokain ampule, Adeka®) was administered subcutaneously across incision line and across the chondrotomy line. Two parallel vertical skin incisions of 4-5 cm were made and a subcutaneous tunnel was created. Cartilage was exposed while preserving the perichondrium (Figure 2).

The cartilage was incised so as to divide the entire ear into cranial and caudal pieces in transverse axis and additionally, skin and perichondrium were kept intact on the internal surface of the ear (Chondrotomy) (Figure 3). Cartilage was dissected subperichondrially approximately 1 cm caudal and cranial on both surfaces.

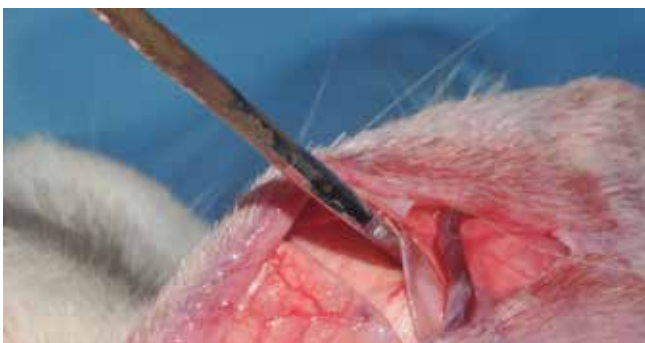

Figure 2. Incisions and dissection. Two skin incisions parallel to each other along the vertical axis of the ear and dissection.

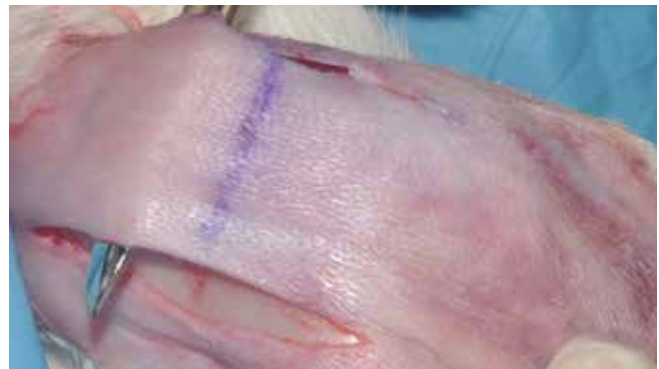


Figure 3. Chondrotomy. Cartilage incision along the horizontal axis of the ear and perichondrium kept intact.

The skin was sutured with 4/0 rapid vicryl. Followed by antibiotic ointment application. The distraction device was adapted to the surface of the external ear and 2 supporting pieces were adapted to the surface of the internal ear and sutured to each other with 3/0 prolene. Ears were sutured to each other with a single suture to obtain elevation for minimal postoperative edema and to prevent the removal of the device by the rabbit. The suture was removed one week postoperatively.

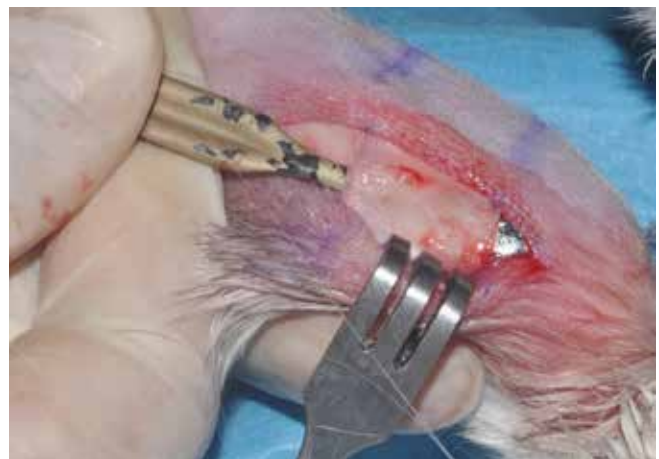

Figure 4. Dissection of the cartilage segment. Dissection and excision of the cartilage segment 1 cm in width.

In the excision group, following the same markings and dissection, a cartilage segment of 1cm in width was excised but the perichondrium was preserved (Figure 4). The perichondrium was placed back into the defect and the skin was sutured with 4/0 rapid vicryl.

In the post operative period all animals were observed and followed in separate cages without any antibiotherapy.

In order to determine the best rate and the rhythm of distraction, 3 different distraction methods were planned at a rate of 0.5 mm/day, 0.25 mm/day and 0.25 mm every two days. Distraction devices were activated by a screwdriver.

Distraction was carried out for 15, 30 and 60 days respectively. No consolidation period was implemented after the completion of distraction because unlike bone tissue, supportive function was not expected in cartilage. Following the completion of activation, the animals were sacrificed with a high-dose of intravenous sodium pentothal injected

After the distraction rhythm was set as 0.25 mm every two days the same operation was performed on 7 different rabbits. Distraction devices were removed and the animals were sacrificed two months later at the end of distraction period. After the macroscopic assessment, the ears were amputated in one piece.

The other four animals which had had a cartilage segment excised were sacrificed by the same method and samples were taken.

The samples were placed in a 10% solution of formaldehyde (for 24 hours) and were dehydrated, cleared and blocked in paraffin in the Marmara University School of Medicine, Department of Pathology. Sections (3 μ in thickness) were cut across the vertical plane of the rabbit's ear on a microtome (Leica). All samples were stained with hematoxylin and eosin and examined by light microscopy with 40x and 100x magnify.

Results

Macroscopic findings

In the distraction group, when the device was removed a full layer of necrosis due to pressure was observed in one ear. This animal was excluded from the study.

Although a lengthening was observed on ears on which distraction had been applied (Figure 5), quantitative evaluations were not performed due to the weakness of the cartilage and a certain level of contraction that may have occurred.

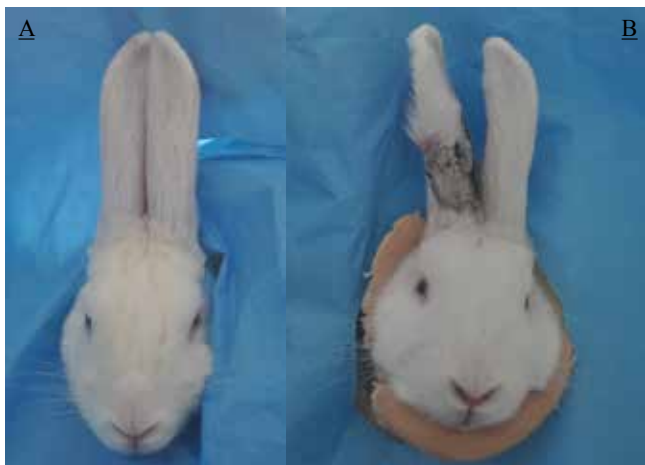

Figure 5. Difference in the lengths of the ear before and after the distraction
A. Before the distraction, B. After the distraction

Histopathologic findings

Excision group: In the cartilage segment of the excision group 2 rabbits were sacrificed at the end of fourth week, while the other 2 rabbits were sacrificed at the end of eighth week. At the end of fourth week an increase in the fibrous tissue, lymphocytes, and chronic inflammatory cell infiltration which consisted of plasmocytes and rare neutrophils and insufficient cartilage healing was observed.

In the samples which were taken on the eighth week an increase in fibrous tissue without inflammatory cell infiltration and with an insufficient cartilage healing was observed (Figure 6).

Pilot study group: The groups with a distraction rate of 0.5 mm/day and 0.25 mm/day revealed that chondroblastic proliferation could not follow the distraction vector caused by breaking off due to rapid distraction. Therefore, chondroblastic proliferation was random involving stromal

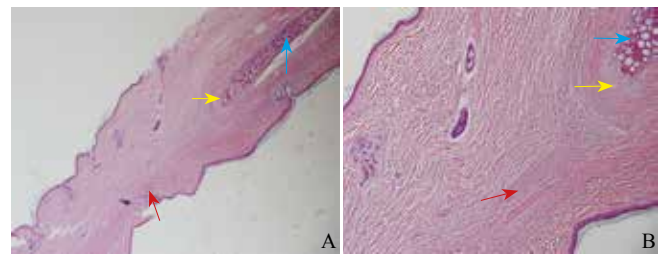


Figure 6. Cartilage excision group (8 weeks after surgery) A. 40-magnification examination, B. 100-magnification examination. Old chondrocytes (blue arrow), healing with fibrous tissue (red arrow), perichondrium (yellow arrow) (HE).

fibroblasts. Cartilage generation was observed in areas unrelated to the old cartilage tissue (Figure 7).

Distraction group: The distraction group showed that chondroblastic proliferation followed the line of growth and formed new cartilage tissue at the zone of distraction. At the centre and in areas near the old cartilage tissue, between the chondroid matrix, transformations of chondroblasts into chondrocytes that were forming mature cartilage tissue was observed (Figure 8).

The transition of the “normal cartilage area, - newly generated cartilage - normal cartilage area” was observed on the sections of the samples which were taken from the distraction zone, cranial and caudal part of the distraction zone.

Discussion

In this study, generation of new chondroblasts via cartilage distraction was planned by a method similar to the principle of distraction osteogenesis. The rabbit's ear was selected for this study since this has a broad cartilagenous surface.

In order to benefit from appositional growth of cartilage and to preserve the perichondrium during the experiment, the ear cartilage was incised on the horizontal

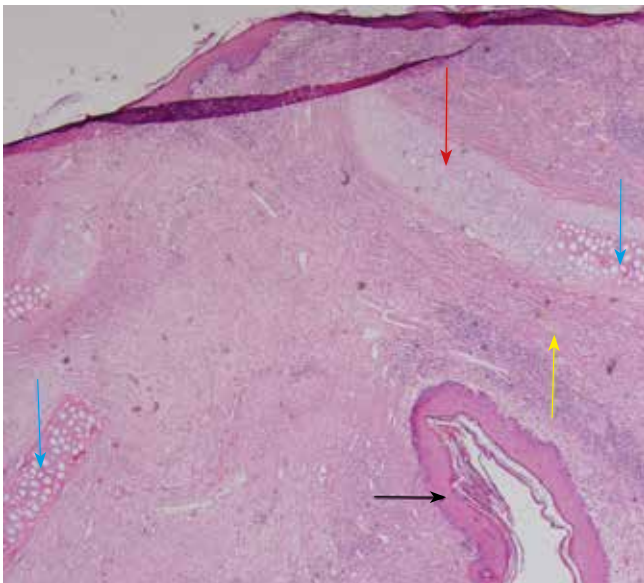


Figure 7. Rupture due to rapid distraction and the formation of irregular chondrocytes (40x). Newly formed chondroblasts (red arrow), old chondrocytes (blue arrow), perichondrium (yellow arrow), skin (black arrow) (40x) (HE).

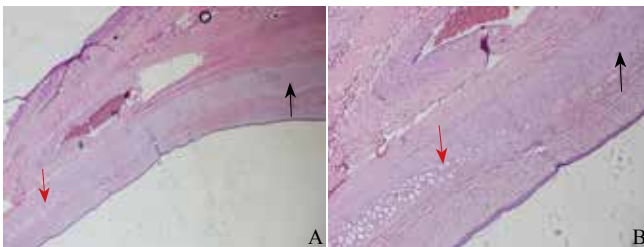


Figure 8. Microscopic image of the distraction group. A. Advancement of the chondroblasts originating from the perichondrium (black arrow) in the direction of the distraction (old chondrocytes are shown with red arrows), (40x) B. 100 magnification examination of the same sample (HE).

axis (chondrotomy). Appositional growth is obtained by proliferation of chondroblasts and their conversion into chondrocytes which originate from perichondrium [16], and has been seen in living structures that have completed their developmental growth. “Wrestler’s ear deformity” is an example of appositional growth where an increase in chondroblastic activity is seen as a result of removal of contact inhibition due to separation of the perichondrium from the subjacent cartilage [13, 14].

A pilot study was conducted to determine the most suitable schedule of distraction. Rupture between the cartilage segments and healing with the connective tissue are similar to the findings when rapid distraction is applied on bone tissue [17-19]. These data suggest that daily distraction in the cartilage is fast.

Histopathological examination of samples which were taken from the rabbits whose distraction rate was 0.25 mm/ every other day revealed that, new chondroblast formation progressed in line with the distraction vector in an orderly

manner and the ideal distraction rate was determined as 0.25 mm / every other day. After completion of the pilot study, distraction was applied to 7 rabbits at the ideal rate for 60 days. Full-layer necrosis was seen in one case. The reason is thought to be the fact that rabbits are susceptible to infection or as experience increases, more attention has been paid to the attachment of the custom-made distraction device.

Although the latent period after osteotomy was determined as 5, 7 or 10 days in the literature [20-23], it was observed that the maximum volume of callus was in the group in which distraction was applied after 7 days [24]. In this study, the latent period was determined as 7 days in order to minimize post-operative edema of the ear. During this period, the tip of both ears was sutured to each other with the help of a single suture and the suture was removed prior to activation. The ear on which the distraction device was placed was held in a low position due to the weight of the instrument. The aim was to get support from the healthy ear in this way. Thus, edema was reduced by ensuring the elevation of the ear and it also helped to prevent the rabbit’s feet from removing or damaging the the distraction device.

Considering that the auricle is lengthened in one direction by using a single-vector distraction device, three-dimensional growth of cartilage tissue can be targeted by using a multi-faceted distraction device as used in bones. In this case, for example, for an anomaly such as a lack of tissue of the upper 1/3 of the ear, defined as “cup-ear” deformity, the distraction device can be planned to be multi-faceted.

The biggest technical challenge for the cartilage distraction is that cartilage tissue is not as strong as bone tissue and soft tissue covers such as skin and mucosa is mostly fine in the body. In this case, it can cause “cheese cuttings” on the cartilage at the distraction device enforcement points. Indeed, with rapid distraction, formation of new cartilage could not be obtained due to the distraction device moving on the surface of the cartilage. This problem can be overcome technically by planning a distraction device that implements the force from several points to form a platform and by reducing the distraction rate (0.25 mm / every other day).

The distraction device should be designed according to the surface of the tissue, the desired shape, and be of suitable size and weight for the delicate structure of the cartilage. In addition, it should be fastened to the cartilage appropriately. Tight fastening can create necrosis due to pressure on the cartilage. However, insufficient fastening would not distract the tissue by scraping the distraction device from the cartilage.

In this experimental study, in the excision group, after resection of the ear cartilage in the fourth and eighth weeks, the histopathological findings showed that new cartilage cells did not occur. In this model, the insufficient formation of new cartilage tissue can be explained by the size of the defect although the perichondrium was left intact and the blood supply was thought to be normal. It is important that such a defect can be closed by distraction chondroneogenesis without using cartilage grafts.

Primary or secondary rhinoplasty operations, iatrogenic and congenital disorders of the nose, defects of ears and eyelids (trauma, cancer and infection) may require cartilage grafting. In fact, the body has an adequate donor area in terms of quantity and shape such as nasal septum, ear concha and rib cartilage. However, as the cartilage has no blood supply and is fed by osmotic diffusion [12, 25, 26], a sufficient vascular bed in the recipient region is crucial for the nutritional needs of the cartilage grafts and their survival in the recipient bed [25]. A resorption rate of 20% is seen even in a well vascularized bed [27, 28]. Reconstructive procedures involving the use of cartilage grafts are difficult cases due to lack of blood supply on the recipient bed and donor site requirements necessitate meticulous work. Therefore, in some situations, such as radiotherapy, which cause nutritional deficiencies in cartilage tissue, distraction may be an ideal solution for the repair of the defect as in DO [29, 30].

As a result, it has been demonstrated in this study that the new cartilage tissue can be generated by applying mechanical force to the cartilage. This method can be clinically applied for cases where cartilage grafting is not possible. It is considered that congenital or iatrogenic deficiencies of the cartilage can be repaired without a need for a donor area and that the cartilage can be lengthened together with the surrounding tissues.

Conclusion

In this study, distraction was performed on cartilage tissue in a method similar to the bone tissue and formation of new chondroblasts in the distraction zone was observed. The process was performed successfully on cartilage compared to the bone which is hard, durable and rich in nutritional supplies. This study showed that the cartilage, which has a healing capacity limited to small defects and most often heals itself with fibrous tissue, can form new chondrocytes by distraction and by utilizing the regenerative capacities of the perichondrium. This experimental research gives rise to the thought that body parts such as nose, ear, etc. can be repaired and lengthened together with the surrounding tissues by the distraction method, without using cartilage grafts.

References

1. Tsuchiya H, Tomita K. Distraction osteogenesis for treatment of bone loss in the lower extremity. *J Orthop Sci* 2003;81:116-24. doi: 10.1007/s007760300020
2. Eren A, Eralp L, Çakmak M (editors) et al. Ilizarov cerrahisi ve prensipleri: Ilizarov sisteminin dünyada ve Türkiye'de gelişimi. İstanbul: Doruk Grafik, 1999.
3. De Bastiani G, Aldegheri R, Renzi-Brivio L, et al. Limb lengthening by callus distraction (callotaxis). *J Pediatr Orthop* 1987;7:129-34. doi: 10.1097/01241398-198703000-00002
4. Ilizarov GA. The tension-stress effect on the genesis and growth of tissues: Part I. The influence of stability of fixation and soft-tissue preservation. *Clin Orthop* 1988;238:249-81.
5. Kürklü M. Periferik Sinir Defektlerinin Tedavisinde; Primer Tamir, Distraksiyon ve Greftleme Yöntemlerinin Karşılaştırılması. Gülhane Askeri Tıp Akademisi Askeri Tıp Fakültesi, Ortopedi ve Travmatoloji Uzmanlık Tezi, Ankara, 2003.
6. Markus K, Frank U, Thorsten G, et al. Effects of controlled dynamic disc distraction on degenerated intervertebral discs: An in vivo study on the rabbit lumbar spine model. *Spine* 2005;30:181-7.
7. Molina F, Ortiz Monasterio F, Aguilar M, et al. Maxillary distraction: aesthetic and functional benefits in cleft lip-palat and prognathic patients during mixed dentition. *Plast Reconstr Surg* 1998;4:951-63. doi: 10.1097/00006534-199804040-00010
8. Kessler P, Wiltfang J, Schultze-Mosgau S, et al. Distraction osteogenesis of the maxilla and midface using a subcutaneous device: report of four cases. *Br J Oral Maxillofac Surg* 2001;39:13-21.
9. Chin M, Toth BA. Le Fort III advancement with gradual distraction using internal devices. *Plast Reconstr Surg* 1997;100:819-30. doi: 10.1097/00006534-199709001-00001
10. Lester CW. Tissue replacement after subperichondrial resection of costal cartilage: Two case reports. *Plast Reconstr Surg* 1959;23:49-54. doi: 10.1097/00006534-195901000-00006
11. Maor G, Von Der Mark K, Reddi H. Acceleration of cartilage and bone differentiation on collagenous substrata. *Collagen Rel Res* 1987;7:351-70.
12. Fawcett DW. Cartilage. In: Fawcett DW, editor. *A Textbook of Histology*. 11th Edition. Philadelphia: WB Saunders, 1986: 188-9.
13. Ohlsen L, Vedung S. Reconstructing the antihelix of protruding ears by perichondrioplasty: a modified technique. *Plast Reconstr Surg* 1980;65:753-62 doi: 10.1097/00006534-198006000-00007
14. Skoog T, Ohlsen L, Sohn SA. Perichondrial potential for cartilaginous regeneration. *Scand J Plast Reconstr Surg* 1972;6:123-5. doi: 10.3109/02844317209036711
15. Rasmussen S, Sonne-Holm S. Bone lengthening. History of the development and field of applications. *Ugeskr Laeger* 1999 Aug 30;161:4863-7.
16. Junquera LC, Carneiro J, Kelley RO. Temel Histoloji. Çev: Aytekin Y, Solakoğlu S, Ahıskalı B. İstanbul: Barış Kitabevi, 1995: 124-31.
17. Al Ruhaimi KA. Comparison of different distraction rates in the mandible: An experimental investigation. *Int J Oral Maxillofac Surg* 2001;30:220-6. doi: 10.1054/ijom.2001.0046
18. Ilizarov GA. Clinical application at the tension-stress effect for limb lengthening. *Clin Orthop* 1990;250:8-17. doi: 10.1097/00003086-199001000-00003
19. Tavakoli K, Stewart KJ, Poole MD. Distraction osteogenesis icraniofacial surgery; A review. *Ann Plast Surg* 1998;40:88-99. doi: 10.1097/0000637-199801000-00020
20. Karaharju-Suvanto T, Peltonen J, Karaharju EO. Distraction osteogenesis of the mandible. *J Oral Maxillofac Surg* 1992;21:118-21. doi: 10.1016/S0901-5027(05)80547-8
21. Al-Mahdi AH, Al-Jumaily HA. Clinical evaluation of distraction osteogenesis in the treatment of mandibular hypoplasia. *J Craniofac Surg* 2013;24:e50-7. doi: 10.1097/SCS.0b013e3182700223
22. Yasui N, Kojimoto H, Sasaki K, et al. Shimizu H, Shimomura Y. Factors affecting callus distraction in limb lengthening. *Clin Orthop Rel Res* 1993;293:55-60. doi: 10.1097/00003086-199308000-00008
23. Gil-Albarova J, de Pablos J, Franzeb M, et al. Delayed distraction in bone lengthening. Improved healing in lambs. *Acta Orthop Scand* 1992;6:604-6. doi: 10.1080/17453679209169717
24. Cope JB, Samchukov ML, Cherkashin AM. Craniofacial distraction osteogenesis. In: Samchukov ML, Cope JB, Cherkashin AM, editors. *Historical Development and Evolution of Craniofacial Distraction Osteogenesis*. Missouri: Mosby, 2001;3-18.
25. Ross MH, Romrell LJ, Kaye GI, (editors). *Histology A Text and Atlas*. 3rd Edition. Philadelphia: Lippincott, Williams and Wilkins, 1995:132-48.
26. Goode RL. Bone and cartilage grafts: Current concepts. *Otolaryngol Clin North Am* 1972;5:447-55.
27. Donald PJ, Col A. Cartilage implantation in head and neck surgery: Report of a national survey. *Otolaryngol Head and Neck Surg* 1982;90:85-9.
28. Brown DL, Borschel GH (editors). *Michigan Manual of Plastic Surgery*. Philadelphia: Lippincott, Williams and Wilkins, 2004.
29. Kashiwa K, Koyayashi S, Nohara T, et al. Efficacy of distraction osteogenesis for mandibular reconstruction in Previously Irradiated areas: Clinical experiences. *J Craniofac Surg* 2008;19:1571-6.
30. Price DL, Moore EJ, Friedman O, et al. Furutani KM. Effect of radiation on segmental distraction osteogenesis in rabbits. *Arch Facial Plast Surg* 2008;10:159-63. doi: 10.1001/archfaci.10.3.159