

A MODIFIED TECHNIQUE IN INCISIONAL HERNIOPLASTY Case Report

(Received 7 July, 1995)

G. Ögünç, M.D.*

* Assistant Professor, Department of General Surgery, Faculty of Medicine, Akdeniz University, Antalya, Turkey

ABSTRACT

A 61 year old male patient was admitted to hospital with a six month history of a lump in the anterior abdominal wall. The patient was operated with the diagnosis of incisional hernia.

Key Words: Incisional hernia, Mesh, Hernioplasty.

INTRODUCTION

Incisional hernias are very common complications of abdominal surgery. Large incisional hernias do need a prosthesis for a reliable, satisfactory repair. The repair of the incisional hernia may fail unexpectedly. In this report a modification for a large incisional hernioplasty involving both tissue repair and prosthesis application, is described.

CASE REPORT

A 61 year old male patient was admitted to hospital with a 6 month history of a large lump in the anterior abdominal wall and an accompanying pain. Physical examination showed a large incisional abdominal hernia and an old mid-line surgical scar. In acquiring the history of the patient, we learned that he had six operations so far: plication for perforation in the duodenum (in 1966 and 1972), Billroth II gastrectomy (in 1979), appendectomy (in 1984), jejunotomy because of the phytobezoar (in 1993), coronary artery bypass (in 1993).

The patient was operated under general anaesthesia with the diagnosis of incisional hernia. A prophylactic antibiotic therapy was administered before the surgery. A vertical elliptic incision was performed, excising the old scar and an approximately 20 centimetres myoaponeurotic defect in his anterior abdominal wall was exposed. The subcutaneous tissue was dissected from both the sac and the rectus sheaths. An incision was made in both anterior rectus

sheaths about 2 centimetres from medial edges, extending between the xiphoid processes to symphysis pubis (Fig. 1). A new linea alba was reconstructed by continuous suturing (No-1 prolene) together with a strip of fascia from the medial edge of each anterior rectus sheath, as described by Dixon (1) (Fig. 2) This procedure, invested a new form of linea alba without opening the sac and its contents of the abdominal cavity. One closed suction drain was placed on top of the peritoneum. A large suitable size Prolene (polypropylene) prosthesis was implanted freely above the abdominal muscles. Then was sutured with No-1 prolene suture material continuously to the lateral edge of the anterior rectus sheaths roundly (Fig. 3).

This modified operation showed that intraperitoneal organs were highly protected from erosions and adhesions when mesh was placed in the usual way (2).

Two closed suction drains were placed on top of the mesh and then skin and subcutaneous tissue were stitched. Whole operation was performed in 40 minutes. All of the drains were withdrawn when the drainage registered minimum. He, after four days, was released in a good condition. Patient, since then, has been followed and no complication and recurrence has been observed for a year.

DISCUSSION

Incisional hernias are and will continue to be one of the most common complications of abdominal surgical procedures (3). Most small incisional hernias are managed by simple closure of the aponeurotic defect. However when large incisional hernias, however, with aponeurotic defects greater than 10 centimetres are involved, they expose high tendency to recur. Consequently most incisional hernias and all recurrent incisional hernias require a prosthesis for a successful repair (4). Scanning through many prosthetic techniques that have already been described showed no sufficiency in hernioplasty (5).




Fig. 1:
Incising the anterior rectus sheaths.

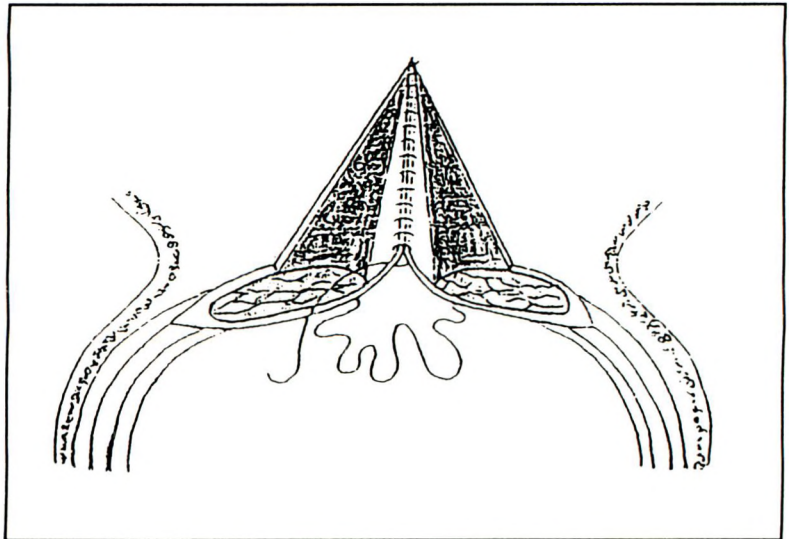


Fig. 2:
Forming a new linea alba.

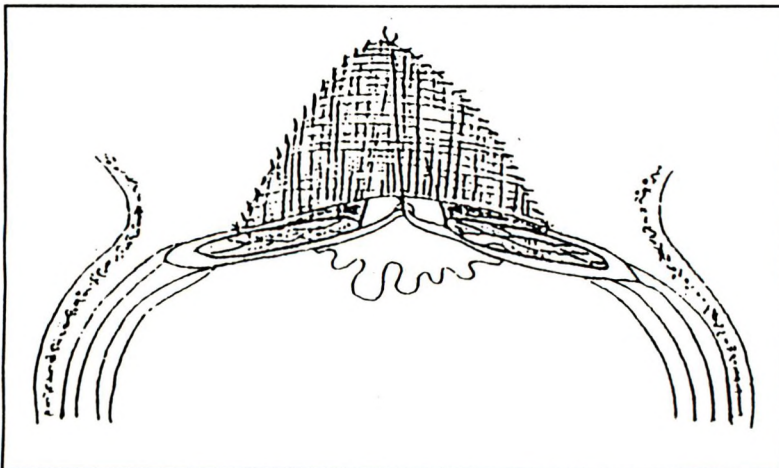


Fig. 3:
Mesh sutured to the lateral edge of the anterior rectus sheaths continuously above the abdominal muscles.

This large incisional abdominal hernia was successfully repaired by a combined technique of incisional hernioplasty with prolene (polypropylene) mesh and tissue repair.

It should also be noted that this modified surgical method described would only be indicated for those with large mid-line incisional abdominal hernias.

REFERENCES

1. Schwartz SI. *Maingot's abdominal operations*. 9th ed. USA: Appleton Lange Prss Inc, 1990:278.
2. Tyrell J, Silberman H, Chandrasoma P, Niland J. Absorbable versus permanent mesh in abdominal operations. *Surg Gynecol Obstet* 1989;168:227-232.
3. Santora TA, Roslyn JJ. Incisional hernia. *Surg Clin North Am* 1993;73:557-569.
4. Schwartz SI. *Principles of surgery*. 6th ed. USA: McGraw-Hill Inc, 1994:1539-1540.
5. Wantz GE. Incisional hernioplasty with mersilene. *Surg Gynecol Obstet* 1991;172:129-137.