

# The Effects of Relationship Between the Mixed Typed of Lingula and Coronoid Process of the Mandible

MİKST TİPTE LİNGULA MANDIBULA İLE PROCESSUS CORONOIDEUS MANDIBULA ARASINDAKİ İLİŞKİNİN ETKİLERİ

 Eren ÖĞÜT<sup>1</sup>,  Fatoş Belgin YILDIRIM<sup>2</sup>

<sup>1</sup> Bahçeşehir Üniversitesi Tıp Fakültesi, Anatomi Anabilim Dalı, İstanbul, TÜRKİYE

<sup>2</sup> Akdeniz Üniversitesi Tıp Fakültesi, Anatomi Anabilim Dalı, Antalya, TÜRKİYE

## ABSTRACT

**Introduction:** This study aimed to identify the variational types of lingula (LM) and coronoid process of the mandible (CPM) in order to determine their relationship and its effect on ethnicity and surgery.

**Methods:** A total of 100 Turkish dry mandibles were measured bilaterally to determine the LM and CPM types. Two-way mixed ANOVA test was used to analyze the relationship between LM and PCM types on both sides, and the chi-square test was used for comparison of categorical variables.

**Results:** The occurrence of Type 4 CPM was 5.5% and type 5 LM was 1.5%. There was a significant difference between the types of LM and CPM ( $\chi^2=48.02$ ,  $p<0.05$ ). The type 5 LM was more frequent with the type 1 CPM on both sides ( $F_{5, 15} = 3.254$ ,  $p=0.04$ ,  $p<0.05$ ), whereas type 4 CPM was more recorded with type 3 and type 5 LM. There were significant difference between the Turkish, Brazilian and Thai populations according to the frequency of the LM types, and between the Turkish and Indian populations according to the frequency of the CPM types ( $p < 0.05$ ).

**Conclusion:** In conclusion, ethnicity might play a role in LM / CPM morphology and explain why different ethnic groups have similar forms. When type 5 LM or type 4 CPM is seen on one side of the ramus, it may indicate that there is more than one variation in that person and give a clue about the individual's ethnicity and effects on surgery.

**Keywords:** Lingula, coronoid process, mandible, skull, bone


## ÖZ

**Giriş:** Bu çalışmanın amacı, varyatif lingula (LM) ve processus coronoideus mandibula (PCM) tipleri arasındaki ilişkiyi ve bunun etnik köken ile cerrahi üzerindeki etkisini araştırmaktır.

**Yöntem:** Lingula Mandibula (LM) ve PCM tiplerinin belirlenmesi için toplam 100 Türk kuru mandibulası bilateral olarak ölçüldü.

## Eren ÖĞÜT

Bahçeşehir Üniversitesi Tıp Fakültesi,  
Anatomi Anabilim Dalı, İstanbul, Türkiye  
E-posta: eren.ogut@med.bau.edu.tr

 <https://orcid.org/0000-0003-2506-9883>

Sağ ve sol tarafta LM ve PCM tipleri arasındaki ilişkinin analizi için iki yönlü ANOVA testi ve kategorik değişkenlerin karşılaştırılması için ki-kare testi kullanıldı.

**Bulgular:** Tip 4 PCM % 5,5 ve tip 5 LM % 1,5 olarak bulundu. Lingula tipleri ile PCM tipleri arasında istatistiksel olarak anlamlı fark saptandı ( $X^2 = 48,02$ ,  $p < 0,05$ ). Tip 5 LM'nin, her iki tarafta da tip 1 PCM ile görülme insidansı daha fazla iken ( $F_{5, 15} = 3,254$ ,  $p = 0,04$ ,  $p < 0,05$ ), tip 4 PCM daha çok tip 3 ve tip 5 LM ile kaydedildi. LM tiplerinin frekansına göre Türk, Brezilya ve Tayland popülasyonlarında, PCM tiplerinin frekansına göre ise Türk ve Hint popülasyonu arasında anlamlı farklılık saptanmıştır ( $p < 0,05$ ).

**Sonuç:** Sonuç olarak etnik köken LM/PCM morfolojisinde rol oynayabilir ve farklı etnik grupların neden benzer formlara sahip olduğunu açıklayabilir. Ramusun bir tarafında tip 5 LM veya tip 4 PCM görülmesi, kişide birden fazla varyasyon olduğunu gösterebilir ve bireyin etnik kökeni ile cerrahi etkileri hakkında bir ipucu verebilir.

**Anahtar Kelimeler:** Lingula, processus coronoideus, mandibula, kafatası, kemik

The lingula mandible (LM) is located on the posterior border of the mandibular foramen and is lodged on the medial aspect of the mandibular ramus (1). The inferior margin of the LM is located at the entry site of the inferior alveolar neurovascular bundles (1). Therefore, the LM is an essential landmark for an inferior alveolar local anesthetic block injection into the medial ramus (2). The coronoid process of the mandible (CPM) is a flat, thin, superior, and anterior projection of the ramus, existing in various shapes and diameters (3). The CPM has an apex, to which a part of the temporal muscle is attached, as well as inserting to its medial surface, and also provides insertion to the anterior fibers of the masseter muscle to the anterior part of its lateral surface (1). Therefore, the function of the muscles is variable depending on morphological differences (1). The definition of the types of LM is of importance as it is often selected as an anatomical reference to provide a ground on the mandibular ramus for a safe and effective approach in mandibular trauma surgery, orthognathic operations, bilateral sagittal split osteotomy, and the various mandibular deformities (4).

Furthermore, the CPM is noteworthy for its utilization as a graft material for the following types of surgery: the reconstruction of orbital floor deformities and alveolar/osseous defect, augmentation of the paranasal

sinuses, repair of mandibular non-union fractures, and craniomaxillofacial surgery. Elongation of the CPM may be detected on one or both sides, resulting in progressive, painless restriction of mandibular opening due to the impingement of the CPM, and treatment involves resection of the CPM (4). The variations and relationships in the types of CPM and LM are of significant importance for oral-maxillofacial surgery. Some anatomical and morphological variations in the types of the LM and CPM have been stated in the literature; (3, 5, 6) however, the type correlation and the effects of ethnicity and the effects on surgical approaches are undetermined (7-9).

### Embryological design

At around the sixth week of fetal life, each half of the mandible is ossified from a single-center, derived from dense fibro-membranous tissue lateral to the inferior alveolar vessels and the lower sections of Meckel's cartilage.(1-10) The CPM is formed from secondary cartilage, which quickly ossifies, emerges in front of the CPM, and then vanishes before birth (1). The accessory nuclei of cartilage occur in the head of the mandible and spread downward through the ramus, a small strip along the anterior border of the CPM, and smaller nuclei in the

front part of both alveolar walls (1, 10). The dermal bone invades these accessory nuclei, causing absorption and a significant reduction in the thickness of the ramus above the LM. The lateral and medial cortical plates can fuse and form the variational types (1, 10). This is of importance in mandibular ramus osteotomies and also influences of the variational types.

### Goals of this study

Little importance has been given to the relationship between the variational types of LM and CPM. Therefore, the present study aimed to analyze the relationship between the types of LM and CPM and the effects of ethnicity, and the effects on surgical management.

## MATERIALS AND METHODS

### Study sample

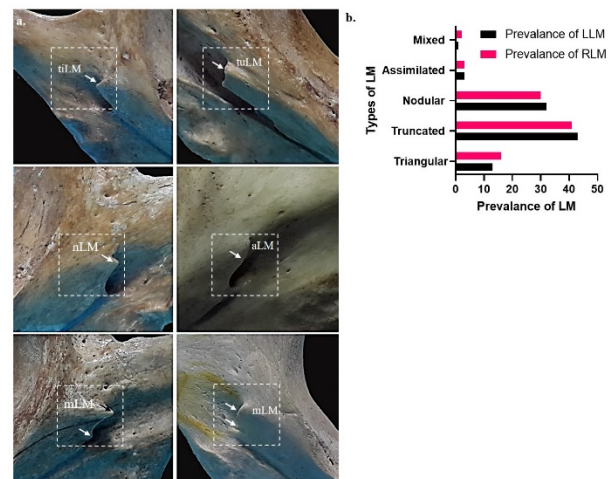
A total of 100 dry mandibles of Turkish skulls were included in the study for defining the types of LM and CPM. The study was carried out at the Department of Anatomy, School of Medicine, Akdeniz University, Antalya, Turkey. It was approved by the ethics committee of Akdeniz University, Antalya, Turkey, on 2 November 2019 with approval number 897/2012-KAEK-20. Both measurements were taken bilaterally, and three commonly used precision estimates were measured to achieve intraobserver precision: technical error of measurement (TEM), relative technical error of measurement (rTEM), and coefficient of reliability (R) (11-13). Eligible mandibles were selected based on strict inclusion and exclusion criteria to obtain the most accurate results. Mandibles were included in the study after they were evaluated as completely ossified, dried, and complete. Thirteen (n) mandibles were excluded from the study because of deformities, fractures, or incompleteness. The morphological characteristics of the CPM and LM and their relationship were evaluated on both sides, and additional types were noted (mixed type LM (mLM, Type 5), and mixed CPM (mCPM, Type 4). The chi-square test was used to analyze the types of LM statistically and CPM detected, and the relationships between the LM

and CPM were analyzed by two-way mixed ANOVA.  $p < 0.05$  was accepted as statistically significant.

### The types of LM were categorized as follows

Triangular LM (tiLM, Type 1), stands on a broad base with a narrow, pointed tip, extending posterosuperiorly towards the mandibular condyle and the posterior border of the mandibular ramus. As seen in Fig. 1, both margins of the tiLM are unattached.

**Figure 1.** Types of lingula mandible **a.** triangular lingula (tiLM) (white arrow), thin-rounded structure with a pointed tip stands on a wide base, with its apex extending superior-posteriorly towards the mandibular condyle and posterior margin of the mandible; truncated lingula (tuLM) (white arrow), the superior, inferior and posterior borders form a tetragonal shaped top; nodular lingula (nLM) (white arrow), the nodular shape, excluding its apex, is unified inside the mandibular ramus; assimilated lingula (aLM) (white arrow), this is completely contained in the mandibular ramus; mixed lingula (mLM) (white arrow), this has variable size and shape, and has more than one tip **b.** prevalence of types of LM (%), the prevalence of LLM (%) (LLM: Left Lingula Mandible) and prevalence of RLM (%) (RLM: Right Lingula Mandible)



Truncated LM (tuLM, Type 2), Fig. 1 indicates that the upper part is quadrangular as formed by the configuration and alignment of its superior, inferior and posterior borders. Nodular LM (nLM, Type 3), This has

only as a nodular apex and is wholly integrated with the mandibular ramus (Fig.1).

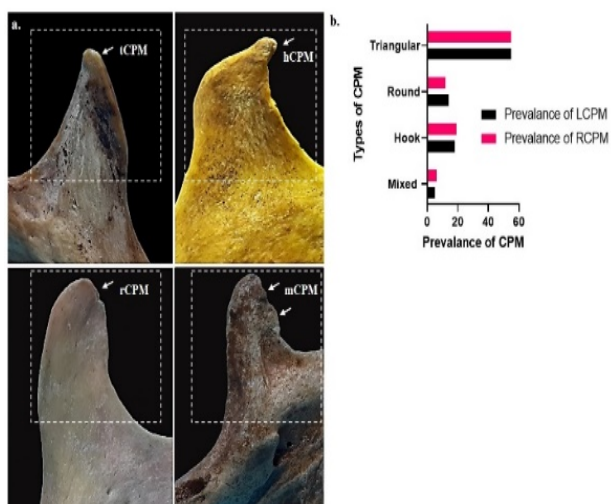
Assimilated LM (aLM, Type 4), As seen in Fig. 1, it is completely integrated with the mandibular ramus.

Mixed type LM (mLM, Type 5), Fig. 1 indicates that mLM is defined by variable size and shape and by having more than one tip.

### The types of CPM were categorized as follows

Triangular CPM (tCPM, Type 1), characterized by a pointed apex, and anteroposterior borders of the structure which are straight and without notches (Fig. 2).

**Figure 2.** Types of coronoid process of mandible **a.** triangular CPM (tCPM, Type 1) (white arrow); as the hook-shaped type of CPM (hCPM, Type 2) (white arrow), was the most variable type in shape, it was further subclassified according to its base and the proximity of the notch to the apex; round CPM (rCPM, Type 3) (white arrow); mixed CPM (mCPM, Type 4) (white arrow), which did not conform to any of the definitions, were categorized as the mixed type **b.** prevalence of types of CPM (%), the prevalence of LCPM (%) (LCPM: Left coronoid processes of mandible), the prevalence of RCPM (%) (RCPM: Right coronoid processes of mandible)



Hook-shaped CPM (hCPM, Type 2), with a pointed apex and a notch, but the anterior and posterior margins are respectively convex and concave (Fig. 2). Round CPM (rCPM, Type 3), with a rounded apex and anteroposterior borders, which are straight and without notches (Fig. 2).

Mixed CPM (mCPM, Type 4), which does not conform to any of the above definitions and are referred to as a mixed type (Fig. 2).

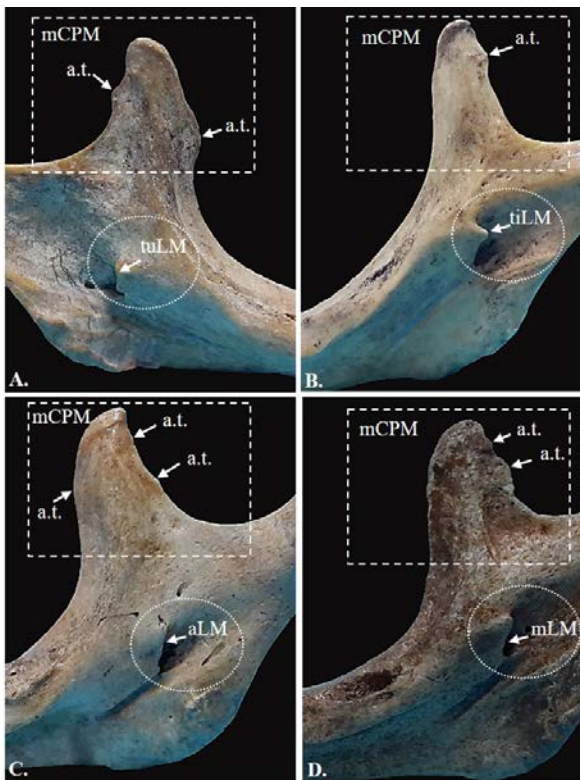
### Statistical Analysis

SPSS 25.0 (IBM SPSS Statistics 25, USA) was used for all statistical analyses. Descriptive statistics of continuous variables are given with mean and standard deviation, frequency and percentage for categorical variables. The two-way mixed ANOVA test was used for the relationship between the types of LM and CPM on both sides. A chi-squared test was used for the comparison of categorical variables. For all statistical comparisons,  $p < 0.05$  was assumed to indicate statistical significance.

### RESULTS

The coefficient of reliability (R) values of most of these variables were close to 1, suggesting that most of the variation in the variables in the sample was due to factors other than measurement error. These results suggest that an acceptable degree of intra-observer precision was obtained for the measurements. It was inferred from the present study that the variational types of the coronoid process of the mandible (mCPM) and the lingula of the mandible (mLM) refer to a mixed type (Fig. 1-3).

**Figure 3.** The mixed CPM (mCPM, Type 4) type along with LM **a.** mCPM - tuLM (truncated lingula) (white arrow) **b.** mCPM - tiLM (triangular lingula) (white arrow) **c.** mCPM - aLM (assimilated lingula) (white arrow) **d.** mCPM - nLM (nodular lingula) (white arrow), a.t. accessory tubercle (white arrow)



As seen in Fig. 1, our results demonstrated five different types of LM: the triangular, truncated, nodular, assimilated, and mixed types. As seen in Fig. 2, we also demonstrated four types of CPM: the triangular, round, hook, and mixed types. The present study revealed that the truncated type was the most frequent lingula type (type 2 LM); *left*,  $43 \pm 0.7$  (47%); *right*,  $41 \pm 0.7$  (45%) in the 100 dried mandibles. As seen in Fig. 1, triangular and mixed lingula types were more frequent on the right side, while truncated and nodular type were more frequent on the left ( $p < 0.05$ ). Fig. 1 indicates that the most frequent LM type on both sides was the truncated (type 2 LM); *left*,  $43 \pm 0.7$  (47%); *right*,  $41 \pm 0.7$  (45%), followed by the nodular (type 3 LM); *left*,  $32 \pm 1.4$  (35%), *right*,  $30 \pm 1.4$  (33%), triangular (type 1 LM); *left*,  $13 \pm 2.12$  (14%), *right*,  $16 \pm 2.12$  (17%), assimilated (type 4 LM);  $3 \pm 0.1$  (3%) and mixed types (type 5 LM); *left*,  $1 \pm 1.41$  (1%), *right*,  $2 \pm 1.41$  (2%). The most prevalent CPM type was the triangular (type 1 CPM) on both sides,  $55 \pm 0.1$  (60%) in the 100 dried mandibles.

As seen in Table 1, the most frequent CPM type was the triangular type (type 1 CPM),  $55 \pm 0.1$  (60%) followed by the hook (type 2 CPM), *left*,  $18 \pm 0.7$  (20%), *right*,  $19 \pm 0.7$  (21%), round (type 3 CPM), *left*,  $15 \pm 1.41$  (14%), *right*,  $12 \pm 1.41$  (13%) and mixed types (type 4 CPM), *left*,  $5 \pm 0.7$  (5%), *right*,  $6 \pm 0.7$  (6%).



**Table 1.** The type incidence of coronoid process in dry mandibles of populations by the year

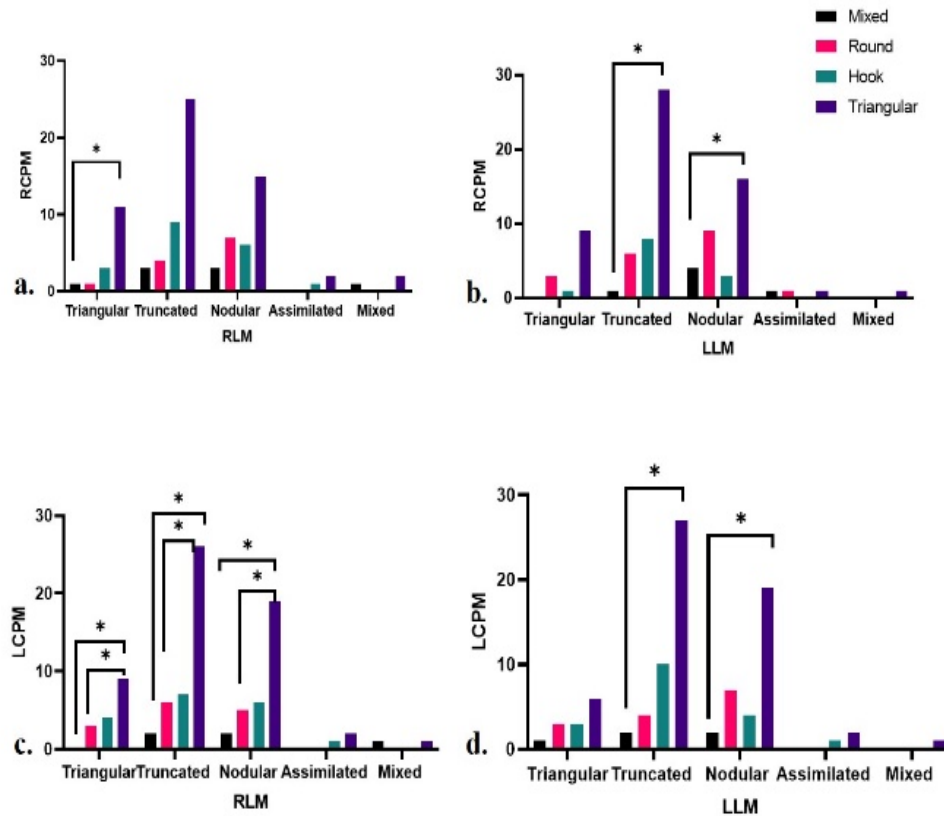
Coronoid process of mandible (CPM)	Total number	Study Design	Population	Years	Hook Type (%)	Triangular (%)	Rounded (%)	Mixed (%)
Isaac et al.	157	Dry mandible	Indian	2001	27.4	49	23.6	
Prajapati et al.	120	Dry mandible	Western Indian	2011	21.25	54.17	24.58	
Khan et al.	200	Dry mandible	South Indian	2011	30	67	3	
Hossain et al.	189	Dry mandible	Indian	2011	45	29.65	25.35	
Tanveer et al.	200	Dry mandible	South Indian	2011	30	67	3	
Nirmale et al.	84	Dry mandible	Indian	2012	28	65	7	
Bakırcı et al.	97	Dry mandible	Byzantin	2013	64	15.7	20.2	
Desai et al.	100	Dry mandible	Indian	2014	24	68	8	
Pradhan et al.	92	Dry mandible	Eastern Indian	2014	17.93	46.73	35.3	
Bhaphor et al.	198	Dry mandible	Indian	2015	45	29.65	25.35	
Subbaramaiah et al.	100	Dry mandible	Indian	2015	61.5	14	12	
Mouna et al.	100	Dry mandible	Indian	2015	61.5	14	12.5	
Sanmugam et al.	100	Dry mandible	Indian	2015	27	49	24	
Parveen et al.	264	Dry mandible	Indian	2018	21.97	66.10	11.93	
Soman et al.	100	Dry mandible	Indian	2018	45	23	32	
Kausar et al.	110	Dry mandible	Indian	2020	29	60	11	
Agnihotri et al.	500	Dry mandible	Indian	2020	12	42	46	
Present study	100	Dry mandible	Turkish	2020	18.5	55	13	5.5*

As seen in Fig. 4, the truncated type was the most frequent left LM type in 28 (65%) mandibles, independently from the CPM. As seen in Fig. 2, the hook and mixed CPM types were more frequent on the right, whereas the round CPM was more frequent type on the left ( $p < 0.05$ ). The chi-

square test showed a significant difference between the types of left LM and left CPM ( $X^2 = 73.85$ ,  $p < 0.001$ ). The occurrence of the nodular and truncated types of left LM was significantly higher with the triangular type of CPM on the left side as shown in Fig. 4 ( $F_{3,15} = 6.041$ ,  $p = 0.02$ ,  $p < 0.05$ ).

As seen in Fig. 4, the triangular CPM (tCPM) was observed in all mixed LM types on both sides. The chi-square test

showed that there was a significant difference between the types of the *right* LM and the *right* CPM ( $X^2= 62.90, p<0.001$ ).



**Figure 4.** The relationship between the types of coronoid process and lingula of mandible according to the body side **a.** The relationship between the RCPM/RLM and **b.** the relationship between the RCPM/LLM. Prevalence of LM (types of LM: triangular, truncated, nodular, assimilated, mixed lingula) and RCPM (%) (types of right coronoid processes of the mandible: triangular, hook, round, mixed) RLM. **c.** The relationship between the LCPM/RLM and **d.** the relationship between the LCPM/LLM. Prevalence of RLM and LLM (%) (types of lingula mandible: triangular, truncated, nodular, assimilated, mixed lingula) and LCPM (types of left coronoid processes of the mandible: triangular, hook, round, mixed) (LCPM: Left coronoid processes of mandible, LLM: Left Lingula Mandible, RLM: Right Lingula Mandible, RCPM: Right coronoid processes of mandible).

The triangular right CPM was more seen with the triangular right LM ( $F_{5, 15} = 3.126, p=0.03, p<0.05$ ). The chi-square test showed that there was no significant difference between the types of the *left* LM and *right* CPM ( $X^2= 17.37, p=0.297, p>0.05$ ); however, the *left* tuLM was frequently found related with the *right* tiCPM ( $F_{5, 15} = 2.955, p = 0.0472,$

$p<0.05$ ). The chi-square test showed a significant difference between the types of the *right* LM and *left* CPM ( $X^2= 48.02, p<0.001$ ). Mixed right LM was the most frequent type with a left tiCPM ( $F_{5, 15} = 3.254, p=0.04, p<0.05$ ). There was a relationship between the round CPM (rCPM) and mixed CPM (mCPM) related to the nodular LM (nLM) on the

right side, as shown in Table 3, The mCPM was also related to the mLM on both sides. As seen in Fig. 4 hCPM was a less detected type with the left mLM and nLM types.

## DISCUSSION

### Ethnicity

The significance of the relationship and types of LM/CPM in determining an individual's ethnicity is debatable, and no study on the subject has been released. The tuLM is more frequent in Thai (14), Brazilian, and Turkish dry mandibles, while the tiLM is more frequent in North Indian (15) and Bangladeshi (16) dry mandibles (Table 2).

**Table 2.** The type incidences of mandibular lingula (LM) in populations by the year

<i>Lingula Mandible (LM)</i>	<i>Total number</i>	<i>Study Design</i>	<i>Years</i>	<i>Population</i>	<i>Triangular</i>	<i>Truncated</i>	<i>Nodular</i>	<i>Assimilated</i>	<i>Mixed</i>
<i>Tuli et al.</i>	165	Dry mandible	2000	<b>Indian</b>	68,5	15.8	10.9	4.8	
<i>Hossain et al.</i>	208	Dry mandible	2001	<b>Bangladeshi</b>	70.2	20.2	-	9.6	
<i>Kositbowornchai et al.</i>	72	Dry mandible	2007	<b>Thai</b>	16.7	47.2	22.9	13.2	
<i>Jansisyanont et al.</i>	92	Dry mandible	2009	<b>Thai</b>	29.9	46.2	19.6	4.3	
<i>Lopes et al.</i>	80	Dry mandible	2010	<b>South Brazilian</b>	41.3	36.3	10.5	11.9	
<i>Nirmale et al.</i>	84	Dry mandible	2012	<b>Indian</b>	47.67	10.71	27.97	13.69	
<i>Murlimanju et al</i>	67	Dry mandible	2012	<b>South Indian</b>	29.9	27.6	29.9	12.6	
<i>Samanta et al.</i>	60	Dry mandible	2013	<b>North Indian</b>	61.6	46.6	31.6	11.6	
<i>Gupta et al.</i>	102	Dry mandible	2014	<b>North Indian</b>	50	33.82	11.76	2.9	
<i>Sanmugam et al.</i>	100	Dry mandible	2015	<b>Indian</b>	49	26	7	19	
<i>Alves et al</i>	132	Dry mandible	2015	<b>Brazilian</b>	23.3	49	26.5	1.2	
<i>Jung et al</i>	347	CBCT	2018	-	14.3	29.3	54	2.4	
<i>Present study</i>	100	Dry Mandible	2020	<b>Turkish</b>	14.5	42	31	3	<b>1.5*</b>



**Table 3.** Means, Standard Deviations, and Two-Way Analyses of Variance in the relationship between the types of lingula and coronoid process of the mandible (LM=lingula mandible, CPM=coronoid process of mandible, R=right, L=left)

	Types	Mean	SD	q	p	F
<b>RCPM-RLM</b>	" Mixed - Round"	2.400	2.490	0.4544	0.9880	$F(4, 12) =$
	" Mixed - Hook"	3.800	2.490	1.250	0.8134	4.632
	" Mixed -Triangular"	11.00	2.490	5.339	0.0122*	$p=0.0171^*$
	" Round - Hook"	3.800	2.490	0.7951	0.9414	
	" Round -Triangular"	11.00	2.490	4.884	0.0215*	
<b>RCPM-LLM</b>	" Mixed - Round"	3.800	3.104	1.185	0.8357	$F(4, 12) =$
	" Mixed - Hook"	2.400	3.104	0.5468	0.9794	3.527
	" Mixed -Triangular"	11.00	3.104	4.465	0.0360*	$p=0.0400^*$
	" Round - Hook"	2.400	3.104	0.6379	0.9682	
	" Round -Triangular"	11.00	3.104	3.281	0.1478	
	" Hook -Triangular"	11.00	3.104	3.919	0.0702	
<b>LCPM-RLM</b>	" Mixed - Round"	2.800	2.849	0.8935	0.9198	$F(4, 12) =$
	" Mixed -Hook"	3.600	2.849	1.291	0.7987	3.717
	" Mixed -Triangular"	11.40	2.849	5.162	<b>0.0152*</b>	$p=0.0343^*$
	" Round - Hook"	3.600	2.849	0.3971	0.9919	
	" Round - Triangular"	11.40	2.849	4.269	<b>0.0459*</b>	
	" Hook -Triangular"	11.40	2.849	3.872	0.0743	
<b>LCPM-LLM</b>	" Mixed - Round"	2.800	3.089	0.8242	0.9354	$F(4, 12) =$
	" Mixed -Hook"	3.600	3.089	1.190	0.8337	3.562
	" Mixed -Triangular"	11.40	3.089	4.579	0.0313*	$p=0.0389^*$
	" Round - Hook"	3.600	3.089	0.3663	0.9936	
	" Round - Triangular"	11.40	3.089	3.755	0.0854	
	" Hook -Triangular"	11.40	3.089	3.388	0.1309	

Two Way ANOVA \*\*\* $p < .00$

In the present study, as seen in Table 1 and Table 2, there are some similarities in Turkish, Brazilian (17, 18), and Thai dry mandibles according to the occurrence of types of LM and also a significant similarity between Turkish and Indian individuals relating to the frequency of CPM ( $p < 0.05$ ). Ethnicity can influence the morphology of the LM/CPM, also explain why different ethnic populations have similar forms. As seen in Table 2, the observed types of LM vary across different populations and ethnicities (19, 20). Tuli *et al.* (19) have previously defined the types of LM based on the results of a study scrutinizing a total of 165

Indian mandibles, which defined four types of LM, which were triangular, truncated, nodular, and assimilated. Besides those four types, our results revealed an additional LM (type 5) in Turkish dry mandibles, which we refer to as the *mixed type*. Senel *et al.* (20) reported that the most frequent types were nodular, followed by assimilated, triangular, and truncated. Samanta *et al.* (2), Tuli *et al.* (19), Gupta *et al.* (15) reported that the most frequent type of LM was triangular, and the least one was assimilated in Indian populations. Similarly, Nirmale *et al.* (21) found that the most frequent Indian LM type was triangular, and the least

frequent type was truncated. As seen in Table 2, Sanmugam *et al.* (6) and Lopes *et al.* (18) found that the triangular type was the most frequent, followed by the truncated, assimilated, and nodular types of both Indian and Brazilian populations. Contrary to these findings, Kositbowornchai *et al.* (22) and Alves *et al.* (17) conducted a study that analyzed dried mandibles, reporting that the most frequent LM type was the truncated type. This was followed by the nodular, triangular, and assimilated types in Thai and Brazilian populations. Similarly, Devi *et al.* (23) reported that the most frequent LM was the truncated type, while Murlimanju *et al.* (7) and Hossein *et al.* (16) found that was triangular type in south Indian and Bangladesian populations, respectively. Jansisyantont *et al.* (14) evaluated a total of 92 mandibles and reported that the most frequent LM type was truncated, and the least frequent type was assimilated in Thai populations. Jung *et al.* (24) analyzed CBCT and reported that the most frequent type was nodular followed by the truncated, triangular, and assimilated types. However, the findings of the current study indicated that the most frequent lingula type was truncated (type 2 LM), followed by nodular (type 3 LM), triangular (type 1 LM) and assimilated (type 4 LM) in Turkish dry mandibles (Table 2). This inconsistency could occur during the embryologic developmental process of the ramus mandible. In addition to these types, we concluded that an additional LM type needs to be referred to as the mixed LM (type 5).

As seen in Table 1, Isaac *et al.* (25), Parween *et al.* (3), Sanmugam *et al.* (6), Nirmale *et al.* (21) reported that there were three types of CPM, triangular, hook, and round; the most frequent type was the triangular type, and the least frequent was the round type in Indian populations. Prajapati *et al.* (26) and Pradhan *et al.* (5) stated that the triangular type was the most frequent, while the least frequent was the hook type in western and eastern Indians. Nirmale *et al.* (21) analyzed 84 dry mandibles and reported that the hook CPM was the most frequent type in both genders and that the triangular type was more frequent in Indian males. Sanmugam *et al.* (6) investigated the various types of LM and CPM and reported that the triangular type was the most frequent type both in the LM and the CPM in Indian populations. Kausar *et al.* (27) stated

that the triangular type was the most frequent, while the least frequent was the round type in Indian populations. Our results confirmed the findings of Parveen *et al.* (3) according to the prevalence of the CPM types except for the mixed type. In our study revealed that the most frequent CPM type was triangular (type 1 CPM), followed by hook (type 2 CPM), round (type 3 CPM), and mixed (type 4 CPM) in Turkish dry mandibles (Table 2). However, Agnihotri *et al.* (28) reported the types of CPM were round (46%), triangular (42%) and hook in Indian populations. Furthermore, Bakırcı *et al.* (29) and Subbaramaiah *et al.* (30) reported that the most frequent CPM type was the hook; the triangular and round types followed them in Byzantian and Indian populations respectively (as seen in Table 1). However, there is no adequate data in the literature related to the mixed types of LM/CPM and relationship between them. Isaac *et al.* (25) stated the occurrence of several CPM types in Indian mandibles, including the rectangular and flattened types. The mixed type of CPM and LM needed to be taken into account in the literature as an additional type, also referred to as a type 4 CPM and type 5 LM. Ethnicity can influence the morphology of the LM/CPM, also explain why different ethnic populations have similar forms.

### Surgery

The data in Fig. 3 shows the occurrence of a mixed type of CPM and its close relationship with the types of LM. In order to perform the planned operation correctly, it is essential to know the relationships of the LM and CPM in order to decrease the risk of surgery. However, there is a paucity of knowledge in the literature about the mixed types of LM/CPM and the surgical approaches used to treat them. The variational types of LM and CPM can be identified using a blunt nerve hook to detect and conserve the branches of the inferior alveolar nerve (4). Hsu *et al.* (31) reported that the location of the LM and its relationship with the types of skeletal patterns were essential for ramus surgery to avoid excessive hemorrhage and lower lip numbness during surgery. Jung *et al.* (24) claimed a relationship between the types of LM and mandibular ramus, and therefore tiLM was lodged more superoposterior than other types. When the mixed type of

CPM is seen on one side of the ramus, this may also demonstrate that the other mixed type of LM is more frequent on the same side. Therefore, it is crucial to take into account the relationship between the mixed types when performing mandibular ramus surgery. This finding also shows that there can be more than one variation in the same individual. Therefore, this relationship can be used as a surgical landmark to preserve the related anatomical structures in order to provide a predictable and stable outcome with no further nerve damage. Nirmale *et al.* (21) stated the variations in the types of CPM. They reported that several factors were involved in the occurrence of types, including functional differences in muscle tone-related activities, the action of chewing, the effects of hormones, genetic factors, and dietary habits (21).

The morphological type of CPM is also critical, as certain types are associated with a narrow vestibular space (27). Since the medial surface of the CPM is closely adjacent to the distal molars, a narrow vestibular space may lead to a limited mouth opening and restrictions in the mobility of the mandible (27). Jung *et al.* (24) stated that the tip of the LM was occurred at the same level as the coronoid notch (75.3%) and above the coronoid notch in 66.6%.

Furthermore, they alleged that significant differences were detected between the deepest point of the coronoid notch and the LM (24). Studies evaluating the morphological features of LM have reported that variations were associated with insufficient blockade of the inferior alveolar nerve (28). Understanding the CPM and LM in various populations is expected to assist the clinician in reconstructive procedures such as orbit floor, alveolar defects, paranasal sinus augmentation, non-union fracture mandible, osseous defects reconstruction, and other procedures (28). For that reason, the types of CPM and LM should be meticulously identified as they provide beneficial parameters for dental, orofacial, and mandibular surgery by enabling the performance of productive anesthesia and by preventing the development of intraoperative complications such as bleeding and nerve injuries (4). The preoperative knowledge of the mixed types of LM and CPM and related surgical approaches prevents nerve injury and compression of the nearby vessels. The findings of this study gave us a better understanding of

how to identify mixed types of LM/CPM before and during surgery and effects of ethnicity.

## LIMITATIONS

This study was performed only on Turkish dry mandibles; therefore, further large-scale studies are needed to investigate the effects of ethnicity on the relationship between the lingula and coronoid process of the mandible. The intraoperative imaging modalities are also beneficial to detect the relationship between them.

## CONCLUSION

According to the current study's findings, ethnicity may play a role in the morphology of the LM/CPM, and it may explain why different ethnic groups have similar forms. When a mixed type of LM or CPM is seen on one side of the ramus, this may also indicate that there is more than one variation in the same individual and give us a clue about an individual's ethnicity and effects on the surgery.

## REFERENCES

1. Standring S, Anand N, Birch R, et al editors. Gray's Anatomy. 41th ed. London:UK. Elsevier; 2016.
2. Samanta P, Kharb P. Morphological analysis of the lingula in dry adult human mandibles of north indian population. *Journal of Cranio-Maxillary Diseases*. 2012;1(1):7-11.
3. Parveen S, Akhtar J, Kumar S, Kumar A, Kumar V. Morphological study of coronoid process of adult human dry mandibles. *JMSCR*. 2018;6(4):155-161.
4. Naini FB, Daljit SG, editors. *Orthognathic Surgery: Principles, Planning and Practice*. 1th ed. London:UK. Wiley-Blackwell; 2017.
5. Pradhan S, Bara DP, Patra S, Nayak S, Mohapatra C. Anatomical study of various shapes of mandibular coronoid process in relation to gender & age. *Journal of Dental and Medical Sciences*. 2014;13(8):09-14.
6. Sanmugam K. A study of morphological variation of lingula and coronoid process of adult human

- dry mandibles. *Journal of Pharmaceutical Sciences and Research*. 2015;7:1017-20.
7. Murlimanju BV, Prabhu LV, Pai MM, Paul MT, Saralaya VV, Kumar CG. Morphological study of lingula of the mandibles in south indian population. *Morphologie*. 2012;96(312):16-20.
  8. Smith BR, Rajchel JL, Waite DE, Read L. Mandibular ramus anatomy as it relates to the medial osteotomy of the sagittal split ramus osteotomy. *J Oral Maxillofac Surg*. 1991;49(2):112-6.
  9. Tom WK, Martone CH, Mintz SM. A study of mandibular ramus anatomy and its significance to sagittal split osteotomy. *Int J Oral Maxillofac Surg*. 1997;26(3):176-8.
  10. Hollinshead WH, editor. *Textbook of Anatomy*. 1th ed. Calcutta:India. Harper & Row; 1962.
  11. Sekerci R, Ogut E, Keles-Celik N. The influences of forus acusticus internus on ethnicity and importance in preoperative and intraoperative approaches. *Surg Radiol Anat*. 2021 Mar 30: s00276021027416. [Epub ahead of print].
  12. Ogut E, Armagan K, Barut C. Reappraisal of the types of trigeminal forus and importance in surgical applications. *Surg Radiol Anat*. 2021 Jan 5:s0027602002651z. [Epub ahead of print].
  13. Akdag UB, Ogut E, Barut C. Intraforaminal dural septations of the jugular foramen: a cadaveric study. *World Neurosurgery*. 2020;141:e718-e27.
  14. Jansisyanont P, Apinhasmit W, Chompoopong S. Shape, height, and location of the lingula for sagittal ramus osteotomy in thais. *Clinical Anatomy*. 2009;22(7):787-93.
  15. Gupta S. Morphological analysis of the lingula in dry mandibles of individuals in north india. *IOSR Journal of Dental and Medical Sciences*. 2014;13(1):04-6.
  16. Hossain SMA, Patwary SI, Karim M. Variation in shape of the lingulae in the adult human mandible of bangladeshi skulls Pakistan Journal of Medical Sciences. 2001;17:233-6.
  17. Alves N, Deana N. Analysis of the lingula shapes in macerated mandibles of brazilian individuals. *International Journal of Morphology*. 2016;34:42-8.
  18. Lopes PTC, Pereira GAM, Santos AMPV. Morphological analysis of the lingula in dry mandibles of individuals in southern brazil. *Journal of Morphological Sciences*. 2010;27(3-4):136-138.
  19. Tuli A, Choudhry R, Choudhry S, Raheja S, Agarwal S. Variation in shape of the lingula in the adult human mandible. *Journal of Anatomy*. 2000;197(2):313-7.
  20. Senel B, Ozkan A, Altug HA. Morphological evaluation of the mandibular lingula using cone beam computed tomography. *Folia Morphol*. 2015;74(4):497-502.
  21. Nirmale VK, Mane UW, Sukre SB, Diwan CV. Morphological features of human mandible. *International Journal of Recent Trends in Science and Technology*. 2012;3(2):38-43.
  22. Kositbowornchai S, Siritapetawee M, Damrongrungruang T, Khongkankong W, Chatrchaiwiwatana S, Khamanarong K, et al. Shape of the lingula and its localization by panoramic radiograph versus dry mandibular measurement. *Surg Radiol Anat*. 2007;29(8):689-94.
  23. Devi R, Arna N, Manjunath KY, Balasubramanyam A. Incidence of morphological variants of mandibular lingula. *Indian J Dent Res*. 2003;14(4):210-3.
  24. Jung YH, Cho BH, Hwang JJ. Location and shape of the mandibular lingula: Comparison of skeletal class I and class III patients using panoramic radiography and cone-beam computed tomography. *Imaging Sci Dent*. 2018;48(3):185-90.
  25. Isaac B, Holla S. Variations in the shape of the coronoid process in the adult human mandible. *J Anat Soc India*. 2001;50:137-9.
  26. Prajapati V, Malukar O, Nagar SK. Variations in the morphological appearance of the coronoid process of human mandible. *National Journal of Medical Research*. 2011;1:64-6.

27. Kausar H, Tripathi A, Raizaday S, Bharti S, Jain S, Khare S, et al. Morphology and morphometry of coronoid process of dry mandible-a comprehensive study. *Journal of Evidence Based Medicine and Healthcare*. 2020;7:773-6.
28. Agnihotri G, Kahlon S. Variations in mandibular coronoid process-a morphometric treatise. *Journal of Dental Specialities*. 2020;8(1):9-12.
29. Bakirci S, Ari I, Kafa I. Morphometric characteristics and typology of the coronoid process of the mandible. *Acta Med Mediterr*. 2013;29:683-6.
30. Subbaramaiah M, Bajpe R, Jagannatha SR, Jayanthi KS. A study of various forms of mandibular coronoid process in determination of sex. *Indian J Clin Anat Physiol*. 2015;2(4).
31. Hsu KJ, Tseng YC, Liang SW, Hsiao SY, Chen CM. Dimension and location of the mandibular lingula: comparisons of gender and skeletal patterns using cone-beam computed tomography. *Biomed Res Int*. 2020 Feb 13:2571534. [Epub ahead of print].