



Electrocardiographic Analysis of ST-Segment Duration and Morphology in Sheep and Goats: Effect of Species, Breed, Age and Sex

Amir Saeed SAMIMI^{1*}, Javad TAJIK¹, Seyyed Morteza AGHAMIRI¹, Talieh TAHERI¹

¹Department of Clinical Studies, School of Veterinary Medicine, Shahid Bahonar University of Kerman, Iran

*Sorumlu Yazar /
Corresponding Author:

Amir Saeed SAMIMI
e-mail: amirsamimi90@yahoo.com

Geliş Tarihi / Received:
30 April 2016

Kabul Tarihi / Accepted:
09 August 2016

Key Words:
Age, breed, electrocardiographic
analysis, goat, sex, sheep, ST-
segment

Abstract

The importance of obtaining normal values of ST-segment for specific breeds of animals besides the high variability of indices in small ruminant has been emphasized. The animals were assigned into 4 groups (G₁₋₄), according to their age: G₁<3 months, 3 months ≤G₂< 1 year, 1 year ≤G₃<3 years, and G₄ ≥ 3 years old. There were 34 animals in each study group. The animals were assigned to two comprising groups: sheep, goat, male and female. Also, the animals were divided into three groups according to their breed, including: Kermani sheep, Saanen and Cashmere (Raini) goats. The present study showed that sex, age and breed had no effect on ST-segment in sheep and goats and the obtained data can provide a good basis for judging the ST-segment length and morphology in difference sexes, breeds and age groups of sheep and goats.

Introduction

Electrocardiograph (ECG) prepares different records of the times that occur over the surface of the body as the result of electrical activity within the heart. This is associated with depolarization and repolarization of the myocardium that occurs in a definite pattern (Pourjafar et al., 2012; Radostits et al., 2007).

In human, ECG analysis of ST-segment has been used as a diagnostic method in some of the cardiac and non-cardiac diseases (Chalmeh et al., 2014; Gertsch, 2009; Häggmark et al., 2005). Elevation and depression of this segment in patients represent disorders such as cardiac ischemia and infarction, electrolyte imbalances, electrical conduction abnormalities, and cardiac structure and valves problems (Gertsch, 2009; Häggmark et al., 2005; Li et al., 1998). However, little is known regarding the ST-segment in animals. Knowledge of the normal duration and pattern of ST-segment may help in the diagnosis of diseases using ECGs.

The importance of obtaining normal values of ST-segment for specific breeds of animals besides the high variability of indices in small ruminant has been

emphasized (Escudero et al., 2009; Fakour et al., 2013; Mohan et al., 2005; Tajik et al., 2013). However, there are only a few previous studies about the normal reference values of ST-segment in clinically healthy small ruminant (Balikci and Yildi, 2006; Radostits et al., 2007; Pogliani et al., 2013). The present study was undertaken to evaluate the probable effects of sex, age, species and breed on duration and morphology of ST-segment in base apex lead ECG in sheep and goats.

Materials and Methods

The present study was carried from October 2013 to October 2014 on 135 clinically apparently healthy sheep and goats in Kerman province, Southeast of Iran (latitude 30°19'N and longitude 52°07'E). The animals were assigned into 4 groups (G₁₋₄), according to their age: G₁<3 months, 3 months ≤G₂< 1 year, 1 year ≤G₃<3 years, and G₄ ≥3 years old. There were 34 animals in each study group. The animals were assigned to two comprising groups: sheep, goat, male and female. Also, the animals were divided into three groups according to their breed, including: Kermani sheep (average weight of 41.2±2.25 kg), Saanen (average weight of 30.2±2.20 kg)

and Cashmere (Raini) goats (average weight of 32.2 ± 2.15 kg). The animals were examined prior to ECG recordings. None of the animals used in this study had any clinical signs of heart diseases.

The ECG was obtained from each animal (at least one minute) on a bipolar base apex lead using a single channel ECG machine (Cardiomax FX-2111, Fukuda, Japan) with a paper speed of 25 mm/s and calibration of 10 mm equal to 1 mV. The ECG was obtained when the animals were thought to be in a quiet standing position (without sedation and minimal restraint) using an alligator-type electrode attached to the skin. The positive electrode of lead I (left arm) was attached to the skin of the fifth intercostals space just caudal to the olecranon and the negative electrode (right arm) on the jugular furrow about the lower 1/3 of the left side of the neck, and the earth electrode was attached to withers (Rezakhani et al., 2004). Alligator clips were fixed to the skin after application of methyl alcohol.

A magnifying glass was used for analyzing and measuring ST-segment duration and morphology. The ST-segment is the portion of tracing falling between the QRS complex and the T wave (Figure 1). Using this method of measurement, the precision of duration and amplitude was 0.02 s and 0.05 mV, respectively.

Comparison of ST-segment duration between the two sexes and two species was performed using two sample t- tests. Also, analysis of variance (ANOVA) test was used for the purpose of comparison between different breeds and age groups (SPSS for Windows, version 17, SPSS Inc, Chicago, Illinois). Comparison of ST-segment morphology between the two sexes, two

species, different breeds of goats and different age groups was performed using Fisher's exact test. Differences were considered significant at $P < 0.05$.

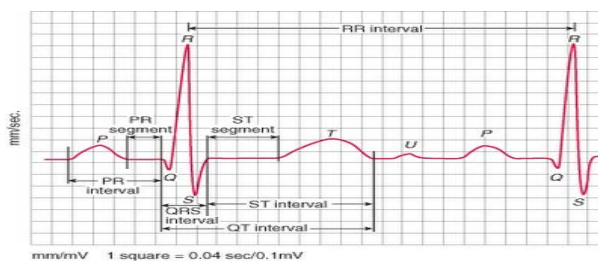


Figure 1. Electrocardiographic (ECG) parameters comprising: waves amplitude and duration, and duration of PR and ST-segments. Paper speed: 25 mm/s, calibration: 10 mm/mv (Andreoli et al., 2010; Samimi et al., 2015).

Results

The ST-segment duration ranged from 0.08 ± 0.01 to 0.22 ± 0.02 (second) with an average of 0.11 ± 0.01 and 0.16 ± 0.01 in sheep and goats, respectively. The results of the measurement of ST-segment are shown in Table 1 comprising: duration and configuration in different species, breeds, genders and age groups. The results of the present study showed that ST-segment duration in goat was significantly higher than sheep ($P < 0.05$) and also in G₃ significantly higher than G₁ in Kermani sheep ($P < 0.05$) (Table 1). Furthermore, no significant difference was found for ST-segment duration between different genders, breeds and age groups of goats. The morphologic assessments of ECGs showed that there were not significant differences among all groups.

Table 1. Mean \pm SD of ST-segment duration (second) in base apex lead electrocardiography (ECG) of clinically apparently healthy sheep and goats in different sexes, age groups and breeds.

		Sex						
		All animals	Male	Female	G1	G2	G3	G4
Species	Sheep (n=40)	0.11 \pm 0.01 ^a	0.12 \pm 0.01	0.11 \pm 0.01	0.09 \pm 0.04 ^b	0.11 \pm 0.04	0.14 \pm 0.02 ^b	0.16 \pm 0.05
	Goat (n=95)	0.16 \pm 0.01 ^a	0.16 \pm 0.01	0.17 \pm 0.01	0.15 \pm 0.04	0.17 \pm 0.04	0.18 \pm 0.04	0.17 \pm 0.05
Breed	Kermani sheep (n= 40)	0.11 \pm 0.01	0.12 \pm 0.01	0.11 \pm 0.01	0.09 \pm 0.04	0.11 \pm 0.04	0.14 \pm 0.02	0.16 \pm 0.05
	Saanen goats (n=56)	0.16 \pm 0.01	0.15 \pm 0.01	0.17 \pm 0.01	0.16 \pm 0.05	0.16 \pm 0.05	0.18 \pm 0.04	0.17 \pm 0.06
	Raini goats (n=39)	0.16 \pm 0.01	0.16 \pm 0.01	0.17 \pm 0.01	0.15 \pm 0.03	0.17 \pm 0.04	0.20 \pm 0.02	0.18 \pm 0.02

^a With significant difference between two species ($P < 0.05$).

^b With significant difference between age groups ($P < 0.05$).

G1 < 3 months, 3 months \leq G2 < 1 year, 1 year \leq G3 < 3 years, and G4 \geq 3 years old

Table 2. Comparison of the frequency of ST-segment morphology in base apex lead electrocardiography (ECG) of clinically apparently healthy sheep and goats in different sexes, age groups and breeds.

	Morphology	Number	Sex		Age				
			Male	Female	G1	G2	G3	G4	
Species	Sheep (n=40)	+	23	12	11	8	3	6	6
		-	17	7	10	7	5	2	3
	Goat (n=95)	+	62	21	41	21	13	18	10
		-	33	16	17	9	8	6	10
Breed	Kermani sheep (n= 40)	+	23	12	11	8	3	6	6
		-	17	7	10	7	5	2	3
	Saanen goats (n=56)	+	35	9	26	11	7	13	4
		-	21	8	13	5	5	4	7
	Raini goats (n=39)	+	27	12	15	10	6	5	6
		-	12	8	4	4	3	2	3

+: elevated ST-segment

- : non-elevated ST-segment

G1<3 months, 3 months ≤G2< 1 year, 1 year≤G3<3 years, and G4 ≥ 3 years old

Discussion

Evaluation of cardiac problems could be performed by ECG as the clinical method (Santamarina et al., 2001). To the best of researchers' knowledge, there are just a few previous researches about ST-segment duration and morphology in clinically healthy sheep and goats (Balicki and Yildi, 2006).

The ST-segment is the portion of tracing falling between the QRS complex and the T wave. During this time, the ventricle is contracting, but no electricity is flowing (Pourjafar et al., 2012). The ST-segment is therefore usually even with the baseline (line drawn from P start to T end). It represents the period of slow repolarization of the ventricles. ST-segment may be horizontal, elevated or depressed (Gertsch, 2009; Pourjafar et al., 2012).

Bipolar leads (I, II, III, base-apex, X, Y and Z of the orthogonal lead system) and unipolar leads (aVF, aVR, aVL, thoracic) have been described, but the amplitude, duration and configuration of the different wave forms vary widely, depending on an animal's breed, size, body type and sex (Pourjafar et al., 2012; Radostits et al., 2007). The base apex lead appears to be the most useful in measuring conduction times (i.e., durations of component deflections, intervals, and segments) because the origins and terminations of deflections could be identified easily (Pourjafar et al., 2012; Santamarina et al., 2001). The results of the present study showed that the value of ST-segment duration ranged from 0.08±0.01 to 0.22±0.02 (second) with an average of 0.11±0.01 and 0.16±0.01 in sheep and goats, respectively. Our findings showed that ST-segment duration in goats was little different from that reported by Pogliani et al. (2013) in Saanen goats (0.15±0.041)

and was less than what was reported by Ahmed and Sanyal (2008) in Black Bengal goats (0.19±0.014). Also our findings showed that ST-segment duration in Kermani sheep was less than that reported by Ahmed and Sanyal (2008) in Garol sheep (0.13±0.010). It may be due to the breed variation, ECG lead system differences, heart rate, and size of body and heart during aging in sheep and goats. This parameter in sheep and goats was lower than in cattle and horse (Pourjafar et al., 2012; Radostits et al., 2007) which may be due to the lower heart mass in small ruminants.

Although, the heart rate of goats is higher than sheep (Radostits et al., 2007; Samimi et al., 2015) and there is a negative correlation between ST-segment duration and heart rate, (Jafari-Dehkordi et al., 2012; Milhorn, 2005; Pogliani et al., 2013) in the current study, the ST-segment duration in goats was longer than in sheep. Inter species difference, the conductive properties of the body mass and the volume of the gastrointestinal tract can influence the distribution of electrical potentials to the body surface (Santamarina et al., 2001) and this may explain the different ST-segment duration between the sheep and goats in our study.

The results of the present study showed that there was no significant difference between lambs and adults in Kermani sheep in the heart rate (1610.05±6.53 and 134.12±7.30 beats/minute, respectively). However, the ST-segment duration in G3 was significantly higher than G1 group. Pourjafar et al. (2012) and Pogliani et al. (2013) believed that the augmentation in heart size in animals becomes larger during growth, causes a decrement in heart rate. Different growth rates, body sizes, inter breed variations can be proposed as the

probably causes of the controversial findings (Pogliani et al., 2013; Pourjafar et al., 2012)

Upward or downward shifts in the ST-segment were evaluated in this study. Our findings showed that elevation of ST-segment was not seen in any groups of animals (Table 1) and morphologic assessments of ST-segment showed that all groups had normal isoelectric (horizontal) ST-segment. It shows that sex, age, species and breed had no effect on ST-segment in sheep and goats. In humans, elevation of the ST-segment from baseline, can indicate right or left bundle branch block, left ventricular hypertrophy, acute myocardial infarction, myocardial contusion, pericarditis, left ventricular aneurysm, acute myocarditis, right ventricular infarction, dissecting aortic aneurysm, acute pulmonary embolism, various central and autonomic nervous system abnormalities, thiamine deficiency, hypercalcaemia, hyperthyroidism, hyperkalaemia and compression of right ventricular outflow tract by metastatic tumor (Gertsch, 2009; Häggmark et al., 2005; Machler et al., 1998; Nagy, 2009; Nishi et al., 2006; Wang et al., 2003). In some healthy young adult humans, a form of ST-segment elevation can be normal (Wang et al., 2003). The mechanisms of ST-segment changes in animals have not yet been fully clarified (Pourjafar et al., 2012). However, such literatures mention that the ST-segment elevation is the result of an epicardium to endocardium voltage gradient during the early repolarization phases of the action potential (Grant, 2001; Pourjafar et al., 2012). But, Pourjafar et al. (2012) and Chalmeh et al. (2014) suggested that electrolyte imbalances due to acidosis in newborn and diarrheic calves may induce ST-segment elevation.

It seems that our study on ST-segment duration may be helpful in standardizing base apex lead in small ruminant of various ages, sexes and breeds. It has been reported that the base apex lead gave the least variable ECG tracings in all the animals. The present study showed that sex, age and breed had no effect on ST-segment in sheep and goats in base apex lead and the obtained data can provide a good basis for judging the ST-segment length and morphology in difference sexes, breeds and age groups of sheep and goats.

REFERENCES

- Ahmed, J.A., Sanyal, S., 2008.** Electrocardiographic studies in Garol sheep and black Bengal goats. *Research Journal of Cardiology* 1, 1-8.
- Andreoli, T.E., Benjamin, I.J., Griggs, R.C., Wing, E.J., 2010.** Diagnostic tests and procedures in the patient with cardiovascular disease, in: Andreoli and Carpenter's: Cecil essentials of medicine. Saunders, Philadelphia, pp. 46-47.
- Balikci, E., Yildi, A., 2006.** Electrocardiographic parameters in single and twin pregnant and non-pregnant sheep. *The Indian Veterinary Journal* 83, 1076-1078.
- Chalmeh, A., Pourjafar, M., Naghib, M., 2014.** Comparison of ST-segment duration and morphology between clinically healthy and diarrheic Holstein dairy calves. *Journal of the Faculty of Veterinary Medicine Istanbul University* 40, 162-167.
- Escudero, A., González, J.R., Benedito, J.L., Prieto, F.R., Ayala, I., 2009.** Electrocardiographic parameters in the clinically healthy Zamorano-leones donkey. *Research in Veterinary Science* 87, 458-461.
- Fakour, S., Mokhber Dezfuli, M., Nadalian, M., Rezakhani, A., Lotfollah Zadeh, S., 2013.** Electrocardiographic parameters of Markhoz goat using base apex lead and six standard limb leads. *Iranian Journal of Veterinary Research* 14, 241-244.
- Gertsch, M. 2009.** Electrolyte Imbalance and Disturbances, In: *The ECG Manual: An Evidence-Based Approach*, Springer Verlag, London, pp. 177-190.
- Grant, A.O., 2001.** Molecular biology of sodium channels and their role in cardiac arrhythmias. *The American Journal of Medicine* 110, 296-305.
- Häggmark, S., Haney, M.F., Jensen, S.M., Johansson, G., Näslund, U., 2005.** ST-segment deviations during pacing-induced increased heart rate in patients without coronary artery disease. *Clinical Physiology and Functional Imaging* 25, 246-252.
- Jafari-Dehkordi, A., Haji-Hajikolaei, M.R., Karimi-Dehkordi, Z., 2012.** ECG changes in acute experimental ruminal lactic acidosis in sheep. *Veterinary Research Forum* 2, 203-208.
- Li, D., Li, C.Y., Yong, A.C., Kilpatrick, D., 1998.** Source of electrocardiographic ST changes in subendocardial ischemia. *Circulation Research* 82, 957-970.
- Machler, H.E., Lueger, A., Rehak, P., Berger, J., Veith, W., Kuhbacher, C., Koidl, C., Stark, G., Metzler, H., 1998.** A new high-resolution esophageal electrocardiography recording technique: an experimental approach for the detection of myocardial ischemia. *Anesthesia and Analgesia* 86, 34-39.
- Milhorn, H.T., 2005.** The Electrocardiogram, In: *Electrocardiography for the Family Physician, The Essentials*. Brown Walker Press 11. pp. 1-52.
- Mohan, N., Niyogi, D., Singh, H., 2005.** Analysis of normal electrocardiograms of Jamunapari goats. *Journal of Veterinary Science* 6, 295-298.
- Nagy, D.W., 2009.** Resuscitation and critical care of neonatal calves. *Veterinary Clinics of North America: Food Animal Practice* 25, 1-11.
- Nishi, S.P., Barbagelata, N.A., Atar, S., Birnbaum, Y., Tuero, E., 2006.** Hypercalcemia-induced ST-segment elevation mimicking acute myocardial infarction. *Journal of Electrocardiology* 39, 298-300.

- Pogliani, F.C., Birgel Junior, E.H., Monteiro, B.M., Grisi Filho, J.H., Raimondo, R.F., 2013.** The normal electrocardiogram in the clinically healthy Saanen goats. *Pesquisa Veterinária Brasileira* 33, 1478-1482.
- Pourjafar, M., Badie, K., Chalmeh, A., 2012.** Evaluation of ST-segment duration and morphology of standard base apex lead electrocardiograms in different age groups of apparently healthy Holstein cattle. *Journal of the Faculty of Veterinary Medicine Istanbul University* 38, 51-58.
- Radostits, O.M., Gay, C., Hinchcliff, K.W., Constable, P.D., 2007.** Diseases of the Cardiovascular System, In: *Veterinary Medicine: A Textbook of the Diseases of Cattle, Horses, Sheep, Pigs and Goats*. Saunders, London, pp. 14-438.
- Rezakhani, A., Paphan, A.A., Shekarfroush, S., 2004.** Analysis of base apex lead electrocardiograms of normal dairy cows. *Veterinarski Arhiv* 74, 351-358.
- Samimi, A., Aghamiri, S., Tajik, J., Taheri, T., Eshteraki, R., 2015.** Analysis of cardiac arrhythmias and electrocardiographic indices of clinically healthy Saanen goats in different sexes and age groups. *Euroasian Veterinary Journal* 31, 192-196.
- Samimi, A.S., Tajik, J., Bakhshaei, S., Mirjordavi, A., 2015.** The effect of short term rest after handling stress on electrocardiogram indices in goat. *Veterinary Science Development* 5 (4), 127-129.
- Santamarina, G., Espino, L., Suarez, M.L., 2001.** Electrocardiographic parameters of free-ranging roe deer (*Capreolus capreolus*). *Journal of Zoo and Wildlife Medicine* 32, 441-446.
- Tajik, J., Samimi, A., Tajik, T., Bakhshaei, S., Mirjordavi, A., 2013.** Electrocardiographic parameters in clinically healthy Cashmere goats. *Online Journal of Veterinary Research* 17, 528-534.
- Wang, K., Asinger, R.W., Marriott, H.J., 2003.** ST-segment elevation in conditions other than acute myocardial infarction. *New England Journal of Medicine* 349, 2128-2135.