

Evaluation of the effects of ozone therapy on the treatment of cutaneous wounds with tissue-loss in dogs and cats

Research Article

ABSTRACT

The aim of this study was to investigate the effects of ozone treatments on the rapid and uncomplicated recovery of the wound or the shortening of the time of suture placement. This study was carried out on a total of 40 patients who were admitted to surgery clinic with 20 cats and 20 dogs of different ages, races and genders. These animals were divided into 4 groups. According to the statistics obtained; The patients in group 1 (ozonated oil) had the best reduction in wound size and clinical efficacy. This group was followed by group 3, which was supported by treatment with ozonated water. There was no statistically significant difference in both ozone bagging and control groups. As a result, it was observed that in addition to the treatment of skin wounds with tissue loss, ozonated oil or ozonated water accelerated healing by 50% on average.

Keywords: Ozone bagging, Ozonated oil, Ozonated water, Skin wound with tissue-loss.

INTRODUCTION

Researching methods and materials that will help heal wounds with tissue loss that can be seen in different parts of the body, and wounds that are infected or prone to infection, especially in animals, is a topic that remains up-to-date in the field of human and veterinary medicine (Engin, 2004; Güzel et al., 2011; Gornicki and Gutsze, 2000; Kim et al., 2009; Kirsner and Eaglsterin, 1993; Kutlubay et al., 2010; Nogales et al., 2008; Polat, 2009; Shinuzuka et al., 2008).

Especially in infected wounds, the infection must be eliminated for healing to take place. For this purpose, systemic and parenterally intensive antibiotics are used. In addition, it is used locally in skin wounds with tissue loss, together with pomades, in solutions with antiseptic properties. These applications require regular maintenance and dressing. Especially when pets are considered, the importance of care and dressing increases even more due to the care conditions and natural behaviors. The aim of wound care and dressing is to create a suitable environment for healing to occur, stimulate the onset of healing, control the exudate, minimize pain with mechanical support, and prevent contamination (Beanes et al., 2003; Rigler, 1997; Theoret, 2004; Wilmink and van Weeren, 2004; Witte and Burbul, 1997).

Wound healing is a complex process. These; inflammation, cell migration, angiogenesis, matrix synthesis, new collagen formation, and reepithelialization stages (Glenn and Thomas 1995).

Osman Aydın^{1a}
Ali Kumandaş^{1b}

¹ Department of Surgery,
Faculty of Veterinary
Medicine, Kırıkkale
University, Kırıkkale,
Türkiye

ORCID-

^a[0000-0001-6457-0983](https://orcid.org/0000-0001-6457-0983)

^b[0000-0002-7679-2126](https://orcid.org/0000-0002-7679-2126)

Correspondence

Ali KUMANDAŞ

alikumandas@kku.edu.tr

Article info

Submission: 18-04-2022

Accepted: 02-11-2022

Online First: 24-12-2022

Publication: 31-12-2022

e-ISSN: 2548-1150

doi prefix: 10.31797/vetbio

• <http://dergipark.org.tr/vetbio>

This work is licensed under a
Creative Commons Attribution 4.0
International License



How to cite this article

Aydın, O., Kumandaş A. (2022). Evaluation of the effects of ozone therapy on the treatment of cutaneous wounds with tissue-loss in dogs and cats. *Journal of Advances in VetBio Science and Techniques*, 7(3), 313-320. <https://doi.org/10.31797/vetbio.1104760>

Healing of the wound, that is, the repair of the tissue that has lost its integrity, is an important biological response for the continuity of life (Dinçer et al., 1996; Li et al., 2007). After injury, local and systemic immune responses are somehow stimulated. Disruption of tissue integrity for any reason initiates a series of physiological events that will restore the functional and morphological characteristics of the wound area (Li et al., 2007; Philips, 2000; Rigler, 1997). The most important feature in wound healing is that as long as a phase is not completed, the next phase does not start and the wound healing stops (Anderson, 1996; Diegelmann and Evans, 2004; Engin, 2000; Philips, 2000).

The aim of this study is to investigate the effects of ozonated oil, ozone bagging and ozonated water, which are the main application methods of ozone therapy in tissue-loss skin wounds, on the healing of tissue-loss skin wounds in dogs and cats.

MATERIAL and METHOD

Animals

This study was carried out on a total of 40 cases, 20 cats and 20 dogs of different ages, genders, and breeds, who were brought to the Surgery clinic with the complaint of cutaneous defect wounds in various parts of the body.

Ozonated oil; Face Ozonated oil (Face Ozon®, Ankara, Türkiye) was used, which was obtained as a result of exposure of specially prepared 0 acid cold-pressed 500 ml olive oil to ozone for 48 hours by a device producing 1 gr/hour ozone.

Ozone Bagging; Bags made of thick nylon prepared according to the extremity of the area to be applied. The ozone gas produced by the 500 mg ozone device supplied by the company (Refresh Ozon Ankara, Türkiye) is sent into the bag via the serum set and lasts for an average of

10 minutes. The wound area was exposed to ozone gas for a period of time.

Ozonated Water; Ozonated water was obtained by applying ozone gas for 10 minutes with a 500 mg/h ozone device to 0.5 lt mains water in a glass jar (Refresh O₃, Ankara, Türkiye). This ozonated water was applied to the wound within 5 min.

After obtaining anamnesis information from the owners for the cases included in this study, detailed information was given verbally about the patient's condition, the severity of the event, the treatment to be performed, and the study, and verbal consent was obtained from the owners. In these patients, after shaving around the wound, the wound was washed with saline and cleaned with chlorhexidine gluconate (Biohand Chx Scrub®, Tosel İlaç Sanayi, Türkiye) solution. Wound dimensions were measured and recorded as mm² (Figure 1). One of the ozone therapy methods was chosen according to the region of the wounds and the condition of the wound in the animals included in the study. Ozone applications were made in addition to routine wound care in all groups. After the wound was cleaned, ozone was applied according to the group of the patient. The dressing was applied to these patients. Beta-lactamase group antibiotics were administered to these patients as the antibiotic group. Antibiotic administration was applied for 7 days and antibiotic administration was terminated.

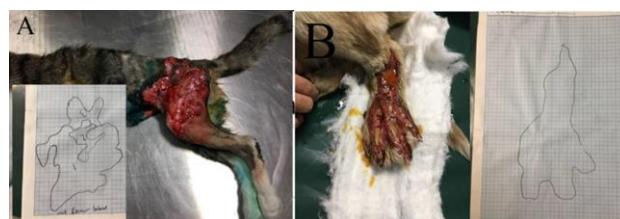

Figure 1. Planimetry for calculation of wound area. A- Wound area calculation in a cat, B- Wound area calculation in a dog.

Parenteral antibiotic administration and local ointment were applied to the cases included in the study as a routine treatment. The pomades

used; A mixture of nitrofurazone (Furacin®, Zentiva, Türkiye), Centella Asiatica (Madecassol®, Bayer, Türkiye), biyo rivoderm (Biyoteknik®, Türkiye), and rifamycin (Rif®, Koçak Farma, Türkiye) was applied on wounds with deep tissue loss, and zinc oxide (Oxyde de zinc®, Biyoteknik, Türkiye) pomade was applied on more superficial open wounds.

In the study groups, the wound sizes of the animals included in the whole study were measured and recorded on the 0th, 4th, 7th, 10th, 14th, and 21st days before, during, and after the treatment. The findings were recorded in the prepared wound follow-up form.

Patients, consisting of 20 cats and 20 dogs, who applied to the clinic with the complaint of cutaneous wounds with tissue loss, were divided into 4 groups, 10 cases in one group. Some of these were classified as full-thickness, while others were classified as superficial. In addition to the routine treatment protocol, ozone oil was applied to 5 cats and 5 dogs in the 1st group. In the second group, ozone bagging was applied to 5 cats and 5 dogs in addition to the routine treatment protocol. In addition to the routine treatment protocol, ozonated water was applied to 5 cats and 5 dogs in the 3rd group. In the 4th group, only routine treatment was applied to 5 cats and 5 dogs as the control group. In wounds with excessive tissue loss, granulation, contraction and epithelialization conditions of the tissue were evaluated after the discharge from the wound was stopped, and sutures were applied to the appropriate ones. In cases where sutures were applied, the size of the wound just before suturing was recorded by drawing on millimetric paper and was accepted as the last measurement of the case.

Statistical Analysis

The efficacy of ozone therapy was determined by evaluating the findings clinically and statistically. 5 animals from each group were used for statistical data. In the statistical evaluation, the data obtained on the 1st, 4th,

7th, 10th, 14th and 21st days were used. After statistical analysis of the data, it was determined that there was no normal distribution. Cats and dogs were evaluated separately. Differences between groups were determined by the Kruskal-Wallis test, which is a non-parametric test. Significance levels were evaluated with the Mann-Whitney test. Pearson Correlation analysis was performed to determine the relationship between wound size and wound closure rate in the study groups. Independent variables t-test was used to determine the relationship between infection and wound closure. SPSS 25.0 statistical package program was used for statistical evaluations. $P < 0.05$ was accepted to determine the significance levels.

RESULTS

The distribution of wounds in the animals included in the study showed great variation. These; bite wounds, burn wounds, injuries due to accidents and falls, leash wounds, wire cutting wounds, wounds with tissue loss due to scratching due to parasitic skin diseases, and wounds with tissue loss due to poor postoperative process management. In the animals included in the study, it was determined that the wounds mainly appeared in the neck region, back region, abdomen, and extremities as bitten wounds and incisional wounds caused by sharp objects.

The methods specified in the literature were used to evaluate the data on wound healing (Bohling et al. 2004). Wound healing was evaluated according to signs of infection control, wound contraction, epithelialization and granulation. Obtained data were evaluated separately in dogs and cats for each group in terms of wound closure times and closure rates. This was done to avoid the difficulty of comparing differences by species. Ozonated oil application was easier to obtain and applied more easily during application compared to other applications, and no symptoms of allergic

reaction or sensitivity were encountered (Figure 2).

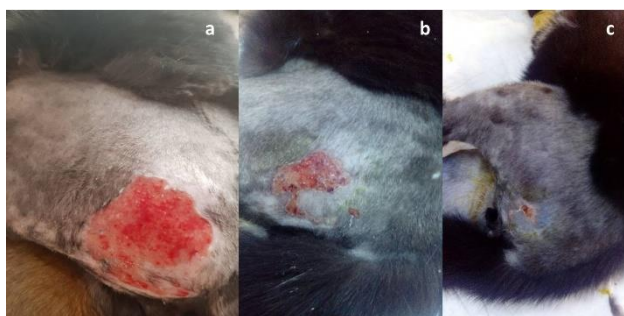

Figure 2. Ozonated oil treatment. a: Day 0 of treatment, b: Day 7 of treatment, c: Day 14 of treatment.

It has been observed that the ozone bagging technique can be applied without any problems in animals with a calm temperament, however, there are difficulties in restraint in animals that are active and aggressive. It was observed that the dry wound line was irrigated after ozone bagging (Figure 3).

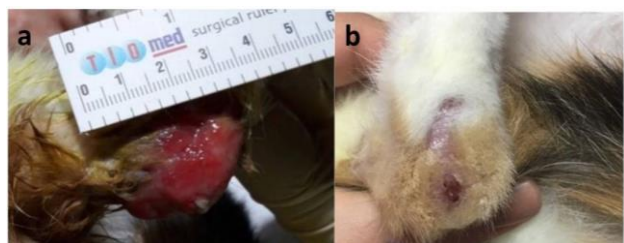


Figure 3. Ozone bagging treatment. a: Day 0 of treatment, b: Day 21 of treatment.

No allergic reactions or sensitivities were observed in the patients. In all ozone applications, it was observed that granulation

tissue protruding from the wound line was formed as a result of long-term ozone application. However, it was determined that this rate was slightly higher in ozonated water applications (Figure 4). Only routine treatment was applied to the patients in the control group.

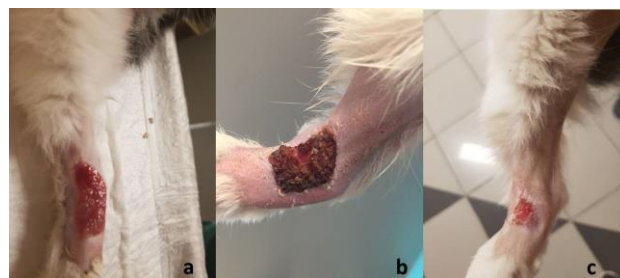

Figure 4: Ozonated water treatment. a: Day 0 of treatment, b: Day 7 of treatment, c: Day 14 of treatment.

The clinical efficacy percentages of the groups were calculated according to the data obtained as a result of the follow-up of the animals included in the study during the recovery period (Table 1). In some animals, the wounds were closed by suturing on the 7th, 10th, and 14th days. The time of suturing was considered the recovery time in these animals. When evaluated as the healing time, it was determined that the fastest healing was in the wounds of the animals in the ozonated oil and ozonated water groups.

Table 1. Average of clinical efficacy percentages of study groups

Group	Animal	Day 0	Day 4	Day 7	Day 10	Day 14	Day 21	P
Ozonated oil	Dog	0	28,98	37,026	66,81 ^a	78,04	91,76	0,040
	Cat	0	21,38 ^c	30,74	77,50	*	-	0,056
Ozone bagging	Dog	0	17,49	19,16	25,44 ^a	48,98 ^b	88,86	0,013 ^a - 0,016 ^b
	Cat	0	9,85 ^c	14,48 ^d	14,09	11,11	57,76	0,041 ^c - 0,027 ^d
Ozonated water	Dog	0	30,94	32,48	44,40	76,01 ^b	*	0,010
	Cat	0	32,13	37,92 ^d	51,70	71,96	93,85	0,027
Control	Dog	0	16,29	33,52	45,65	61,41 ^b	88,12	0,016
	Cat	0	8,49 ^c	13,42 ^d	16,16	28,92	35,32	0,021 ^c -0,013 ^d

(*)There is no data to participate in the measurement because the suture was applied or the wound closure was completed. Data are expressed as mean (n=40). ^a:Significant difference in clinical efficacy parameters between ozonated olive oil group and other groups on 10th day in dogs. ^b:Significant difference in clinical efficacy parameters between ozonated olive oil group and other groups on 14th day in dogs. ^c:Significant difference in clinical efficacy parameters between ozonated olive oil group and other groups on 4th day in cats. ^d:Significant difference in clinical efficacy parameters between ozonated olive oil group and other groups on 7th day in cats.

When wound closure times and percentages were examined in statistical evaluations, a negative correlation was found between the ozonated oil group and both the control group and ozone bagging group. A positive correlation was determined between antibiotic use and wound healing time in all study groups. Wound healing and closure rate was determined at the highest level, especially in the groups in which ozonated oil was applied. There was no statistically significant relationship between ozone bagging and the control group as a local application (Figure 5).

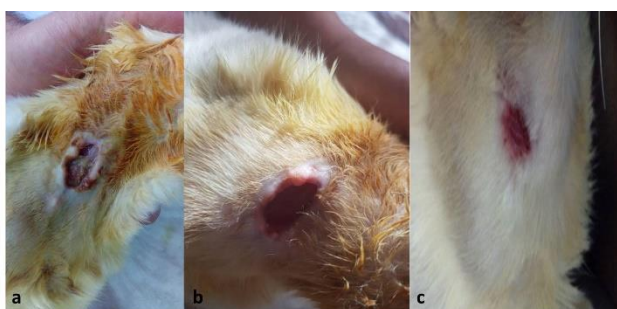

Figure 5. Routine application in the Control group. **a:** Day 0 of treatment, **b:** Day 14 of treatment, **c:** Day 21 of treatment.

The two techniques with the highest recovery percentage were determined as Ozonated oil and Ozonated water. In the statistical evaluation of the dogs included in the study, it was determined that there was a significant difference between the ozone oil application and both the control and ozone bagging methods $P=0,040$. In the cat groups, although the values were close in terms of clinical efficacy, statistically marginal significance was determined at $P=0,056$. There was no significant difference between ozone bagging and control groups in terms of healing and wound closure times and percentages of clinical efficacy.

DISCUSSION

Wounds and wound healing have been of great importance for all living things since the beginning of life. Therefore, many studies have been conducted on wound healing. Studies on

wound healing in veterinary medicine are mostly performed on porcine and rodents. Especially in the field of veterinary medicine, proper and rapid wound healing is of great importance due to the care conditions and natural behavior of animals. Delayed healing in infected wounds or wounds with infected tissue loss causes patients to be affected systemically. For this purpose, it is necessary to apply drugs that will not harm the organism with its strong disinfectant feature for the purpose of healing infected wounds. In this context, the use of O_3 gas, one of the natural disinfectants, can be considered an innovative approach. The wound may close spontaneously by contraction and epithelialization. In wounds with large tissue loss, contraction is not sufficient, but if granulation is good and there is no infection, it can be closed in a shorter time by suturing. In this study, comparisons were made in terms of the contribution of different ozone therapy methods to skin wound healing, self-closing, or suturing time in dogs and cats.

In a study by Valacchi et al. (2005), ozone application was applied to patients with chronic ischemia using the autohemotherapy method and they concluded that it had a positive effect on healing. In this study, since it was thought that pure ozone gas could have a negative effect on ozone applications, it was applied in the form of an O_3/O_2 mixture. However, according to the statistical information obtained at the end of the study, it was observed that the recovery was not adversely affected in the cases where the ozone bagging method was applied, but it did not provide a significant contribution.

In another study conducted on patients who received ozone therapy, it was found that the patients who received ozone therapy had a positive effect, and it was concluded that the aspect that positively affected the healing in patients was the increase in tissue oxygenation. In addition, it has been determined that ozone does not have a stored structure and cannot show its effect very much because it cannot

penetrate when applied to the skin (Bocci, 2006). He concluded that ozonated oil is the best penetrating oil to the skin in ozone applications and it has a more positive effect on the patients who are applied. In this study, which was carried out in parallel with this information, it was determined that the recovery was faster in cases where ozonated oil and ozonated water were applied.

Kim et al. (2009) created full-thickness skin wounds in rats. They applied pure olive oil and ozonated oil to these wounds. It was determined that the healing was faster in the cases where ozonated oil was applied, and the amount of fibroblast growth factor was higher on the 7th day. Compared with this information, it was determined that among the ozone groups in the study, ozonated oil accelerated recovery by 50% and ozonated water by 40%.

Travagli et al. (2010) examined the effectiveness of ozone gas and ozonated oil applications on skin diseases and reviewed the recovery stages. In the study, they reported that the penetration of ozone oil on the skin is better, and that ozone gas does not have a significant positive effect on healing as a result of the lack of penetrating ability. The result obtained in our study is similar to the results in the literature. It has been observed that it has a positive effect on recovery in animals using ozonated oil. In the ozone bagging group, it had the same effect as the control group in terms of its contribution to healing.

Khadre et al. (2001) evaluated the antimicrobial effect of ozone in a study they conducted. As a result of this study, they concluded that ozone gas has a very strong antimicrobial effect and it would be appropriate to use it in foods since it does not leave any residue after use. In this study, it was observed that the infection regressed in a shorter time compared to other groups and was brought under control, especially in cases where

ozonated oil and ozonated water were applied to skin wounds with infected tissue loss.

Bocci et al. (2005) also investigated the autohemotherapy method they performed in patients with tumor tissues, which supports the positive effect of ozone on tissue oxygenation, and they supported that ozone increases tissue oxygenation.

In order for the tissue to heal and repair itself, it is necessary to increase oxygenation and improve blood flow (Clavo et al., 2004). In this study, like other researchers, it has been observed that it has a positive effect on tissue oxygenation and healing, especially in tissue loss skin wounds where ozone oil and ozonated water are used.

Bette et al. (2006) applied intraperitoneal O₃/O₂ mixture in a study they conducted on rats with peritonitis and observed that the survival rate increased by 33% in rats with peritonitis due to increased oxygenation and decreased bacterial load. In this study on skin wounds with tissue loss, it was observed that the infection was reduced and prevented at a faster rate in ozone groups of infected wounds.

Zamora et al. (2007) also divided 192 Wistar male rats with experimental septic shock into 16 groups of 12 animals in their study. As a result of the research carried out, the use of ozone alone does not have any effect on recovery. However, they observed that when used as an adjunct treatment, it had a positive effect on recovery. In a study by Shinuzka et al. (2008), it was determined that bacteria exposed to ozone gas had a significant reduction in toxin release and thus minimized the harmful effect it created. In this study, it was observed that the infection recovered faster and tissue regeneration increased in all ozone groups.

Kuroda et al. (2015) also investigated the effect of ozonated water on tumor tissues. As a result of this research, it was determined that ozonated water increased tissue oxygenation

and positively affected healing. At the same time, since direct inhalation of O₃ gas will have a toxic effect on the lungs, treatment with ozonated water has been tried and it has been determined that it has a positive effect on the treatment. In this study, it was determined that the recovery was the fastest after ozone oil in cases where ozonated water was used.

CONCLUSION

As a result, it is a known fact that ozone is used for therapeutic purposes with very different methods. Especially in the field of veterinary surgery, literature information about its use in skin wounds with tissue loss is rare. In this study, ozone oil, ozonated water and ozone bagging techniques, which are the main local applications of ozone therapy in the treatment of tissue loss skin wounds, were compared in terms of their contribution to clinical healing. The findings obtained after the study were compared with the medical literature due to the scarcity of studies in the veterinary field. It has been determined from the data obtained that ozone therapy contributes to wound healing. However, among these study groups, it was determined that the most effective technique was ozone oil application, ozonated water and ozone bagging method, respectively. It is thought that ozone oil can be used more comfortably with the dressing material clinically. In the light of the findings obtained from the study, it was concluded that the use of ozone oil will contribute 50% more to wound healing and this study will shed light on more detailed studies in both veterinary medicine and human medicine.

ACKNOWLEDGMENT

Ethical approval:

Kırıkkale University Animal Experiments Ethics Committee. Ethical Approval: Date: 2020- 2020/05 Number: HADYEK-2020-29

Conflict of interest: Conflict of interest: The authors stated that there is no conflict of interest

REFERENCES

- Anderson, D. (1996).** Wound management in small animal practice, *In Pract*, 18, 115-128.
- Beanes, S.R., DANG, C., Soo, C., Ting, K. (2003).** Skin repair and scar formation: the-central role of TGF- β , *Expert. Rev. Mol. Med*, 5 (21), 1-11.
- Bette, M., Nusing, R.M., Mutters, R., Zamora, Z.B., Menendez, S., Schulz, S. (2006).** Efficiency of tazobactam/piperacilin in lethal peritonitis is enhanced after preconditioning of rats with O₃/O₂-pneumoperitoneum, *Shock*, 25, 23-29.
- Bocci, V. (1999).** Biological and clinical effects of ozone: has ozone therapy a future in medicine?, *British Journal of Biomedical Science*, 56, 270-279.
- Bocci, V. (2006).** Scientific and medical aspects of ozone therapy. *State of the art. Archives of Medical Research*, 37, 425-435.
- Bocci, V., Larini, A., Micheli, V. (2005).** Restoration of normoxia by ozone therapy may control neoplastic growth: a review and a working hypothesis, *The Journal of Alternative and Complementary Medicine*, 11 (2), 257-265.
- Bohling, M.W., Henderson, R.A., Swaim, S.F., Kincaid, S.A., Wright, J.C. (2004).** Cutaneous wound healing in the cat: A macroscopic description and comparison with-cutaneous wound healing in the dog, *Vet. Surg*, 33, 579-587.
- Clavo, B., Perez, J.L., Lopez, L., Suarez, G., Lloret, M., Rodriguez, V., Marias, D., Santana, M., Hernandez, M.A., Martin-Oliva, R., Robaina, F. (2004).** Ozone therapy for tumor oxygenation: a pilot study, *Evidence-based Complementary and Alternative Medicine*, 1(1), 93-98.
- Diegelmann, R.F., Evans, M.C. (2004).** Wound healing: an overview of acute, fibrotic-and delayed healing, *Front. Biosci*, 9, 283-289.
- Dinçer, S., Babul, A., Erdoğan, D., Özgül, L., Dinçer, S.L. (1996).** Effect of-Taurine on Wound Healing, *Aminoacids*, 10, 59-71.
- Engin, A. (2004).** Yara iyileşmesi, In İ. Sayek (Ed.), *Temel Cerrahi*, pp. (266-277). Güneş Kitabevi, Ankara,
- Glenn, F.B., Thomas, A.M. (1995).** Pharmacologic enhancement of wound healing, *Annu Rev. Med*, 46, 467-481.
- Gornicki, A., Gutsze, A. (2000).** In vitro effects of ozone on human erythrocyte membranes: An EPR study. *Acta Biochimica Polonica*, 47(4), 963-971.
- Güzel, Ö., Yıldar, E., Erdikmen, D.O. (2011).** Medikal ozon ve veteriner cerrahide kullanımı, *Vet. Fak. Derg. Med.*, 37(2), 177-184.
- Khadre, M.A., Yousef, A.E., Kim J.G. (2001).** Microbiological aspects of ozone applications in food:a review, *Journal of Food Science*, 66(9), 1242-1252.
- Kim, H.S., Noh, S.U., Han, Y.W., Kim, K.M., Kang, H., Kim, H.O., Park, Y.M. (2009).** Therapeutic effects of topical application of ozone on acute

- cutaneous wound healing. *Journal of Korean Medical Science* 24, 368-374.
- Kirsner, R.S., Eaglsterin, W.H. (1993).** The wound healing process, *Dermatol. Clin*, 11(4), 629-640.
- Kuroda, K., Azuma, K., Mori, T., Kawamoto, K., Murahata, Y., Tsuka, T., Osaki, T., Ito, N., Imagawa, T., Itoh, F., Okamoto, Y. (2015).** The safety and anti-tumor effects of ozonated water in vivo, *International Journal of Molecular Sciences*, 16, 25108-25120.
- Kutlubay, Z., Engin, B., Serdaroğlu, S., Tüzün, Y. (2010).** Dermatolojide ozon tedavisi, *DERMATOZ*, 1(4), 209-216
- Li, J., Chen, J., Kirsner, R. (2007).** Pathophysiology of acute wound healing, *Clin. Dermatol*, 25, 9-18.
- Nogales, C.G., Ferrari, P.A., Kantorovich, E.O., Lage-Marques, J.L. (2008).** Ozone therapy in medicine and dentistry, *The Journal of Contemporary Dental Practice*, 9(4), 75-84.
- Philips, S.J. (2000).** Physiology of wound healing and surgical wound care, *ASAIO Journal*, 46, 2-5.
- Polat, H. (2009).** Dezenfeksiyon amaçlı ozon kullanımı, *Yunus Araştırma Bülteni*, 9(2), 14-15.
- Rigler, D.J. (1997).** Inflammation and repair, In T.C. Jones, R.D. Hunt, N.W. King, (Eds.), *Veterinary Pathology*, (pp.150-157).
- Shinuzuka, Y., Uemetsu, K., Takagi, M., Taura, Y. (2008).** Comparison of the amounts of endotoxin released from *Escherichia coli* after exposure to antibiotics and ozone: an In Vitro evaluation, *Journal of Veterinary Medical Science*, 70(4), 419-422.
- Theoret, C.L. (2004).** Wound repair in the horse: Problems and proposed innovative-solutions, *Clin. Tech. Equine. Pract*, 3;134-140.
[doi:10.1053/j.ctep.2004.08.010](https://doi.org/10.1053/j.ctep.2004.08.010)
- Travagli, V., Zanardi, I., Valacchi, G., Bocci, V. (2010).** Ozone and ozonated oils in skin diseases: A review. *Mediators of Inflammation*,
[doi:10.1155/2010/610418](https://doi.org/10.1155/2010/610418)
- Valacchi, G., Fortino, V., Bocci, V. (2005).** The dual action of ozone on the skin, *Br J Dermatol*, 153, 1096-1100.
- Wilmink, J.M., Van Weeren, P.R. (2004).** Differences in wound healing between horses and-ponies: application of research results to the clinical approach of equine wounds, *Clin. Tech. Equine. Pract*, 3; 123-133.
- Witte, M.B., Burbul, A. (1997).** General principles of wound healing, *Surg. Clin. N.Amer*, 77; 509-258.
- Zamora, Z. B., Menéndez, S., Bette, M., Mutters, R., Hoffmann, S., & Schulz, S. (2003, August).** Ozone Prophylactic Effect and Antibiotics as a Modulator of Inflammatory Septic process in Rats. In *Proceedings of the 16th International Ozone Association World Congress, Las Vegas, NV, USA* (p. 123).
<https://medicalozone.info/wp-content/uploads/Ozone-Therapy-Sepsis.pdf>