



# Percutaneous Treatment of Massive Pneumoperitoneum Following Reintubation After Coronary Artery Bypass Surgery

Arif Selçuk<sup>1</sup>(iD), Mehmet Emir Erol<sup>2</sup>(iD), Sertan Özyalçın<sup>2</sup>(iD)

<sup>1</sup> Clinic of Pediatric Cardiovascular Surgery, Gaziantep Cengiz Gökçek Gynecology and Pediatrics Diseases Hospital, Gaziantep, Turkey

<sup>2</sup> Clinic of Cardiovascular Surgery, Hitit University Erol Olçok Training and Research Hospital, Çorum, Turkey

## ABSTRACT

The aim of this study is to present a percutaneous treatment option for a patient with massive pneumoperitoneum following intubation after coronary artery bypass surgery. After coronary artery bypass surgery, a 74-year-old woman had prolonged endotracheal intubation due to hypoxia associated with pneumonia. On postoperative day seven, she was reintubated with inadequate ventilation leading to hypercapnia due to blockage of the endotracheal tube. Shortly after intubation, the patient was hypotensive, tachycardic, and hypoxic. The breath sound was absent on the right hemithorax, and the abdomen was distended. The chest x-ray showed a right-sided tension pneumothorax. A chest tube was placed on suction to the right hemithorax immediately. The computed tomography scan showed a massive pneumoperitoneum without free fluid in the abdomen. Air evacuation from the peritoneum was performed using a 7 French percutaneous venous catheter and 50 cc syringe. As a practical technique to see air bubbles puffing out from the peritoneal cavity, we connected the sterile water-filled syringe to the line upwards. After the air evacuation, the abdomen was softened and non-distended. Arterial blood gas sample and peak airway pressure became normal. To avoid unnecessary surgical procedures, we need to recognize whether pneumoperitoneum is surgical or not. In non-surgical pneumoperitoneum, the less invasive air evacuation techniques may be faster, more practical, and as effective as placing an intraperitoneal tube or laparoscopy. The percutaneous drainage techniques should be tried as a first-line treatment in pneumoperitoneum without symptoms and signs of peritonitis.

**Key Words:** Pneumoperitoneum; minimally invasive surgical procedures; perioperative care

## Koroner Arter Bypass Cerrahisi Geçirmiş Bir Hastanın Reentübasyonu Sonrası Gelişen Masif Pnömooperitonumun Perkutan Tedavisi

### ÖZET

Bu çalışmamızın amacı koroner arter bypass cerrahisi geçirmiş bir hastanın postoperatif erken dönemde reentübasyonu sonrasında gelişen masif pnömooperitonumun tedavisinde kullanılabilecek alternatif bir perkutan tedavi yöntemini sunmaktır. Yetmiş dört yaşında bir kadın hasta koroner arter bypass cerrahisi sonrası pnömoni ilişkili hipoksi nedeniyle uzamış endotrakeal entübasyona maruz kaldı. Postoperatif yedinci günde endotrakeal tüpün sekresyonlara bağlı oluşan darlığının yol açtığı inefektif ventilasyon ve hiperkapni nedeniyle reentübe edildi. Entübasyonun hemen sonrasında hastanın hipotansif, taşikardik ve hipoksik olduğu görüldü. Solunum sesleri sağ toraksta alınamıyordu ve batın gergindi. Akciğer grafisinde sağ tarafta tansiyon pnömotoraks görüldü. Hemen sağ toraksa bir göğüs tüpü yerleştirildi. Batın gerginliği nedeniyle çekilen batın tomografisinde intraperitoneal alanda serbest sıvı olmadan masif hava varlığı görüldü. Peritonun içinden hava tahliyesi için 7F santral venöz kateter ve 50 cc'lik enjektör kullanıldı. Kateter intraperitoneal bölgeye ilerletildikten sonra kateterin lümenlerinden birinin ucuna içi steril sıvı ile doldurulmuş enjektör ters çevrilerek bağlandı ve hava kabarcıklarının enjektördeki sıvının yüzeyine çıktıkları görüldü. Hava boşaltıldıktan sonra batın yumuşadı ve gerginliği azaldı. Arteriyel kan gazı düzeldi ve hava yolu basınçları normale geldi. Gereksiz cerrahi girişimden kaçınmak için pnömooperitonuma neden olan etyolojiyi iyi belirlemek gerekmektedir. Cerrahi gerektirmeyen pnömooperitonumda daha az invaziv hava tahliye yöntemleri kullanmak daha hızlı sonuç vermenin yanında daha pratik olup intraperitonea tüp yerleştirmek veya laparoskopi kadar etkilidir. Pnömooperitonumda perkutan drenaj tekniklerinin peritonit semptom ve bulgularının olmadığı durumlarda ilk basamak tedavide kullanılabilecek olması akılda tutulmalıdır.

**Anahtar Kelimeler:** Pnömooperitonum; minimal invaziv cerrahi işlemler; perioperatif bakım

## INTRODUCTION

Pneumoperitoneum usually represents a perforated hollow abdominal viscus that requires surgical exploration. Furthermore, the most frequently documented non-surgical pneumoperitoneum cases are associated with intrathoracic causes such as pneumothorax and

*Cite this article as: Selçuk A, Erol ME, Özyalçın S. Percutaneous treatment of massive pneumoperitoneum following reintubation after coronary artery bypass surgery. Koşuyolu Heart J 2022;25(1):108-110.*

## Correspondence

Arif Selçuk

E-mail: kdcaselcuk@gmail.com

Submitted: 20.12.2021

Accepted: 29.01.2022

Available Online Date: 15.04.2022

© Copyright 2022 by Koşuyolu Heart Journal. Available on-line at www.kosuyoluheartjournal.com

pneumomediastinum. In these cases, the pneumoperitoneum is often self-limited and well-tolerated<sup>(1)</sup>. Clinical diagnosis of non-surgical pneumoperitoneum in time can prevent unnecessary laparotomy or laparoscopic surgery<sup>(2)</sup>.

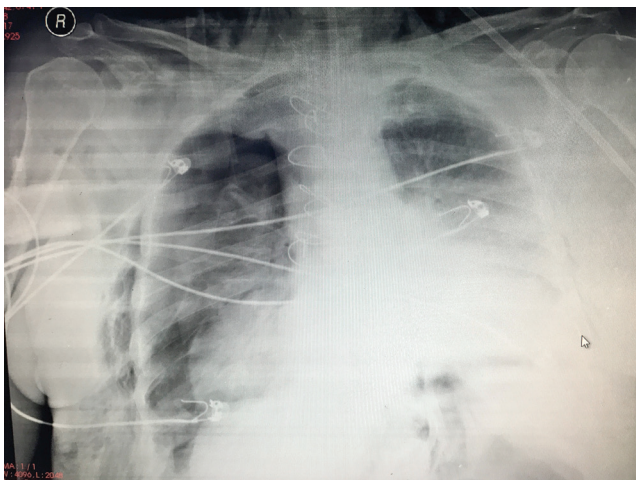
In our case, we discussed a clinical presentation of a patient with massive pneumoperitoneum after intubation and her treatment with percutaneous drainage of intraperitoneal air.

### CASE REPORT

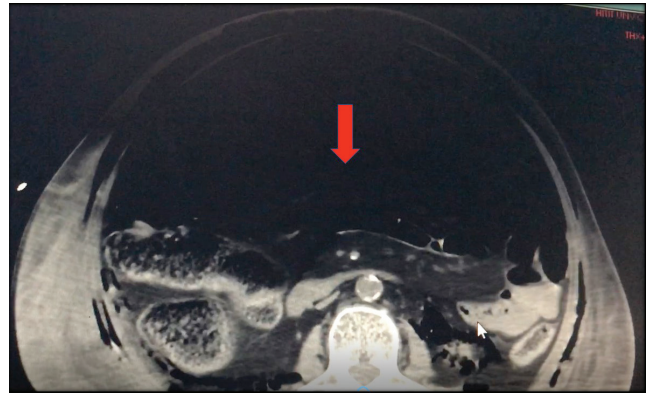
A 74-year-old woman with chronic renal failure and diabetes mellitus had a prolonged length of stay in the intensive care unit (ICU) after coronary artery bypass surgery due to nosocomial pneumonia and hypoxemia. She had an unsuccessful extubating attempt on postoperative day two. While she was followed up on a mechanical ventilator in the ICU, due to endotracheal tube blockage partially and limited ventilation, the patient was re-intubated with a new endotracheal tube on postoperative day seven.

After reintubation, the patient developed a sudden onset of abdominal distention, decreased unilateral breath sounds, and the arterial blood gas sample showed hypoxemia. The abdomen got distended within minutes. It was tympanic and soft without guarding and with bowel sounds. The chest x-ray revealed subdiaphragmatic free air and right-sided tension pneumothorax (Figure 1). A chest tube was placed on suction to the right hemithorax immediately. For evaluation of pneumoperitoneum, the computed tomography (CT) scan was performed. A computed tomography scan of the chest and abdomen confirmed a fully expanded right lung, and the presence of free intraperitoneal air without free fluid was observed (Figure 2).

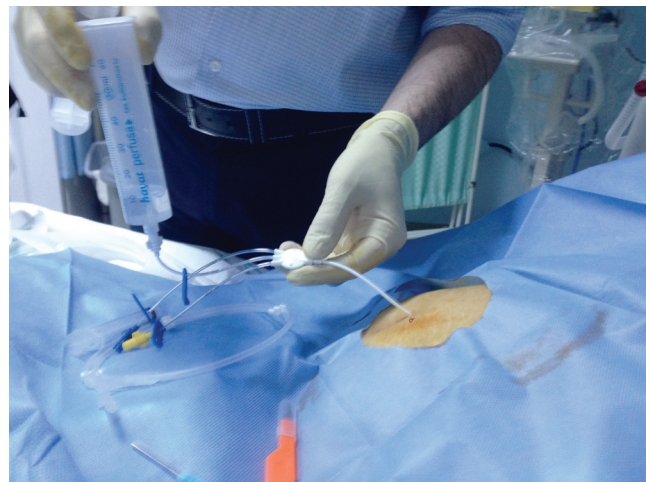
Massive pneumoperitoneum led to elevated peak airway pressure and ineffective mechanical ventilation with progressive hypoxemia. Air evacuation from the peritoneum was performed using a 7 French percutaneous venous central line and



**Figure 1.** Chest x-ray showing right-sided tension pneumothorax and free air under diaphragm.



**Figure 2.** Computed tomography of the abdomen shows massive pneumoperitoneum. Red arrow points to a large amount of free air in the peritoneal cavity and the viscera is pushed posteriorly.



**Figure 3.** Air evacuation from peritoneum with a 7 French percutaneous venous central line and 50 cc syringe. When the sterile water-filled syringe is connected to the line upwards, air bubbles puff out from the peritoneal cavity.

a 50 cc syringe (Figure 3). The central venous line was placed in the middle of the abdomen and 1-2 cm below the umbilicus, like a diagnostic peritoneal lavage catheter. As a practical technique to see air bubbles puffing out from the peritoneal cavity, we connected the sterile water-filled syringe to the line upwards. After the air was taken out with this technique, the abdomen was softened and non-distended. Arterial blood gas sample and peak airway pressure became normal following the intervention.

The patient had an uneventful extubation on postoperative day 12. She was discharged home on postoperative day 18.

### DISCUSSION

Our patient had tension pneumothorax and massive pneumoperitoneum. The reason for the tension pneumothorax was the high positive pressure during endotracheal intubation. After the chest tube placement, the findings of pneumoperitoneum

such as abdominal distension did not worsen and the tension pneumothorax showed immediate clinical improvement. An abdominal CT scan could not identify a stomach or bowel problem as the cause of pneumoperitoneum, so we called it non-surgical pneumoperitoneum. Pneumoperitoneum from an intrathoracic route is the most frequently reported cause of non-surgical peritoneal air collection. It is estimated that the pneumoperitoneum associated with mechanical ventilation may be seen in up to 7% of intubated patients<sup>(3)</sup>. This complication may lead to severe consequences such as tension pneumoperitoneum, abdominal compartment syndrome, and laparotomy. Fortunately, most non-surgical pneumoperitoneum are benign and can be observed without surgical intervention.

In 90-95% of cases of pneumoperitoneum, the perforation of the gastrointestinal tract is the reported cause. To avoid unnecessary surgical procedures, non-surgical causes of pneumoperitoneum need to be recognized. Between 1990 and 2013, all published 115 cases of pneumoperitoneum-related mechanical ventilation were associated with either pneumothorax or pneumomediastinum, or both. Fifty-seven of 115 pneumoperitoneum cases underwent surgical treatment without evidence of perforated viscera. In conclusion, the authors suggested that in the absence of symptoms and signs of peritonitis, conservative management should be preferred<sup>(4,5)</sup>.

Pneumomediastinum may present with simultaneous free air in the peritoneum, thorax, or subcutaneous tissue. The air enters the peritoneal cavity via the diaphragmatic hiatus such as the Morgagni or Bochdalek hiatus<sup>(6)</sup>.

In this case, we thought that a diaphragmatic defect in the thoracic cavity or a peritoneal defect in the subxiphoid region occurred by chance during chest drainage after cardiac surgery. This was most likely the cause of pneumoperitoneum following tension pneumothorax. We stopped the air supply to the

peritoneal cavity by placing a chest tube in the right hemithorax. Therefore, it is possible that pneumoperitoneum is not a more severe problem for our patient than tension pneumoperitoneum. However, we wanted to draw attention to one of the less invasive and practical methods that can be used to evacuate the air from the abdomen.

**Informed Consent:** Written informed consent was obtained from patient who participated.

**Peer-review:** Externally peer-reviewed.

**Author Contributions:** Concept/Design - MEE; Analysis/Interpretation - MEE; Data Collection - SÖ; Writing - AS; Critical Revision - AS; Final Approval - SÖ; Overall Responsibility - AS.

**Conflict of Interest:** All authors declare that they do not have conflict of interest.

**Financial Disclosure:** The authors declared that this study has received no financial support.

## REFERENCES

1. Williams NM, Watkin DF. Spontaneous pneumoperitoneum and other nonsurgical causes of intraperitoneal free gas. *Postgrad Med J* 1997;73(863):531-7. [[Crossref](#)]
2. Cecka F, Sotona O, Subrt Z. How to distinguish between surgical and non-surgical pneumoperitoneum? *Signa Vitae* 2014;9(1):9-15. [[Crossref](#)]
3. Okamoto A, Nakao A, Matsuda K, Yamada T, Osako T, Sakata H, et al. Non-surgical pneumoperitoneum associated with mechanical ventilation. *Acute Med Surg* 2014;1(4):254-5. [[Crossref](#)]
4. Mularski RA, Ciccolo ML, Rappaport WD. Nonsurgical causes of pneumoperitoneum. *West J Med* 1999;170:41-6.
5. Patel RV, Kumar H, Patwardhan N, Antao B. Pneumoperitoneum: A rare air leak in an infant with bronchiolitis and high frequency oscillatory ventilation. *BMJ Case Rep* 2013;bcr2013010447. [[Crossref](#)]
6. Elkholy KO, Akhtar H, Landa E, Malyshev Y, Sahni S. A case of pneumomediastinum and pneumoperitoneum with concurrent massive subcutaneous emphysema due to repositioning of a tracheostomy tube. *Cureus* 2019;11(1):e3881. [[Crossref](#)]