

Case Report / Olgu Sunumu

Two Cases With Chloroquine and Hydroxychloroquine Maculopathy

Klorokin ve Hidroksiklorokin Makülopatili İki Olgu

Fulya AKMAN, Eren ÇERMAN, Özlem YENİCE, Haluk KAZOKOĞLU

Marmara University School of Medicine, Department of Ophthalmology, İstanbul, Türkiye

ABSTRACT

We described two cases of retinopathy due to antimalarial drugs and evaluated drug screening methods in antimalarial treatment.

We reviewed our clinical records, fundus photographs, visual fields and the fluorescein angiographies of two patients from our retina referral department.

The first case arose due to the misinterpretation of test results, despite the presence of adequate screening tests. The second case arose because of the inadequate information about the importance of screening tests.

Keywords: Chloroquine, Hydroxychloroquine, Retinal toxicity

ÖZET

İki antimalarial ilaç kullanımına bağlı retinopati olgusu sunduk ve antimalarial tedavisinde tarama yöntemlerini değerlendirdik.

Retina bölümümüzde takip edilen iki olgunun klinik kayıtları, fundus fotoğrafları, görme alanı, floresan anjiyografileri incelendi.

İlk olguda testler yapılmış olduğu halde sonuçlarının yanlış yorumlanması, ikinci olguda ise hastaya tarama testlerinin öneminin yeterince anlatılmamış olması sebep olarak görüldü.

Anahtar Kelimeler: Klorokin, Hidroksiklorokin, Retinal toksisite

INTRODUCTION

The diagnosis of advanced chloroquine and hydroxychloroquine retinopathy is based on the combined presence of parafoveal pigment epithelial atrophy as seen on fundus biomicroscopy, and acquired paracentral scotoma on threshold visual field testing using the 10-2 program with white test light on a Humphrey perimeter¹. Although the effects of long term usage of antimalarials are well known, it is still debatable what type and what frequency of screening should be performed to recognize toxicity as early as possible.

Here we present two cases of antimalarial retinal toxicity which resulted with severe visual

impairment. Old and new screening methods to rule out possible ocular toxicity, the dose monitoring guidelines and the follow up strategy are subsequently discussed.

Both cases were screened for color vision defects with 25 plates of Ishihara test. The vision field tests were performed with The Humphrey Visual Field Analyzer (HFA; Carl Zeiss Meditec, Dublin, CA) in our department. All previous vision field tests were also performed with The Humphrey Visual Field Analyzer. For each patient, fundus fluorescein angiography and fundus photography were performed to diagnose maculopathy.

Başvuru tarihi / Submitted: 06.02.2010 **Kabul tarihi / Accepted:** 06.09.2010

Correspondence to: Özlem Yenice, M.D. Marmara Üniversitesi Tıp Fakültesi, Göz Hastalıkları Anabilim Dalı, İstanbul, Türkiye. e-mail: yeniceozlem@yahoo.com

CASE REPORT

Case 1.

A 24-year old woman (52 kg and 155cm tall) with a 6-year history of SLE was seen for retinal consultation on February 14, 2006 in our clinic. She had been taking a daily dose of 500 mg of chloroquine (9.62 mg/kg/day) for 2 years, 250 mg of chloroquine (4.81 mg/kg/day) for 1 year, 250 mg of chloroquine (4.81 mg/kg/day) once in two days for 2 years, 250 mg of hydroxychloroquine (3.84 mg/kg/day) for 2 months.

Best corrected visual acuity (BCVA) was 7/10 bilaterally, color vision was compromised. Fundus examination showed a ring of

depigmentation surrounded by a ring of hyperpigmentation (Figure 1) in both eyes. We stopped the administration of the drug with the diagnosis of Bull's eye maculopathy. Past medical history revealed that the patient had a 40-2 vision field report done on February 20th, 2003 and it was interpreted to be normal by a rheumatologist, although actually central scotomas (Figure 2) were compatible with chloroquine maculopathy. The second 40-2 field of vision was done on November 20th, 2005 and showed deterioration (Figure 3) of the visual field, but this was again considered as normal. During the 2 years follow up, neither further deterioration nor improvement of best visual acuity were disclosed (BCVA 0.7).

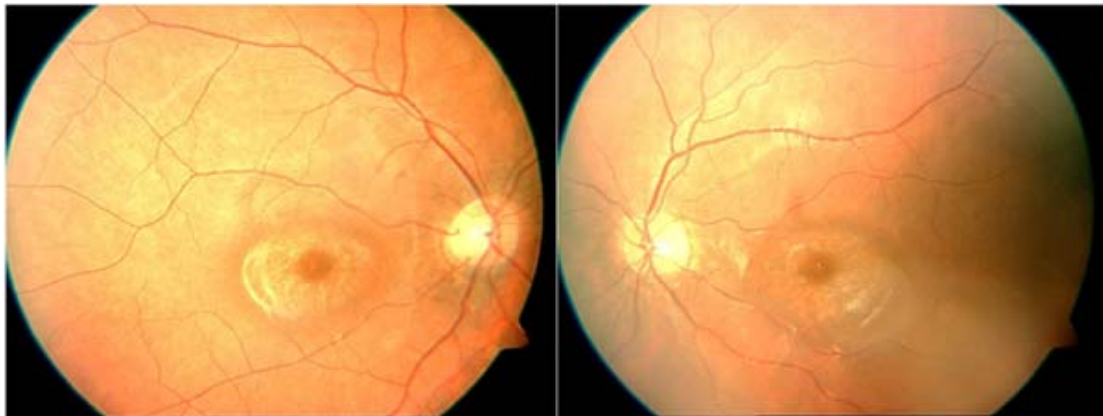


Figure 1. Case 1. A ring of depigmentation surrounded by a ring of hyperpigmentation on colored fundus photographs in both eyes.

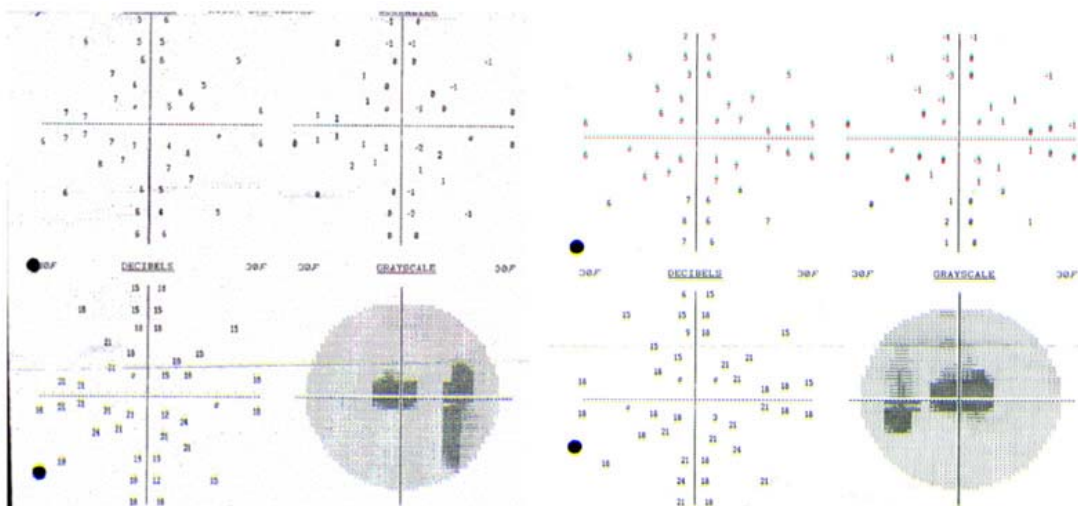


Figure 2. Case 1. Field of vision test from February 20, 2003. Central scotomas are seen bilaterally.

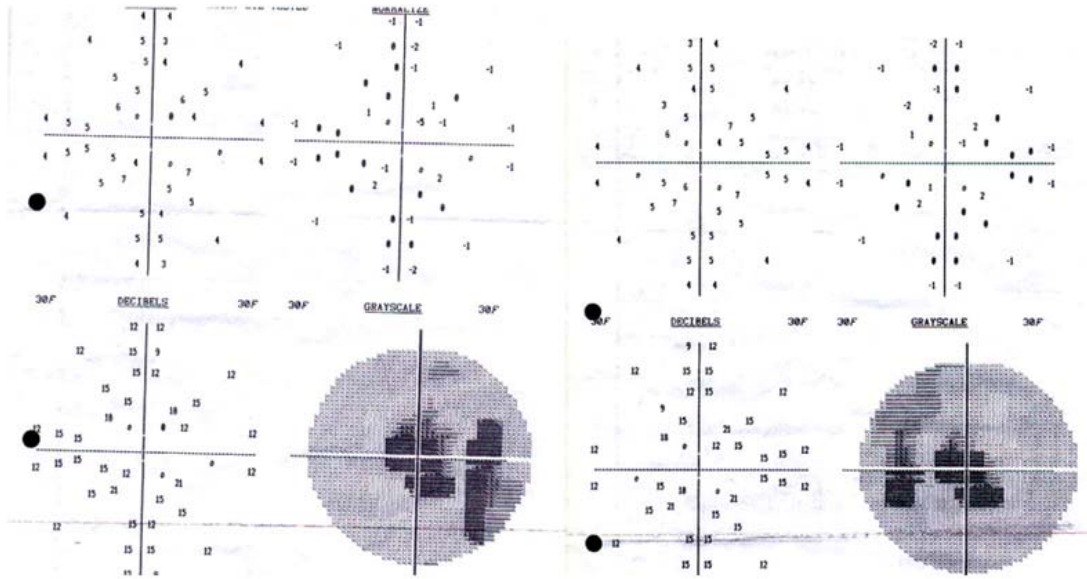


Figure 3. Case 1. Field of vision from November 20, 2005. Deterioration of visual field and enlargement of central scotomas.

Case 2

A 56-year old woman was referred from the Department of Rheumatology at Marmara University Faculty of Medicine with a 5-year history of SLE. She was seen for ophthalmic examination before starting antimalarial treatment on August 10th, 1999. The patient weighed 60 kg and was 165cm tall. Best corrected visual acuity was 4/10 at the right eye due to amblyopia (esotropia since childhood) and 10/10 at the left eye. Color vision was normal with Ishiara color plates. Baseline 10/2 visual field testing was done (which was normal) and the patient was called for follow up annually. Unfortunately the patient did not show up for 3.5

years and came back in September, 2002 with the complaint of a blind spot in the center of vision. She had been taking a daily dose of 500 mg of chloroquine (8.3 mg/kg/day) for 3 years and a daily dose of 250 mg of hydroxychloroquine (3.33 mg/kg/day) for 4 months. BCVA was 0.3 at the right eye and 0.6 at the left eye. Bilateral pericentral scotoma were also demonstrated by Amsler grid testing (Figure 4). Color vision was deteriorated, according to the Ishiara color plates. Fundoscopic examination showed bilateral Bull's eye maculopathy pattern (Figure 5) and the drug was discontinued. During the 5 months follow up, deterioration of visual function continued and BCVA were stabilized at the level of 1/10 bilaterally.

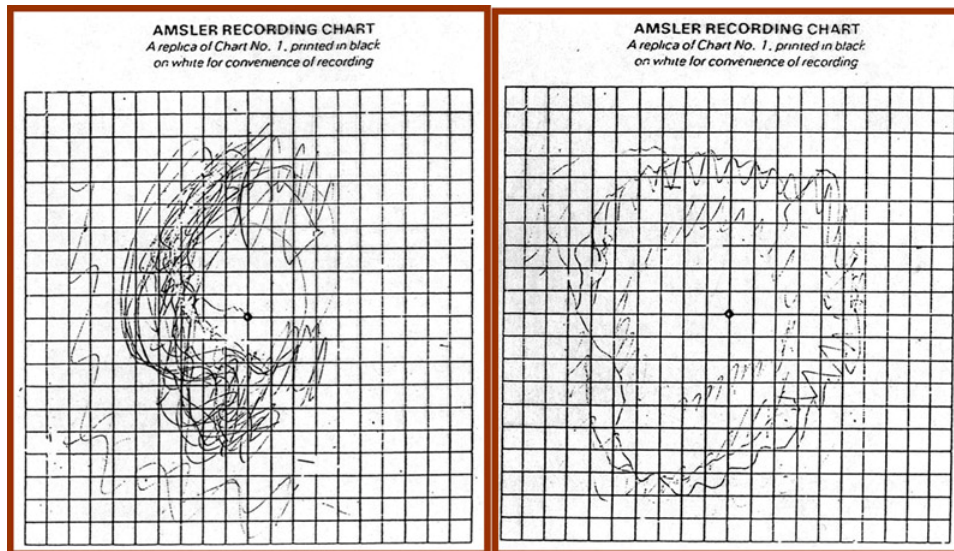


Figure 4. Case 2: Amsler chart. The patient was describing a central scotoma in her central visual field bilaterally.

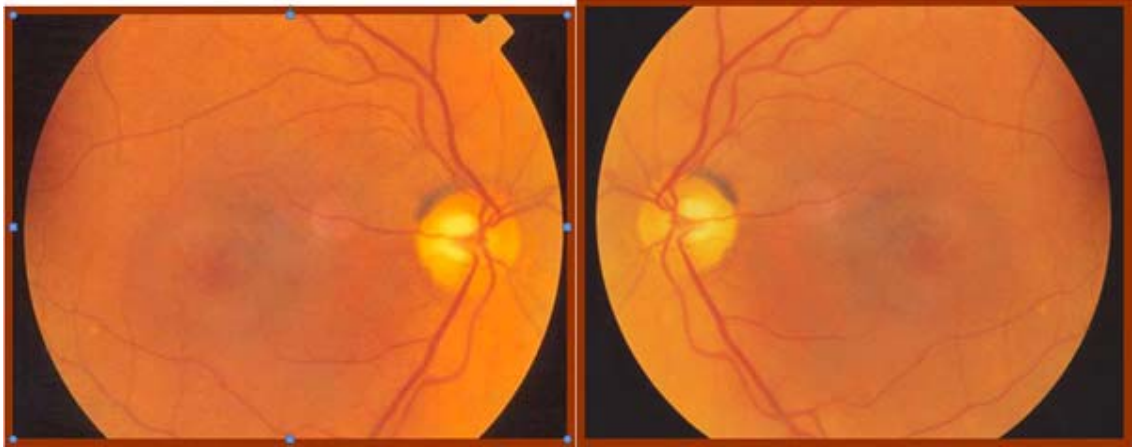


Figure 5. Case 2. Fundoscopic examination showed Bull's eye maculopathy.

DISCUSSION

Chloroquine and Hydroxychloroquine are widely used drugs in the treatment of rheumatoid diseases, and they might cause serious retinal toxicity, when used in high doses and taken for a long period of time. The most recently published guidelines by the American Academy of Ophthalmology (AAO) committee describe two patient groups: low and high risk patients. The level of risk for patients receiving antimalarials is determined by patient-related factors and the amount and duration of drug usage (Table 1)¹. Patients should have a complete baseline ophthalmic examination within the first year of treatment and not necessarily before starting treatment. The first investigation must include retinal examination through a dilated pupil and testing of

central visual field sensitivity by Amsler grid or Humphrey 10-2 testing¹. If the patient is in a low risk category and the examination results are normal, no further ophthalmologic testing is needed for the next 5 years. For patients in a high risk category annual eye examinations are recommended. Studies performed on patients using Chloroquine and Hydroxychloroquine revealed that the daily doses are more important than the cumulative dose²⁻⁴. It should be explained to patients that toxicity is unlikely but not impossible in the first five years of usage. Although the AAO suggest that color vision testing be optional, Easterbrook published that it is a very useful test to detect early maculopathy³. Easterbrook also recommended Humphrey 10-2 visual field testing, only if the best visual acuity is not 6/6, color vision is disturbed or if the patient is symptomatic³.

Characteristics	Low risk	High risk
Dosage mg/kg		
Hydroxychloroquine	<6.5	>6.5
Chloroquine	<3.0	>3.0
Duration of use, yr	<5	>5
Habitus	Lean	Higher fat level
Renal/ liver disease	None	Present
Concomitant retinal disease	None	Present
Age, yr	<60	>60

There is no consensus in different parts of the world about the screening frequency for “high risk” or “low risk” patients, and there is no standard test for screening to detect early maculopathy¹⁻⁹. But there is a world wide acceptance in the description of low or high risk patients and we also use the same terminology in our clinic. The Royal College of Ophthalmologists guidelines recommend a baseline ophthalmic examination including best corrected visual acuity, funduscopy, and a central visual field test⁸. Patients should be warned to report any visual disturbance and may be given an Amsler chart to use monthly. No further ophthalmic examination is needed unless the patient is symptomatic⁸.

The most frequently used follow up tests are Amsler grid and 10/2 visual field testing which concern examination of the macula. However, some centers use 40/2 visual field testing for follow up, as was the situation in Case 1. There are also some new tests mentioned in the literature, pointing to early detection of maculopathy, such as multifocal ERG (mfERG), high speed ultra high resolution optical coherence tomography (hsUHR-OCT) and blue-yellow perimetry. The sensitivity and specificity of these tests are not yet known and the availability and interpretation of these test results are a great concern⁹⁻¹¹.

The two cases of advanced maculopathy mentioned here were diagnosed during a 5 year period (5 years and 3 months in Case 1; 3 years and 4 months in Case 2). These cases are both established maculopathy cases, where toxicity possibly started months before the diagnosis. In Case 1, the test results were misinterpreted by the patient's rheumatologist and she should have been referred to an ophthalmologist. In Case 2, the patient was poorly informed about the importance of follow up procedures. The information procedure should be done more seriously. We are now preparing a more detailed “patients' informed consent form” in our clinic and we are going to publish the results of our clinical protocol which was prepared in accordance with the screening methods mentioned in studies from our country^{12,13}.

Although the mentioned doses are monitored and most patients are under control, there are still some patients suffering from retinopathy. Since 2002, 16 more cases have been reported in the literature, suffering from antimalarial retinopathy. We now add two more cases to these¹⁴.

Advanced cases of maculopathy have been considered rare, but still continue to be diagnosed in the community. Thus, we still need better screening protocols and we still need to find better ways to inform patients about the first signs of maculopathy to eliminate this irreversible but preventable dramatic result.

REFERENCES

1. Marmor FM. New American Academy of Ophthalmology recommendations on screening for hydroxychloroquine retinopathy. *Arthritis Rheum* 2003 Jun;48(6):1764. doi: 10.1002/art.10980
2. Browning DJ. Hydroxychloroquine and chloroquine retinopathy: screening for drug toxicity. *Am J Ophthalmol*. 2002;133: 649- 656. doi: 10.1016/S0002-9394(02)01392-2
3. Easterbrook M. Screening for antimalarial toxicity: current concepts. *Can J Ophthalmol*. 2002; 6:325- 328.
4. Tehrani R, Ostrowski RA, Hariman R, Jay WM. Ocular toxicity of hydroxychloroquine. *Semin Ophthalmol*. 2008; 23 :201- 209. doi: 10.1080/08820530802049962
5. Rigaudière F, Ingster-Moati I, Hache JC, Leid J, Verdet R, Haymann P, Rigolet MH, Zanlonghi X, Defoort S, Le Gargasson JF: Updated ophthalmological screening and follow up management for long term antimalarial treatment. *J Fr Ophthalmol* 2004; 27:191- 199.
6. Rütter K, Foerster J, Berndt S, et al. Chloroquine/hydroxychloroquine:variability of retinotoxic cumulative doses. *Ophthalmologie* 2007;104:875-879. doi: 10.1007/s00347-007-1560-7
7. Pluta JP, Rütter K. Retinal damage by (hydroxyl)chloroquine intake:published evidence for an efficient ophthalmological follow-up. *Klin Monbl Augenheilkd* 2009;226:891-896. Epub 2009 Nov. 13. doi 10.1055/s-0028-1109881
8. Blyth C, Lane C: Hydroxychloroquine retinopathy:is screening necessary? *BMJ*. 1998; 316 :716– 717
9. Gilbert ME, Savino PJ: Missing the bull's eye. *Surv Ophthalmol* 2007; 52 :440- 442.
10. Rodriguez-Padilla JA, Hedges TR 3rd, Monson B, Srinivasan V, Wojtkowski M, Reichel E, Duker JS, Schuman JS, Fujimoto JG: High speed ultra high resolution optical coherence tomography findings in hydroxychloroquine retinopathy. *Arch Ophthalmol* 2007; 125: 775- 780.
11. Razeghinejad MR, Torkaman F, Amini H: Blue yellow perimetry can be an early detector of hydroxychloroquine and chloroquine retinopathy. *Med Hypotheses* 2005; 65 :629- 630. doi: 10.1016/j.mehy.2005.04.005
12. Gündüz K, Okka M, Zengin N, Okudan S, Özbayrak N,Acaroğlu Ş. Klorokin tedavisinde retina toksitesinin araştırılması. *T Klin Oftalmoloji* 1995; 4: 47-51.
13. Köse S, Akkın C, Ya_ cı A, Ate_ H,Haznedaro_lu G. Klorokin retinopatisinin saptanması ve izlenmesinde kullanılan yöntemlerin etkinliği. *MN Oftalmoloji* 1993; 2: 299-301.
14. Herman K, Leys A,Spileers W: Hydroxychloroquine retinal toxicity: two case reports and safety guidelines. *Bull Soc Belge Ophthalmol* 2002; 284: 21- 29.