

## Case Report / Olgu Sunumu

# Tuba-Ovarian Inguinal Herniation after Radiological Percutaneous Treatment of Inguinal Lymphocele; A Case Report and Review of the Literature

## *Inguinal Lenfoselin Radyolojik Perkütan Drenajı Sonrası Tuba Ovarian İnguinal Herniasyon; Olgu Sunumu ve Literatürün Gözden Geçirilmesi*

Melih AKINCI, Kerim Bora YILMAZ, Celil UĞURLU, Hakan KULAÇOĞLU

*Dışkapı Yıldırım Beyazıt Eğitim ve Araştırma Hastanesi, 4. Genel Cerrahi Kliniği, Ankara, Türkiye*

### ABSTRACT

In this case report, we describe an unusual tuba-ovarian inguinal herniation after percutaneous inguinal lymphocele treatment which is a rare condition after a radiological intervention. Lymphocele and other cystic structures of the groin are reviewed within the differential diagnosis

**Keywords:** Lymphocele, Inguinal Herniation, Percutaneous Drainage

### ÖZET

Çok nadir görülen inguinal lenfoselin girişimsel radyoloji tarafından perkütan drenajı sonrası oluşan tuba ovarian inguinal herniasyon olgusu sunulmuştur. Ayırıcı tanıda kasık bölgesinin lenfoseli ve diğer kistik oluşumları gözden geçirilmiştir.

**Anahtar Kelimeler:** Lenfösel, İnguinal Herniasyon, Perkütan Drenaj

### INTRODUCTION

The groin hernia sac generally contains structures such as ileum, jejunum, colon, omentum and infrequently unusual structures are contents of the hernial sac such as vermiform appendix, ovary, fallopian tube and, urinary bladder<sup>1</sup>. Most of the hernias containing ovary and fallopian tubes were reported to be found in children and, often accompanied with other congenital anomalies of the genital tract<sup>2</sup>.

Lymphocele is a cystic structure that occurs after surgical interventions in areas with an extensive lymphatic network due to injury to the lymphatic vessels<sup>3</sup>. In this case report, we describe an unusual tuba-ovarian inguinal herniation after percutaneous lymphocele treatment which is a very rare condition after a radiological intervention. Lymphocele and other cystic structures of the groin are reviewed within the differential diagnosis.

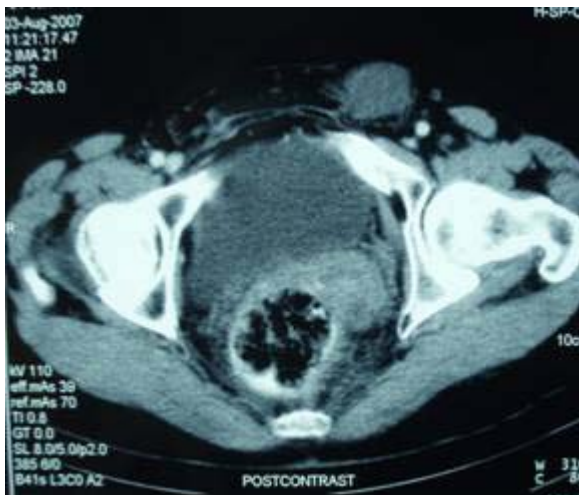
### CASE REPORT

A 46-year old, premenopausal woman was admitted to our clinic with a left inguinal painful swelling. She was married and had two children, delivered by normal vaginal births, with ages 14 and 7. She had a history of right and left inguinal hernia repairs fourteen years and twelve years ago respectively. Two years ago, she realized a left inguinal painless swelling and a lymphocele was the presumed diagnosis when ultrasound showed a 4x3cm fluid collection. Inguinal lymphocele was revealed with computerized tomography (Figure 1), and was primarily treated with percutaneous drainage. She did not have leukocytosis and all the laboratory tests were in normal range. Drainage specimen cytological examination reported as benign cytology with monocyte, macrophage serial cells, lymphocyte cells, plasma cells and reactive mesothelial cell that was harmonious with the lymphocele diagnosis. Cultures were negative.

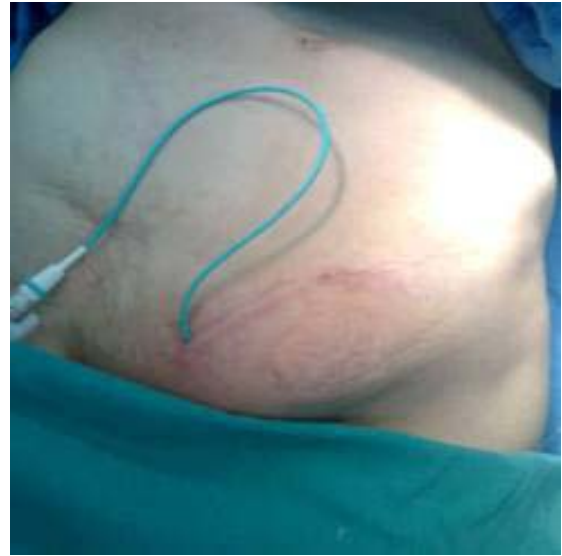**Başvuru tarihi / Submitted:** 19.05.2010 **Kabul tarihi / Accepted:** 09.11.2010

**Correspondence to:** Melih Akinci, M.D. Dışkapı Yıldırım Beyazıt Eğitim ve Araştırma Hastanesi, 4. Genel Cerrahi Kliniği, Ankara, Türkiye e-mail: melihakinci@yahoo.com

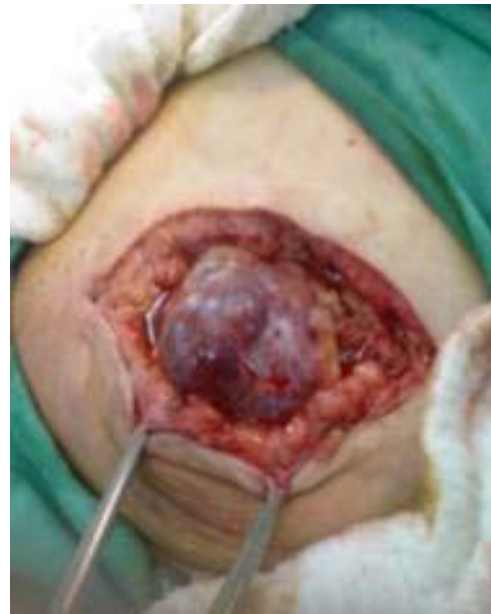However, it relapsed one month later and it was treated with drainage and sclerotherapy. She had no complaints for a period of two years. The next presentation was again a left inguinal painless swelling which was controlled with ultrasound that revealed 5x4x3cm fluid collection at the same location and this collection was diagnosed as the lymphocele relapse. The Radiology Department performed the same treatment of percutaneous drainage and sclerotherapy. The control pouchography did not show any extravasations. The patient was discharged two days after sclerotherapy with the drainage catheter. The outpatient follow up of catheter drainage volumes were 40ml, 40ml, 30ml, 40ml and 30ml for five days respectively so the catheter was not pulled out because of drainage flow was over 20ml per day. The patient was admitted to our clinic with a new painful left sided swelling of groin at the seventh day of lymphocele treatment (Figure 2). The ultrasonographic control revealed 35x 20mm of inguinal herniation sac. Surgery was planned because of severe pain at the physical examination and high drainage of lymphocele catheter. The area was explored, with presumed diagnosis of inguinal herniation. At exploration torsion of the ovary and fallopian tubes were found in the hernia sac (Figure 3-5). The both structures were ischemic, necrotic and edematous so salpingoophorectomy was performed. Hernia repair was performed after lymphocele cavity had been obliterated. Post surgical course was uneventful and she was discharged at the second postoperative day. Pathological examination of the specimen was reported as ischemic necrotic fibro adipose tissue and intraovarian hemorrhage with edema. Eight months after surgery her control was normal and she had no complaint.



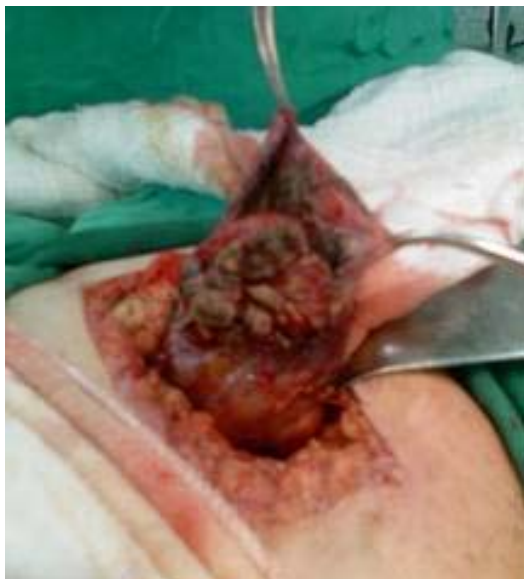**Figure 1:** Image of recurred inguinal lymphocele on computerized tomography



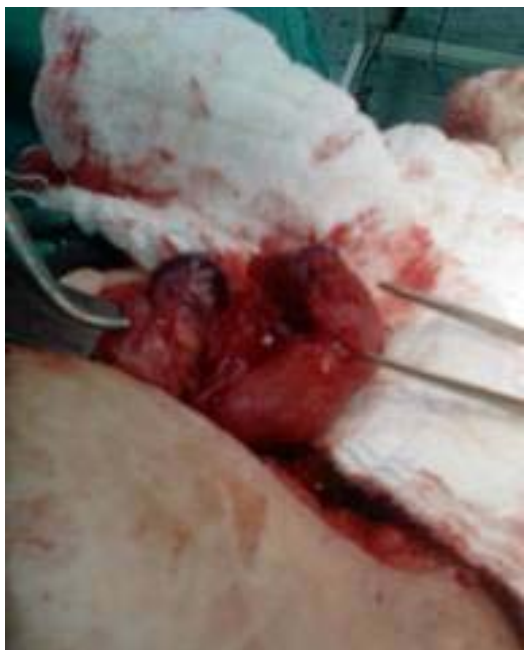**Figure 2:** Left sided swelling of groin at the seventh day of lymphocele treatment



**Figure 3:** Left groin hernia sac



**Figure 4:** The contents of the sac were ischemic, necrotic and edematous



**Figure 5:** At exploration the ovary or fallopian tube were in the hernia sac

## DISCUSSION

The inguinal canal in the female normally gives passage to the round ligament of the uterus, a vein, an artery from the uterus that forms a cruciate anastomosis with the labial arteries, and extraperitoneal fat<sup>2</sup>. The fetal ovary, like the testis, is an abdominal organ and possesses a gubernaculum that extends from its lower pole downward and forward to a point corresponding to the abdominal inguinal ring, through which it continues into the labia majora. Instead of descending, as does the testis, the ovary moves medially, where it becomes adjacent to the uterus<sup>2</sup>. The development of indirect inguinal hernias is

simply explained by prolapse of any intraabdominal organ through the inguinal ring together with round ligament. Swelling of the inguinal region in a female may result from a number of conditions, including inguinal hernia, tumor (lipoma, leiomyoma, sarcoma), cyst, abscess, lymphocele, lymphadenopathy, or a hydrocele<sup>4</sup>. In this report solid tumors and lymphadenopathy was excluded with ultrasonography and abscess also excluded by clinic, history and cytological examination.

Albeit very uncommon, a hydrocele of the canal of Nuck has to be included in the differential diagnosis of a groin lump in female patients. Hydrocele is located in the canal of Nuck which is the portion of the processus vaginalis within the inguinal canal in women. Indeed a hydrocele of the canal of Nuck is equivalent to an encysted hydrocele of the cord in men. If the processus vaginalis does not close, it is referred to as a patent processus vaginalis. Its size will allow fluid or abdominal organs to pass so that the condition will lead to hydrocele or hernia respectively. The literature reveals very little about hydrocele in the adult female patient. Several pediatric cases have been reported in the literature and Wei et al. reported one case in an adult woman as in our case<sup>5</sup>. Hydrocele typically presents as a painless, translucent swelling in the inguinolabial region and there is no nausea or vomiting that is similar to this case report. It is also important to know that a hydrocele can also occur with local inflammation of the sac and cause nausea, vomiting, pain and even leukocytosis, making diagnosis more difficult<sup>5</sup>.

However, the patient in this case report was adult and had a history of inguinal hernia repair when she was 34 years old. Although we do not have information about what kind of hernia repair had been performed, there was high probability of obliteration of the patent processus vaginalis at the herniotomy that diagnosis of hydrocele in this adult patient was not plausible. The treatment of the hydrocele of the canal of Nuck is complete surgical resection. As there is a high association of inguinal hernias, dissection to the internal inguinal ring and ligation of the neck of the processus vaginalis should be performed<sup>4</sup>. Aspiration does not result in cure because the recurrence is high and injection therapy has no place in the treatment<sup>4,6</sup> that altogether same treatment modality was also performed and was effective in this reported case.

On the other hand ultrasonographic description of hydrocele is a comma-shaped lesion with its tail directed toward the inguinal canal and cyst within a cyst appearance which the fluid-filled canal collapsed during Valsalva's maneuver while the cyst came closer to the abdominal cavity that differs with the discussing case<sup>7</sup>.

We also have to discuss about the possibility of the late complications of the hernia repair. The female patient in this case report had a left painless groin lump that had a history of inguinal hernia repair 12 years ago. Ultrasound revealed a cystic structure. After percutaneous sclerotherapeutic drainage, inguinal hernia recurred and the hernia sac contained the torsion of the fallopian tube and

the ovary. Indeed female patients especially young ones have a high incidence of injury to the ovary and fallopian tube that had herniotomy in the hands of unwary surgeons<sup>8</sup>. However, the patient of this case report was 34 years old at her left hernia repair and she had only painless groin lump till to the time of percutaneous sclerotherapeutic drainage. Besides she had a history of right inguinal hernia 14 years ago and normal vaginal births 7 and 14 years ago that she had been controlled several times and gynecologic ultrasonography at least two times had been performed seven years ago.

Without dispute the most common abnormality in the groin is a hernia, which contains bowel loops, omental fat, and peritoneal fluid. Routine ultrasound had been advised to discover the contents of the hernia sacs before performing herniotomy especially on children in order to decrease the risk of injury to these organs<sup>8</sup>. In this case ultrasound revealed no vascular activity, no communication with the peritoneum and no peristaltic activity was observed. The possible diagnosis from the ultrasound findings included fluid in a relapsed inguinal hernia or a lymphocele, or a sterile collection of fluid associated with a past inflammatory episode. Indeed there are various cystic masses involving the female groin, such as round ligament cysts, varicosities of the round ligament, inguinal herniation of the ovary, cystic lymphangiomas, epidermal inclusion cysts, abscesses, and pseudoaneurysms so that sonography is helpful for the differential diagnosis of the pathologic spectrum of cystic masses involving the female groin<sup>9</sup>. Ultrasound is a cheap and easy to perform complementary radiological exam to confirm the cystic nature of the lesion. Therefore, we used the sonography as the first step to evaluate the groin lump and follow up of the cystic lesion.

After all discussion, we agree that the most probable diagnosis of this case was a lymphocele. This diagnosis was supported with age, previous herniorrhaphy history, normal leukocyte count, cystic ultrasonographic image, negative cultures and consistent cytology examination of aspirated cystic fluid. A lymphocele, also known as a lymphocyst, is a collection of lymphatic fluid occurring as a consequence of surgical dissection and inadequate closure of afferent lymphatic vessels. Generally pelvic lymphocele has been described that is caused by lymphatic injury usually secondary to pelvic lymphadenectomy and renal transplantation. Trauma is also a factor for formation of lymphocele for all localizations but in literature there have been few reports of lymphocele which was primary as a pelvic one in a pregnant woman<sup>10</sup> and the other one was cervical localization<sup>11</sup>. However, in the present case, no etiologic factor was apparent except the same sided groin hernia repair twelve years ago. To our literature search, this is the first reported case of primary groin lymphocele or late complication of groin hernia repair as a lymphocele.

Lymphoceles can cause morbidity and rarely mortality by compression of adjacent structures and infectious complications. Treatment alternatives for lymphoceles include surgical

marsupialization by open or laparoscopic surgery or percutaneous catheter drainage. Selection of treatment method currently depends on institutional preferences<sup>10</sup>. Open surgery and peritoneal marsupialization can be used for the treatment of lymphoceles with good success rates; however, long hospital stay, mortality and morbidity due to surgery preclude use in all patients. Therefore, percutaneous catheter drainage with sclerosing agents should be considered as the first-line treatment for pelvic lymphoceles as it is a safe and effective procedure with a high success rate<sup>12</sup>. Algorithm shift that had occurred in the treatment of intraabdominal abscess is happening in the treatment of pelvic lymphoceles and interventional radiological treatments are becoming a robust treatment option for pelvic lymphoceles<sup>10</sup>. However there have been possible complications for percutaneous drainage interventional radiological treatments as bleeding, perforation, peritonitis, fistula etc. In literature only a single case of vesicolymphocele fistula has been reported after ethanol sclerotherapy for percutaneous lymphocele treatment<sup>13</sup>. Inguinal herniation as a complication of percutaneous drainage of lymphocele in our case was a rare condition and tuba ovarian herniation in inguinal sac after percutaneous lymphocele drainage was also an unusual clinical entity.

The hernia sac may contain structures such as ileum, jejunum, colon, omentum, vermiform appendix, acute appendicitis, Meckel's diverticulum, stomach, ovary, fallopian tube and, urinary bladder<sup>1</sup>. Most of the cases of hernia containing ovary and fallopian tubes were reported to be found in children and, often accompanied with other congenital anomalies of genital tract. An article from Nigeria researched inguinal hernias in female children and reported the content of the hernia sacs as 46.6% ovary, 24.4% ovary and fallopian tube, 11.5% fallopian tube, 11.9% peritoneal fluid alone, 3.9% omentum and 1.7% loop of bowels<sup>8</sup>. The presented case is an adult patient whose inguinal hernia contained ovary and the fallopian tube which is unusual for adult patient and is also the first reported one which was due to the radiological intervention as percutaneous sclerotherapeutic lymphocele treatment.

Torsion of the ovary or fallopian tube is a rare acute gynecological disorder with an incidence of 3% in a series of acute gynecological complaints and diverse clinical presentation, the diagnosis is frequently missed at first presentation<sup>14</sup>. Although for the preservation of ovarian function it is of utmost importance to diagnose an ovarian torsion at an early stage, treatment policy will differ depending on the stage of life. We agree with that salpingoopherectomy was a good treatment choice as in our case who was in fifth decade of life with the ischemic condition.

We present this unusual acute groin hernia, containing the ovary and the fallopian tubes after percutaneous lymphocele treatment because of its rarity and want to remind the possible conditions of inguinal lump and lymphocele with brief summary of literature.

## REFERENCES

1. Gurer A, Ozdogan M, Ozlem N, et al. Uncommon content in groin hernia sac. *Hernia* 2006;10:152-5.
2. Ozkan OV, Semerci E, Aslan E, et al. A right sliding indirect inguinal hernia containing paraovarian cyst, fallopian tube, and ovary: a case report. *Arch Gynecol Obstet* 2009;279:897-9.
3. Shih J, Trerotola SO, Itkin M. The lymphocele PILL: a case report of percutaneous imaging-guided lymphatic ligation for the treatment of postsurgical lymph collections. *J Vasc Interv Radiol* 2008;19:1781-4.
4. Anderson CC, Broadie TA, Mackey JE, et al. Hydrocele of the canal of nuck: ultrasound appearance. *Am Surg* 1995;61:959-61.
5. Wei BPC, Castles L, Stewart KA. Hydroceles of the canal of nuck. *A N Z J Surg* 2002;72:603-6.
6. Block RE. Hydrocele of the canal of Nuck. A report of five cases. *Obstet. Gynecol* 1975;45:464-6.
7. Safak AA, Erdogmus B, Yazici B, et al. Hydrocele of the canal of Nuck: sonographic and MRI appearances. *J Clin Ultrasound* 2007;35:531-2.
8. Osifo OD, Ovueni ME. Inguinal hernia in Nigerian female children: beware of ovary and fallopian tube as contents. *Hernia* 2009;13:149-53.
9. Oh SN, Jung SE, Rha SE, et al. Sonography of various cystic masses of the female groin. *J Ultrasound Med* 2007;26:1735-42.
10. Ikeda T, Miyauchi Y, Nishio S, et al. Primary retroperitoneal lymphocele in a pregnant woman: the first report. *Int J Urol* 2006;13:445-6.
11. Hekiert A, Newman J, Sargent R, et al. Spontaneous cervical lymphocele. *Head Neck* 2007;29:77-80.
12. Karcaaltincaba M, Akhan O. Radiologic imaging and percutaneous treatment of pelvic lymphocele. *Eur J Radiol* 2005;55:340-54.
13. Oh SJ, Kim SH, Kim HH. Vesicolymphocele fistula following sclerotherapy for lymphocele. *J Urol* 2004;172:2266.
14. Becker JH, Graaff JD, Vos CM. Torsion of the ovary: a known but frequently missed diagnosis. *Eur J Emerg Med* 2009;16:124-6.