



CASE REPORT

TREATMENT OF SYNCRONEOUS TRIPLE GENITOURINARY TUMOR WITH LAPAROSCOPIC NEPHROURETERECTOMY AND CONVENTIONAL RADICAL CYSTOPROSTATECTOMY

Hasan H. Tavukcu¹, Cem Akbal¹, Suheyla U. Bozkurt², Levent Türkeri¹

¹Marmara Üniversitesi, Tıp Fakültesi, Üroloji, İstanbul, Türkiye ²Marmara Üniversitesi Tıp Fakültesi, Patoloji, İstanbul, Türkiye

ABSTRACT

Synchronous triple primary tumor occurring in the kidney, urinary bladder and prostate is a very rare condition in the practice of Urology. We have reported combined laparoscopic nephroureterectomy with a standard open radical cystoprostatectomy as an effective and reliable operation technique in patients with triple genitourinary tumors and high-risk co-morbidities.

Keywords: Triple tumor, Laparoscopy, Treatment

SENKRONİZE ÜÇLÜ GENİTOÜRİNER SİSTEM TÜMÖRÜNÜN LAPAROSKOPİK NEFROÜRETEREKTOMİ VE STANDART RADİKAL SİSTOPROSTATEKTOMİ İLE TEDAVİSİ

ÖZET

Aynı anda böbrek, mesane ve prostat da tümör saptanması ürolojide nadir karşılaşılan bir durumdur. Bu çalışma aynı seansta uygulanan laparoskopik nefroüretrektomi ve standart açık radikal sistoprostatektominin üçlü genitoüriner sistem tümörü olan yüksek riskli olgularda uygulanabileceğini göstermektedir.

Anahtar Kelimeler: Üçlü tümör, Laparoskopi, Tedavi

INTRODUCTION

Synchronous triple primary tumor occurring in the kidney, urinary bladder and prostate is a very rare condition in the practice of Urology. Most synchronous triple urogenital tumors have been reported by Japanese uro-oncologists¹. According to the review of Takada et al., ten cases of triple urogenital tumor have been reported in Japan until 2002¹. Herein, we present an end-stage renal failure patient with synchronous triple primary tumor occurring in the kidney, urinary bladder and prostate, treated with

laparoscopic radical nephroureterectomy and a standard approach cystoprostatectomy without the occurrence of urinary diversion.

CASE REPORT

A 62-year-old male patient with known coronary artery disease, who was being followed on a chronic dialysis program, admitted to the emergency room with gross hematuria. The digital rectal examination was normal and the PSA value was 1,52 ng/mL. Ultrasound revealed a 4 cm solid mass at the left postero-lateral wall of the bladder and

İletişim Bilgileri:

Hasan H. Tavukcu, M.D.

Marmara Üniversitesi Tıp Fakültesi, Üroloji, Altunizade, İstanbul, Türkiye

e-mail: cakbal@gmail.com

Marmara Medical Journal 2009;22(1);049-051



Grade III hydronephrosis of the left kidney with 3-4 mm parenchymal thickness. Cystoscopy revealed that the patient had a 5 cm solid papillary tumor at the left posterolateral wall of the bladder. The patient underwent an incomplete transurethral resection of the bladder tumor. Pathology report revealed a pT1 Grade III tumor. The patient underwent an abdominopelvic computed tomography (CT) without contrast material and chest x-ray. The CT revealed a suspicious mass in the left distal ureter and the left bladder wall had a huge solitary mass. There was no evidence of metastatic disease or lymphadenopathy. The left kidney was tumor free (Figure IA-B). We discussed treatment options with the patient and decided to perform a laparoscopic radical nephroureterectomy due to the left distal ureter tumor and conventional radical cystoprostatectomy without creating a urinary diversion, because he was on a chronic dialysis program. A left radical nephroureterectomy was performed via a four port transperitoneal approach and the left ureter was mobilized and divided. A radical cystoprostatectomy with a bilateral extended pelvic lymph node dissection was performed

using a standard approach. The right renal unit and ligated right ureter were left within the patient. The operation time was five hours with blood loss of 500 cc. There were no intra or postoperative complications and the patient was discharged on postoperative day four.

A pathology report revealed a synchronous triple tumor in the kidney, urinary bladder and prostate. The kidney pathology revealed a 1.2 cm tubular-type clear cell renal cell carcinoma at the left lower pole, pT1N0 with Fuhrman Grade 2. Bladder pathology revealed a high-grade invasive urethelial carcinoma with carcinoma in-situ, stage PT2bN0. Prostate pathology revealed a prostatic adenocarcinoma composed of small atypical glands with a Gleason score of 3+3 (Figure IIA-B-C). This diagnosis was confirmed by negative staining of the neoplastic glands with high molecular weight cytokeratin immunohistochemistry (34E12). The lymph nodes were tumor free. Control MRI sections did not reveal any tumor recurrences or late complications during the follow-up period of the patients and he did not receive any adjuvant treatment modality.

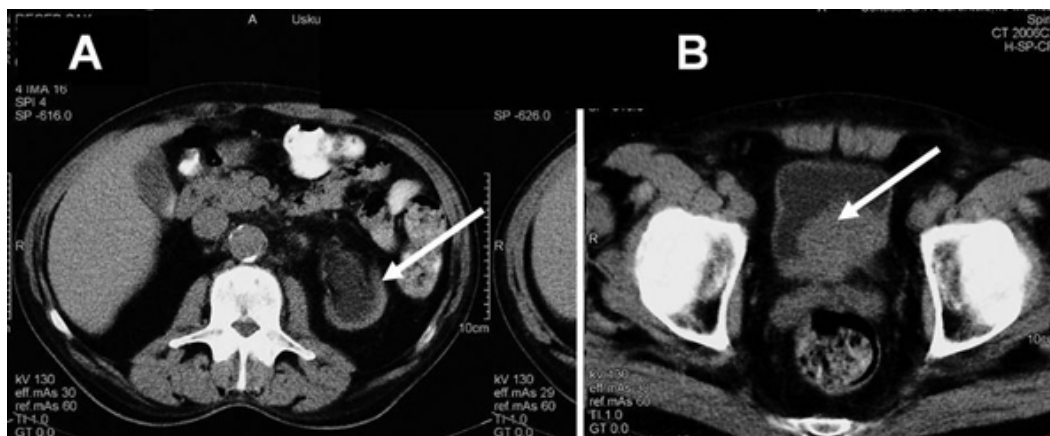

Figure I A-B: CT scan of kidney and bladder

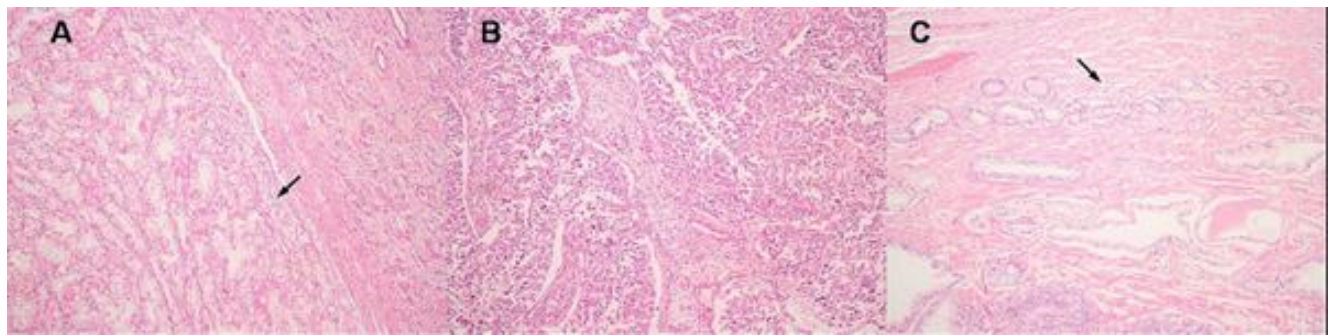


Figure II: A-B-C: II A Clear cell renal cell carcinoma with tubular pattern (arrow) surrounded with adjacent renal parenchyma (H&E, x100)

II B: High grade urothelial cell carcinoma showing disordered architecture and nuclear pleomorphism (H&E, x 100).

II C: Prostatic adenocarcinoma composed of small atypical glands (arrow) (H&E, x 100)

DISCUSSION

Both the conventional and laparoscopic approach in urology is now an acceptable option for kidney, bladder and prostate surgery, with excellent functional and oncological outcomes².

Deng et al. reported simultaneous laparoscopic management of three urological malignancies³. Japanese uro-oncologists prefer a standard approach open radical nephroureterectomy with a hilar lymph node dissection and total cystoprostatectomy with a pelvic node dissection as the radical treatment for their patients. In our case, we decided to perform a laparoscopic radical nephroureterectomy via the four port transperitoneal approach, and a standard, open, radical cystectoprostatectomy with a pelvic lymph node dissection, without urinary diversion. Although our patient's age was 62, he had multiple co-morbidities, including chronic renal failure and coronary artery disease. Therefore, reducing the operation time with minimal morbidity was the main factor for choosing this operation combination for our patient. Although the operation time was five hours in our case, eleven hours with 800 ml of blood loss were reported by Deng et al. for patients who underwent combined laparoscopic radical nephrectomy,

cystoprostatectomy and pelvic lymphadenectomy with the creation of an ileal loop³.

Although the atomic bomb explosions of Hiroshima and Nagasaki have been shown as responsible factors for synchronous multiple tumors in the Japanese population, the only nuclear event that would have affected the Turkish population happened in 1986 in Chernobyl, near the north-eastern area of Turkey. Our patient's hometown was on the north side of Turkey. However, he had not visited his hometown since 1970.

Combined laparoscopic nephroureterectomy with a standard open radical cystoprostatectomy is both an effective and reliable operation technique in patients, like our patient, with triple genitourinary tumors and high-risk co-morbidities.

REFERENCES

1. Takada T, Honda M, Momohara C, Komori K, Fujioka H. Synchronous triple urogenital cancer (renal cancer, bladder cancer, prostatic cancer): a case report] *Hinyokika Kyo* 2002 ;48(4):239-342
2. Hasan WA, Abreu SC, Gill IS. Laparoscopic surgery for renal cell carcinoma. *Expert Rev Anticancer Ther* 2003; 3(6):830-836.
3. Deng DY, Meng MV, Grossfeld GD, Stoller ML. Simultaneous laparoscopic management of 3 urological malignancies. *J Urol* 2002; 167(5):2125-2126.