

## Case Report

### CLOVERLEAF SKULL DEFORMITY

**Ahmet Çolak\* / Murat Kutlay\* / Çınar Başekim\*\*  
Nusret Demircan\* / Arif Bahar\*\*\***

\* M.D., Department of Neurosurgery, Gülhane Military Medical Academy, Haydarpaşa Training Hospital, Istanbul, Turkey.

\*\* M.D., Department of Radiology, Gülhane Military Medical Academy, Haydarpaşa Training Hospital, Istanbul, Turkey.

\*\*\* M.D., Department of Pediatrics, Gülhane Military Medical Academy, Haydarpaşa Training Hospital, Istanbul, Turkey.

#### ABSTRACT

Cloverleaf skull is a rarely seen deformity and the prognosis is poor in untreated cases. The main components of the deformity are hydrocephalus, trilobed head shape, shallow orbits, and midfacial hypoplasia. It may be seen either as an entity or in association with other syndromes, such as Apert's, Crouzon's, Pfeifer's syndromes, and skeletal dysplasias. The presented case is in association with some skeletal anomalies, together with ambiguous genitalia and dermal sinus tract over lumbar spine. As early surgical intervention is suggested to prevent the damages of increased intracranial pressure, we operated the patient on the second day of her life. Although the vital signs of the infant returned to normal limits immediately after the operation, the patient died on the third postoperative day because of diffuse intravascular coagulopathy.

**Key Words:** Cloverleaf deformity, Kleeblattschadel, Craniostenosis, Congenital dislocation of the hip.

#### INTRODUCTION

The name "Kleeblattschadel" or "cloverleaf skull" for the grotesque configuration of trilobar skull was first given by Holtermüller and Wiedemann (1). Major craniofacial manifestations of cloverleaf skull deformity (CSD) were listed as follows: 1. Cloverleaf skull, 2. Severe exophthalmos, corneal ulcerations, hypertelorism and shallow orbits. 3. Downward displacement of the ears, occasionally reaching a

position parallel to the shoulders. 4. Beaked nose with a depressed nasal bridge. 5. Premaxillary and maxillary hypoplasia with relative prognatism and occasionally macrostomia, macroglossia etc. (2,3). Although this deformity can be seen as a single pathology, it may also be seen as an element of a syndrome, or in combination with other skeletal anomalies. CSD is etiologically and genetically heterogeneous and may occur in association with a number of disorders which result from genetic mutations such as hypochondroplasia (4). Prenatal diagnosis of the skull abnormality and accompanying skeletal abnormalities is possible using ultrasonography (5,6).

#### CASE REPORT

This female neonate was born to a 26-year-old gravida I, para 1 woman at 39 weeks of gestation with routine vaginal delivery. The course of pregnancy was uneventful, but an ultrasonographic evaluation two weeks before the delivery revealed an abnormal shape of cranium without any specific diagnosis. The APGAR score of the infant was 10 at birth. The same day she was referred to the Pediatrics and Neurosurgery Departments, for investigation of her apparent craniofacial deformity.

Her weight was 3000 g and head circumference was 39 cm. The trilobed appearance of her skull with bulging of frontal and both temporal regions was diagnosed as "Cloverleaf skull deformity". There was hypertelorism, midfacial hypoplasia and bilateral exophthalmos. Both ears were low-placed and the nasal root was flattened (Figs 1a, b).

# Ülseratif Kolit Tedavisinde Etkili Remisyon **KALICI KORUMA**

**"REMİSYONU ELDEN BIRAKMAYIN"**

 **Dipentum**<sup>®</sup>  
(olsalazin)

Dipentum® 250 mg kapsül FORMÜLÜ: Her kapsülde 250 mg olsalazin sodyum bulunur. ENDİKASYONLARI: Akut ülseratif kolit tedavisinde özellikle sulfasalazine karşı intolerans ya da aynı duyarlılık gören hastalarda kullanılır. KONTRENDİKASYONLARI: Salisilatları aynı duyarlı olan hastalarda kontrendikedir. UYARILAR - ÖNLEMLER: Çocuklar, Gebeler ve Emzirenler için Özel Uyarılar: Deneysel hayvanları üzerinde yapılan araştırmalarda fetus üzerinde herhangi bir zarar etkisi saptanmamıştır. İnsanlarda benzer araştırmalar yapılmamıştır. Gebelikte kullanılması gerekli görüldüğü takdirde ilaçtan beklenen yarar ve fetus üzerine muhtemel zarar gözönüne alınmalıdır. Olsalazin süte geçip geçmediği bilinmemektedir. Pediatride etki ve güvenliği henüz yeterince araştırılmamıştır. YAN ETKİLER: ADVERS ETKİLER: Klinik araştırmalarda en sık karşılaşılan yan etkiler şunlardır: Diyare, şunmak dışkı, baş ağrısı, karın ağrısı, bulantı, midede rahatsızlık hissi, deri döküntüleri ve ekim ağrıları. Diyare: İlaç başlangıcında relapsın kontrolüne yol açabilir. BELİRTİLEN BİR ETKİ GÖRÜLDÜĞÜNDE DOKTORUNUZA BAŞVURUNUZ. İLAÇ ETKİLEŞİMLERİ VE DİĞER ETKİLEŞİMLER: Olsalazin varfarin ile birlikte kullanıldığında protrombin zamanının uzayabildiği bildirilmiştir. KULLANIM ŞEKLİ VE DOZU: Doz vemeçlerle birlikte alınmalıdır. Erşenler: Akut ülseratif kolit tedavisinde günlük doz 6-8 kapsüldür. Bu doz 3 veya 4'e bölünerek alınır. En çok günlük doz 3 gramdır. Ancak bir kerede verilen doz 1 gramı 4 kapsül aşmamalıdır. Yan etkilerin ortaya çıkması olasılığı azaltılmak için tedavide düşük dozlarla başlanması önerilebilir. Örneğin günde 2 kapsül. İdame tedavisinde 12 saatte bir 2 kapsül/günde toplam 4 kapsül uygulanır. Kapsüller yemeklerin hemen ardından alınmalı ve uygulama zamanına dikkat edilmelidir. Remisyondaki hastaların idame tedavisinde Erşenler: Önerilen doz günde 1 gramdır. 4 kapsül. Doz bölünerek alınmalıdır. Diyare gelişen hastalarda günlük toplam dozun ilk günlerde daha fazla bölünerek alınması 3-4 saatte bir günde gerekebilir. Yaşlılara da erişkin dozu uygulanır. DOZ AŞIMI HALİNDE ALINACAK ÖNLEMLER: Olsalazinin özel bir antidotu yoktur. Hasta vakitten itibaren ve gerekirse semptomatik tedavi uygulanmalıdır. SAKLAMA KOŞULLARI: İvi kapalı ve kapalı kaplarda kuru bir yerde 15°-30°C arasında saklanmalıdır. Raf ömrü 5 yıldır. Doktora danışmadan kullanılmamalıdır. Çocukların ulaşamayacağı yerlerde ve ambalajında saklanmalıdır. TİCARİ TAKDİM ŞEKLİ VE AMBALAJ MÜHTEFESİ: Her kapsülde 250 mg olsalazin sodyum içeren 100 kapsüllük ambalajlarda



Üretim Yeri  
**Pharmacia  
& Upjohn**

Ruhsat Sahibi  
**Eczacıbaşı İlaç**

Daha fazla bilgi için kuruluğumuza başvurunuz  
**Eczacıbaşı İlaç Pazarlama**  
Buyükdere Cad. 185 80710 Levent-İstanbul

**||Eczacıbaşı**



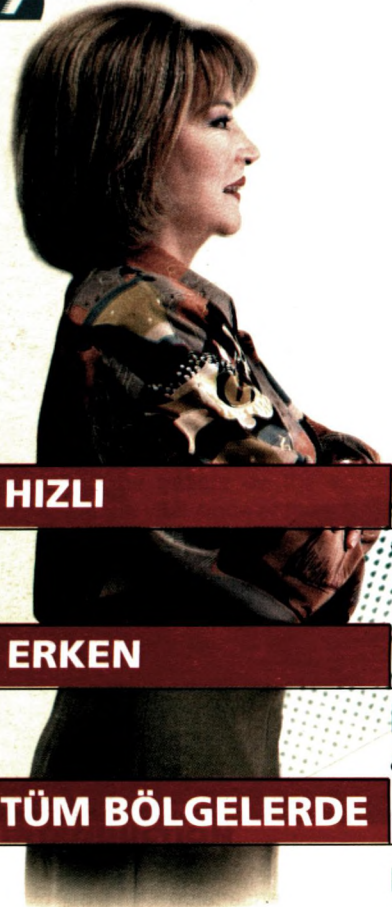# Postmenopozal osteoporozda kırıkların önlenmesini sağlayın.<sup>1</sup>

F  
I  
T

FRACTURE  
INTERVENTION  
TRIAL

F  
O  
S  
I  
T

FOSAMAX  
INTERNATIONAL  
TRIALS



HIZLI

Vertebra dışı kırık insidansını bir yıl içinde **%47** oranında azaltmıştır (p=0,021).<sup>2</sup>

ERKEN

İlk kırık insidansını **%44** oranında azaltmıştır (p=0,001).<sup>2</sup>

TÜM BÖLGELERDE

Kalça kırığı oluşma insidansını **%51** oranında ve diğer kritik osteoporoz bölgelerinde kırık insidansını önemli derecede azaltmıştır (p=0,047).<sup>1</sup>

#### REFERANSLAR

1. Black DM et al for the Fracture Intervention Trial Research Group.

Randomised trial of effect of alendronate on risk of fracture in women with existing vertebral fractures.

Lancet 1996; 348: 1535-1541

2. Data on file, MSD Türkiye.

**GÜNDE BİR KEZ 10 MG FOSAMAX OLARAK REÇETELEYİNİZ.**

Kontrendikasyonlar, uyarılar, önlemler ve yan etkiler ile ilgili detaylı bilgiler için lütfen prospektüse başvurunuz.



**MERCK SHARP & DOHME**

† MERCK & Co., Inc., Whitehouse Station N.J., USA'nın tescilli markasıdır.  
Copyright © Merck & Co., Inc., Whitehouse Station, N.J., U.S.A., 1998.  
Tüm hakları saklıdır. 12-99-FSM-98-MEA-2042-J(TR)

F  
O  
S  
A  
M  
A  
X<sup>®</sup> †

alendronat  
sodyum



## **GAMMA KNİFE**

(Türkiye ve çevre ülkelerde ilk ve tek)  
Beyin Patolojilerinde  
cerrahi müdahaleye gerek kalmaksızın  
tedavi olanağı

## **Radyasyon Onkolojisi**

Saturn 42 Lineer Akseleratör  
Target Doz Planlama Üniti  
Nuclital Simulator

## **Nükleer Tıp**


Camstar X-CT  
Camstar X-RT  
Optima  
Genie Work Stations

## **Radyodiyagnostik**

Magnetic Rezonans  
Helical Bilgisayarlı  
Tomografi  
DSA Angiography  
Preferic Angiography  
Mammografi  
Floroscopy  
Konvansiyonel X-Ray  
Mobile X- Ray  
Ultrasonografi  
Doppler Ultrasonografi  
Advantage Windows  
(Görüntü Değerlendirme  
Sistemleri)

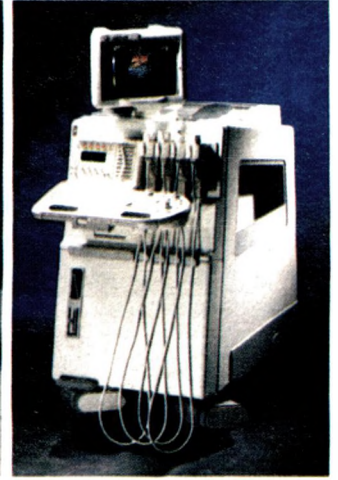
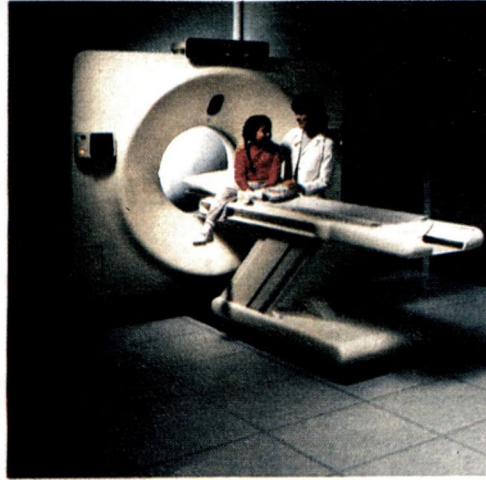
## **Networking System**

## **Ülkemizin en kapsamlı ve modern Teşhis/Tedavi Merkezi**




**GE Medical Systems  
&  
MARMARA  
ÜNİVERSİTESİ**

**İŞBİRLİĞİ**



**Marmara Üniversitesi Tıp Fakültesi Hastanesi 1. ve 2. bodrum katlar**  
**Telefon: (0216) 327 69 50 (4 Hat)**



*Bir kitabın yaşadığı bütün aşamaları  
beraber gerçekleştirebiliriz...*

*Bize daktilo sayfalarıyla gelmeniz yeterli.*

*Kitap ve süreli yayınlarda*

***Kurtiş Matbaacılık.***



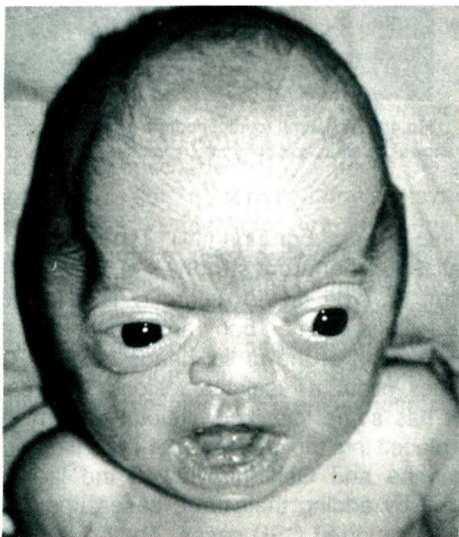
She had abnormal external genital organs, diagnosed as ambiguous genitalia. There was a dermal sinus tract over the lumbar area in the midline. The shape and length of her extremities and fingers were normal.

Cranial plain roentgenograms revealed trilobed skull deformity with evident sagittal suture synostosis and honeycomb appearance of calvarial areas (Figs 2 a,b). Cranial computerized tomography scans showed obliteration in all sulci and subarachnoidal cisterns. Ventricular systems were narrowed and posterior lateral ventricles were obliterated bilaterally. Calvarial bones were very thin and irregular. Metopic, squamosal and medial coronal sutures were widened. Orbital cavities were bilaterally shallow. The middle fossa was wide but anterior and posterior fossae were

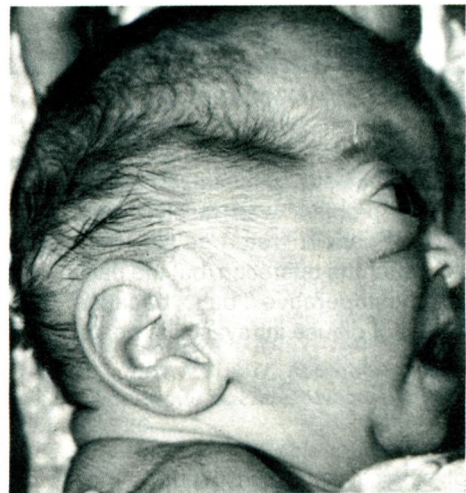narrow (Fig. 3). The dimensions of the foramen magnum were within normal ranges.

Plain roentgenograms of the whole body were taken. The shapes of the long bones in the extremities were normal. The sacral vertebrae and coccyx showed a lordotic alignment and their tip was palpable (Fig.4).

The day after referral, the patient became tachycardic and tachypneic, because of increased intracranial pressure. The following day, she was operated. After sagittal and coronal synostectomies, frontal and parietal bone flaps were placed on dura with single stitches in the manner of free floating flaps. The occipital bone was so tightly adhered to the dura along the lambdoid sutures that, it was left in place.

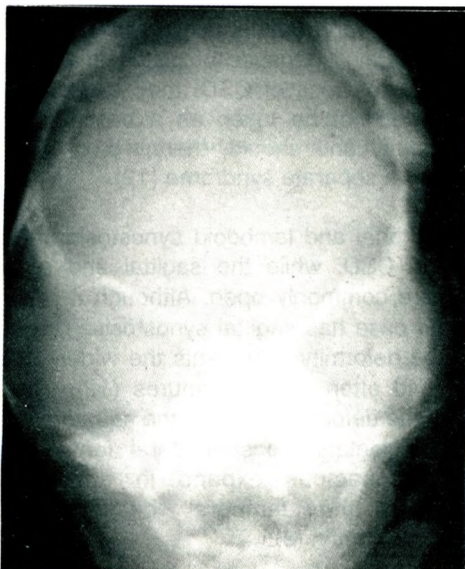


a

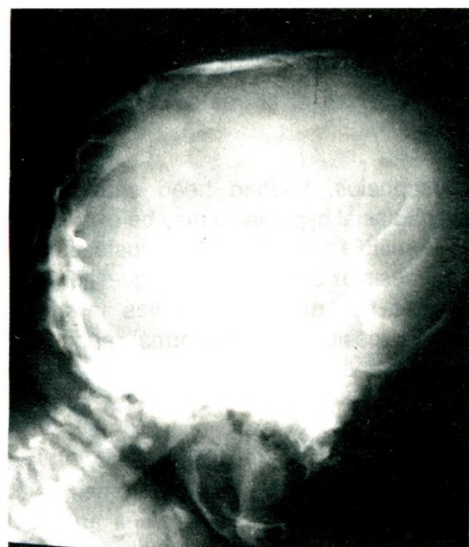


b

Fig.1: Anterior (a) and lateral (b) photographs of head show the trilobed appearance of head.



a



b

Fig.2: Anterior (a) and lateral (b) plain cranial roentgenograms. Note the beaten copper appearance of calvarial bones and sagittal suture synostosis.

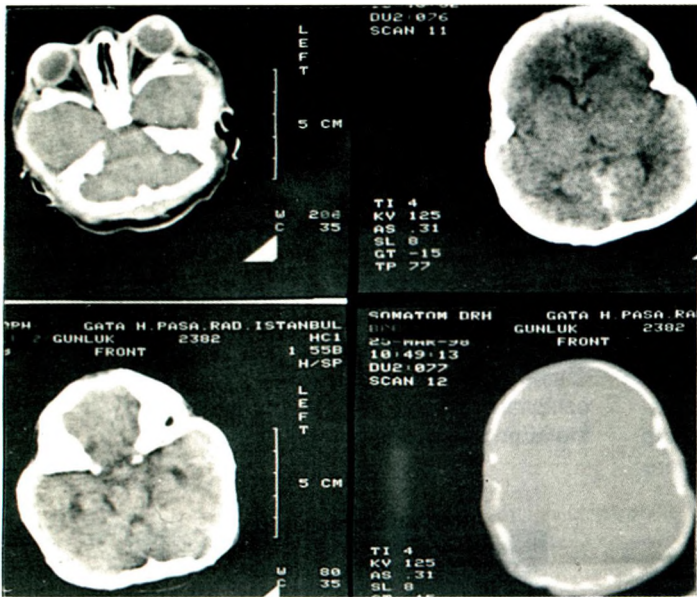


Fig.3: Cranial computerized tomography scans.

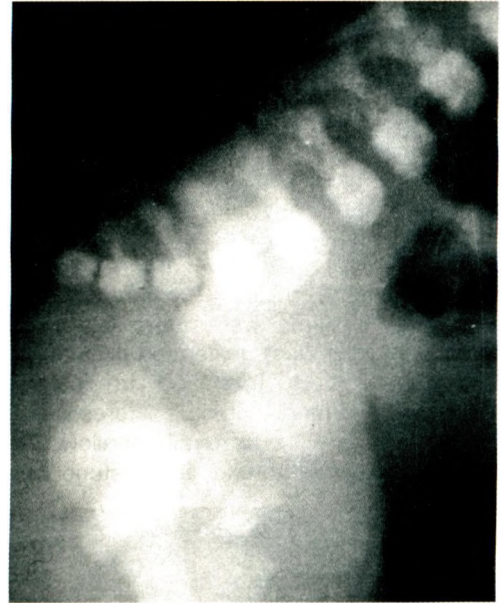

Fig.4: Plain lateral roentgenogram of sacrococcygeal area shows the lordotic alignment of sacral vertebrae and coccyx.

The breathing problem was resolved and the vital signs of the patient returned to normal limits immediately after the operation, but the patient died on the third postoperative day because of the development of diffuse intravascular coagulopathy.

## DISCUSSION

Timing of surgical approach depends mostly on the neurological status of the patients. Although the data concerning the results of early operative intervention of CSD are not enough and it is uncertain whether aggressive decompressive / reconstructive procedures are effective in treating the effects of the malformation on both neurological development and cosmetic appearance, Resnick et al treated their 7 patients in early infancy (7).

The hydrocephalus, trilobed head shape, shallow orbits, and midfacial hypoplasia may be explained with intrauterine multiple cranial suture synostoses, but the real pathogenesis of CSD remains in question (8). It is proposed that the major defect lies in abnormal membranous ossification. Abnormal endochondral ossification has been suggested as the basis of cranial deformity also (2,9).

CSD rarely occurs as an isolated entity. It mostly occurs in association with other syndromes, such as Apert's, Crouzon's, Pfeifer's syndromes and skeletal dysplasia (10). Partington et al. subdivided the CSD

cases into three subgroups (11). Type I is seen with generalized chondrodystrophy of thanatophoric dwarfism. In Type II, the deformity is with localized skeletal lesions such as bony ankylosis of the elbows and subluxation of the radial heads or hips. Type III deformities occur as isolated lesions. The case we present has some localized skeletal deformities and can be placed into the subgroup of Type II deformities. Iannaccone and Gerlini reviewed the literature in 1974 and by adding their three cases, they found a total of 41 reported CSD cases. They concluded that the trilobed deformity is a result of severe alterations in skull development associated with marked hydrocephalus and cranial bulging toward the vertex and bitemporally. Because of quite variable shapes, sizes and evolutions of CSD, they suggest that this pathology cannot be taken as a basis to define a specific entity and should, therefore, no longer be considered a separate syndrome (12).

Mostly, coronal and lambdoid synostosis are usually present in CSD, while the sagittal and squamosal sutures are commonly open. Although it is rare, the presented case has sagittal synostosis. The superior leaf of the deformity represents the widely diastased sagittal and often metopic sutures (12). The lateral leaves of the deformity arise as the squamosal suture, squamosal fontanel, posterolateral fontanel, and/or temporal squamous expand in an attempt to accommodate the temporal dilatation of the hydrocephalic brain (8).



Hydrocephalus is invariably present at birth but develops subsequently in relation to the severity of the premature synostosis (8,13). Whether due to impairment of venous outflow and raised venous pressure in the sagittal sinus or to disruption of cerebrospinal fluid circulation within cortical sulci, both mechanisms specifically acting at the level of the constructive cranial ring, in theory it is possible to avoid the development of hydrocephalus by treating the craniosynostosis early (8). Angle et al. considered the hydrocephalus to be caused by hypoplasia of the chondrocranium with a basilar deformity causing obstruction of the fourth ventricle (2). Prior to the definitive surgery shunting the accompanying hydrocephalus is recommended (14-16). The early computerized tomography scans in our patient did not reveal hydrocephalus and the foramen magnum was seen in normal dimensions. But it was most likely that the communicating hydrocephalus would develop, if the operation were delayed.

The calvarium in CSD has a honeycombed appearance, also known as craniofenestrae which resembles "lückenschadel" (9,17). Unlike the surgical management of conventional syndromal craniosynostosis, paper-thin cranial bones and cranialacunae make surgery tedious and risky in cloverleaf skull because of the high possibility of dural tears. The management of CSD remains a challenge and continues to evolve. Long-term prognosis is still poor, but early surgical intervention provides the potential for relief of craniosynostosis and hydrocephalus (8).

## REFERENCES

1. Holtermüller K, Wiedemann HR. Kleeblattschadel-Syndrom. *Med Monatsschr* 1960;14:439-446.
2. Angle CR, McIntire M, Moore RC. Cloverleaf skull: Kleeblattschadel - deformity syndrome. *Am J Dis Child* 1967; 114: 198-202.
3. Feingold M, O'Connor JF, Berkman M. Kleeblattschadel syndrome. *Am J Dis Child* 1969; 118: 589-594.
4. Angle B, Hersh JH, Christensen KM. Molecularly proven hypochondroplasia with cloverleaf skull deformity: a novel association. *Clin Genet* 1998; 54: 417-420.
5. Boos R, Schmidt W. Prenatal diagnosis of thanatophoric dwarfism with cloverleaf skull. *Z Geburtshilfe Perinatol* 1986; 190: 225-228.
6. Salvo AF. In utero diagnosis of Kleeblattschadel (cloverleaf skull). *Prenatal Diagn* 1981; 1: 141-145.
7. Resnick DK, Pollack IF, Albright AL. Surgical management of the cloverleaf skull deformity. *Pediatr Neurosurg* 1995; 22: 29-37.
8. Lodge ML, Moore MH, Hanieh A, Trott JA, David DJ. The cloverleaf skull anomaly: Managing extreme cranio-orbitofaciostenosis. *Plast Reconstr Surg* 1993; 91: 1-14.
9. Burkhardt L, Fisher H. Pathologische Anatomie des Schädels. In: Henke F, ed. *Handbuch der Speziellen Pathologischen Anatomie und Histologie*. Berlin, Springer-Verlag: 1970: 116-117.
10. Kozłowski K, Warren PS, Fisher CC. Cloverleaf skull with generalised bone dysplasia. *Pediatr Radiol* 1985; 15: 412-414.
11. Partington MW, Gonzales-Crussi F, Khakee SG, Wollin DG. Cloverleaf skull and thanatophoric dwarfism. *Arch Dis Child* 1971; 46: 656-664.
12. Iannaccone G, Gerlini G. The so-called "Cloverleaf skull syndrome". *Pediatr Radiol* 1974; 2: 175-184.
13. Muller PJ, Hoffman HJ. Cloverleaf skull syndrome. *J Neurosurg* 1975; 43: 86-91.
14. Rogathi M. Cloverleaf skull- a severe form of Crouzon's syndrome: a new concept in aetiology. *Acta Neurochir (Wien)* 1991; 108: 45-52.
15. Goh KY, Ahuja A, Fok TF, Poon WS. Cloverleaf skull- when should one operate? *Singapore Med J* 1997; 38: 217-220.
16. Heeckt P, Muhlbauer W, Fairley J, Anderl H, Hopner F. Pancraniofacial synostosis-indications for early craniofacial operation. *Handchir Mikrochir Plast Chir* 1994; 26: 60-67.
17. Carmel PW, Lukem MG, Ascherl GF. Craniosynostosis: Computed tomographic evaluation of skull base and calvarial deformities and associated intracranial changes. *Neurosurgery* 1981; 9: 366-372.