

Case Report

FIBROUS DYSPLASIA OF THE TEMPORAL BONE

**Selçuk İnanlı, M.D. / Enver Özer, M.D. / Elif Ayanoğlu, M.D.
Alper Tutkun, M.D. / Çağlar Batman, M.D.
Cüneyd Üneri, M.D. / M. Ali Şehitoğlu, M.D.**

*Department of Otorhinolaryngology-Head and Neck Surgery, School of Medicine,
Marmara University, Istanbul, Turkey*

ABSTRACT

Fibrous dysplasia of the temporal bone is an extremely rare disorder. Here, a case of temporal bone fibrous dysplasia causing mild sensorineural hearing loss is presented. A heterogeneous solid mass destructing left mastoid bone and narrowing the external auditory meatus was found in the CT and MRI study of the temporal bone. The patient was treated surgically. Decompression of the external auditory canal and debulking of the expansile mass through a simple mastoidectomy was performed.

Key Words: Fibrous dysplasia, Temporal bone, Hearing loss, Vertigo

INTRODUCTION

Fibrous dysplasia is a bone disorder of unknown origin in which normal bone is replaced with fibrotic tissue and disorganized bone trabeculae. Fibrous dysplasia rarely affects the temporal bone and may cause both conductive and sensorineural type hearing loss. Treatment is recommended only in symptomatic cases and the only effective treatment modality is surgery.

Prognosis depends on the progression of the disease and is almost always good.

CASE REPORT

A 67-year-old male patient presented with vertigo and dizziness for 1 year. On physical examination his left external auditory canal was narrow and the left mastoid region was prominent. The Rinne test was positive on both ears and the Weber test was normal. In the patient's computed tomography (CT) (Fig.1) and magnetic resonance imaging (MRI) studies, a heterogeneous solid mass destructing the left mastoid bone and narrowing the external auditory meatus was found. (Fig. 2) The preoperative radiologic diagnosis was fibrous dysplasia. The audiogram showed a normal pattern in speech frequencies and mild sensorineural hearing loss in 4 KHz and higher frequencies. Internal medicine and neurological evaluations were normal. The patient did not have involvement of any other organ systems. Blood analysis did not show an evidence of pathology. The patient underwent decompression of the external auditory canal and debulking of the expansile mass through a simple mastoidectomy. Macroscopically the lesion was a fibrotic tissue containing patchy bone

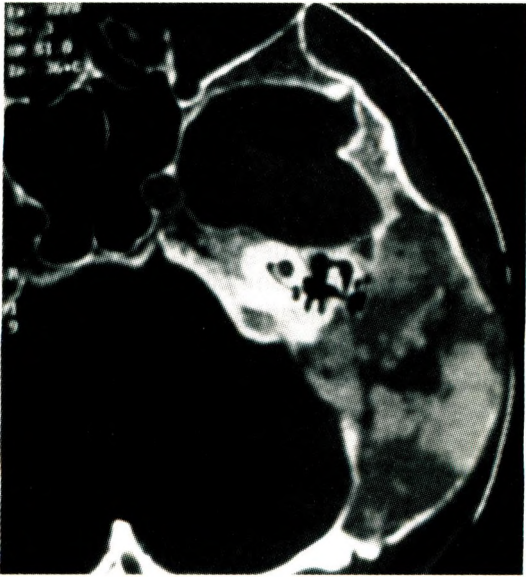


Fig.1.: Axial section of the temporal bone CT. It is in pagetoid type.

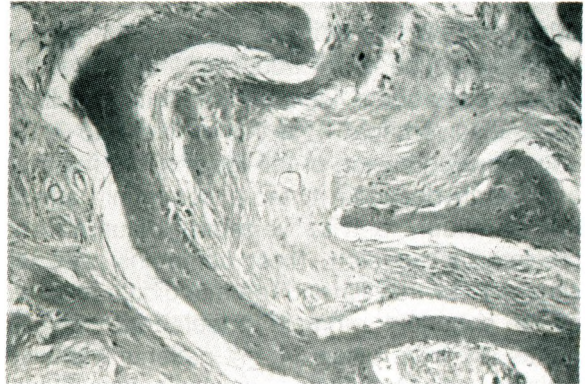


Fig.3.: Histopathological view of the presented case. Normal medullary bone is replaced by fibroosseous tissue. Disorganized bony trabeculae surrounded by fibrous matrix and fusiform cells are seen (HEX40).

formation. In histopathological examination the normal medullary bone is replaced by progressively growing fibroosseous tissue. (Fig. 3) In the postoperative period, signs and symptoms of the disease disappeared.

DISCUSSION

Fibrous dysplasia was first described by Von Recklinghausen in 1891 (1) and Mc Cune and Bruch were the first to present it as a clinical case in 1937. The disease has been found to have three different variants: monostatic, polyostatic, and Albright's Syndrome (2). 10-30% of monostatic fibrous dysplasia and 50-100% of polyostatic fibrous dysplasia are in craniofacial form (3). There are 76 reported cases of temporal bone fibrous dysplasia in the literature (4). The term 'fibrous dysplasia' was suggested by Lichtenstein in 1938 (5). Fibrous dysplasia is a benign disease in which there is slowly progressive growth of abnormal fibroosseous tissue which displaces the normal medullary bone. The tissue contains disorganized bony trabeculae and spindle cells surrounded by a fibrous matrix. The tissue expands, causing distortion and weakening of the bone and the overlying cortical bone may be thinned because of pressure but it is not directly in the disease process (4,6,7).

Fibrous dysplasia accounts for about 7% of all bone tumors (1). There are three variants of fibrous dysplasia. monostatic fibrous dysplasia

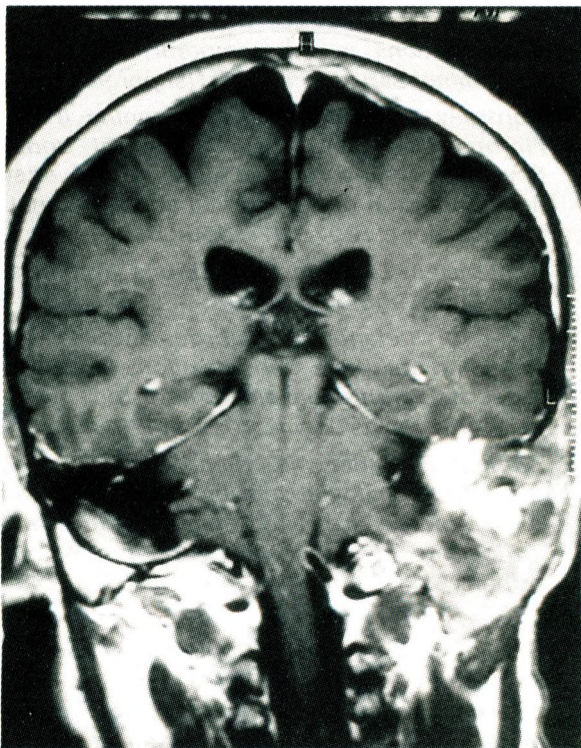


Fig.2.: MRI of the presented case.

accounts for 70% of cases and tends to be more evident in late childhood. Polyostatic fibrous dysplasia accounts for about 30% of cases and usually becomes evident as a result of multiple bone involvement. It is more likely to have ongoing progression of the lesions into the third and fourth decades. It more commonly affects the shoulder, pelvis, vertebral column, and craniofacial skeleton. Most commonly affected sites are the maxilla and the mandibula followed by the sphenoid, ethmoid, parietal and occipital bones (1). In a review of 144 patients with skull lesions caused by fibrous dysplasia, Van Tilburg found the temporal bone to be affected 18% of the time when the skull was involved (4). The petrous and mastoid parts of the temporal bone are the most commonly affected (8). Hearing loss is the most common presenting symptom of temporal bone fibrous dysplasia. Hearing loss is most often conductive and due to the stenosis of the external auditory canal or involvement of the ossicular chain. Cholesteatoma is seen in 40% of the cases and usually originates from the external canal. Sensorineural hearing loss attributed to the lesion is seen in 17% of patients with fibrous dysplasia and it is due to the involvement of the otic capsule (4). Facial nerve involvement is seen in 10% of these patients. Although not common, the function of all cranial nerves can be affected in fibrous dysplasia (3). Only one case of temporal bone fibrous dysplasia with sensorineural hearing loss showed recovery after surgical decompression (9).

Malignant transformation is seen in approximately 0,5% of patients. The average time between the diagnosis of fibrous dysplasia and malignancy is 13,5 years. The malignancies reported are osteosarcoma, fibrosarcoma, chondrosarcoma, and giant cell sarcoma. Malignant transformation has never been reported in temporal bone disease. The incidence of malignant transformation after radiotherapy is 44% (10,11). On radiographic examination fibrous dysplasia has a characteristic ground-glass appearance and is usually surrounded by a shell of dense cortical bone. Craniofacial fibrous dysplasia may have several radiographic patterns. Pagetoid, sclerotic, cystic. The most common pattern is pagetoid and is seen in 56% of cases. In our case, the pattern of fibrous dysplasia is also pagetoid. Temporal bone lesions have a sclerotic

pattern in two thirds of the cases (4,10,11). The use of periodic computed tomography can be helpful to follow the progression of the disease and to assess the need for surgical intervention (12). We decided for surgery with the help of CT.

Treatment and definitive diagnosis rely on surgical debulking and biopsy. The decision to treat depends on the degree of cosmetic or functional impairment. Complications such as cholesteatoma and hearing loss are surgical indications. In our case we considered all of these factors before deciding for the treatment modality.

REFERENCES

1. Tran LP, Grundfast KM, Selesnick S. Benign lesions of the external auditory canal. *Otolaryngol Clin North Am.* 1996;29:807-825.
2. Mc Cune DJ, Brunch H. Osteodystrophia fibrosa: report of a case in which the condition was combined with precocious puberty pathological pigmentation of the skin and hyperthyroidism, with a review of the literature. *Am J Dis Child* 1937;54:806-848.
3. Nager GT, Kennedy DW, Kopstein E. Fibrous dysplasia: a review of the disease and its manifestations in the temporal bone. *Ann Otol Rhinol Laryngol* 1982;91(suppl 92):1-52.
4. Morrissey DD, Talbot JM, Schleuning II AJ. Fibrous dysplasia of the temporal bone: Reversal of sensorineural hearing loss after decompression of the internal auditory canal. *Laryngoscope* 1997;107:1336-1340.
5. Lichtenstein L. Polyostotic fibrous dysplasia. *Arch Surg* 1938;36:874-898.
6. Djerić D, Stefanović P. Fibrous dysplasia of the temporal bone and maxillofacial region associated with cholesteatoma of the middle ear. *Auris Nasus Larynx* 1999;26:79-81.
7. Albright F, Butler AM, Hampton AO, et al. Syndrome characterized by osteitis fibrosa disseminata, areas of pigmentation and endocrine dysfunction with precocious puberty in females. *N Engl J Med* 1937;216:727-746.
8. Moreau S, Bourdon N, Goulette de Ruyg M, Bequignon A, Babin E, Valdazo A. Temporal fibrous dysplasia with labyrinthine involvement apropos of a case and review of the literature. *Ann Otolaryngol Chir Cervicofac* 1997;114:140-143.

9. Benedict PH. Sexual precocity and polyostotic fibrous dysplasia. *Am J Dis Child* 1966;11:426-431.
10. Schlumberger HG. Fibroid dysplasia of single bones (Monostotic fibrous dysplasia). *Mil Surg* 1946;99:504-527.
11. Sassin JF, Rosenberg RN. Neurological complications of the fibrous dysplasia of the skull. *Arch Neuro* 1968;18:363-369.
12. Younus M, Haleem A. Monostotic fibrous dysplasia of the temporal bone. *J Laryngol Otol* 1987;101:1070-1074.