

RIGHT VENTRICULAR MYXOMA INFILTRATING THE TRICUSPID VALVE AND OBSTRUCTING THE RIGHT VENTRICULAR INFLOW AND OUTFLOW TRACTS

Hakan Tezcan, M.D.* / Oğuz Caymaz, M.D.* / Ahmet Toprak, M.D.*
Ali Serdar Fak, M.D.* / Cevat Yakut, M.D.** / Ahmet Oktay, M.D.*

* Department of Cardiology, School of Medicine, Marmara University, Istanbul, Turkey.

** Koşuyolu, Heart Training and Research Hospital, Istanbul, Turkey.

ABSTRACT

Myxomas originating in the right ventricle are extremely rare tumors. Herein, a case of right ventricular myxoma, infiltrating the tricuspid valve and causing right ventricular inflow and outflow tract obstruction, is described. Two-dimensional echocardiography diagnosed the mass easily and cardiac Doppler with color-flow examinations defined precisely its hemodynamic consequences to the heart. Magnetic resonance imaging study helped in preoperatively defining its intracardiac extension and the differential diagnosis by its very specific tissue characterization. The patient was successfully treated surgically and the tricuspid valve was replaced with a bioprosthesis because of tumor invasion of the valvular tissue.

Key Words: Myxoma, right heart ventricle, tricuspid valve, ventricular outflow obstruction, ventricular inflow obstruction.

INTRODUCTION

Right ventricular (RV) myxomas are rare tumors, which usually cause RV outflow tract (RVOT) and/or inflow tract obstruction (1, 2). Herein, we describe another such case demonstrated by two-dimensional (2-D) echocardiography and magnetic resonance imaging (MRI) of the heart. The patient was successfully treated surgically, but replacement of the tricuspid valve (TV) was inevitable due to tumor invasion as rarely reported previously (2).

CASE REPORT

A 20-year-old woman was admitted because of palpitations and dyspnea on exertion with a duration of one year. She was known to have had two episodes of syncope related to exertion within the last year. On physical examination; the heart rate was 110 beats per minute with a regular rhythm. There was no jugular venous distension, but a prominent "a" wave was noted. Cardiac examination revealed a remarkable left parasternal lift (tumor shock); and a systolic thrill at the second and third left intercostal spaces. The first heart sound was normal, while the second heart sound was widely split (tumor plop). A late diastolic sound, presumably a fourth heart sound originating from the right heart, was also heard. There was a grade 3/6 harsh systolic ejection murmur at the second and third left intercostal spaces. No diastolic murmur was audible. The chest radiograph showed a mildly enlarged right heart silhouette and a prominent pulmonary conus with normal pulmonary vascularity. The electrocardiogram showed sinus tachycardia, right axis deviation, P-pulmonale, RV hypertrophy and incomplete right bundle branch block. A 2-D echocardiogram disclosed a huge mass in the RV cavity, which prolapsed into the pulmonary artery during systole (Fig. 1), and was also attached to the TV obstructing the inflow tract (Fig. 2). Right atrium (RA) and RV were markedly dilated, while left ventricle was rather small with a paradoxical septal motion. Color-flow and Doppler examinations revealed mild tricuspid and pulmonary regurgitations, a systolic gradient of 23 mm Hg (Vmax: 2.4 m/sec) at the RV outflow and mean diastolic gradient of 3 mm Hg

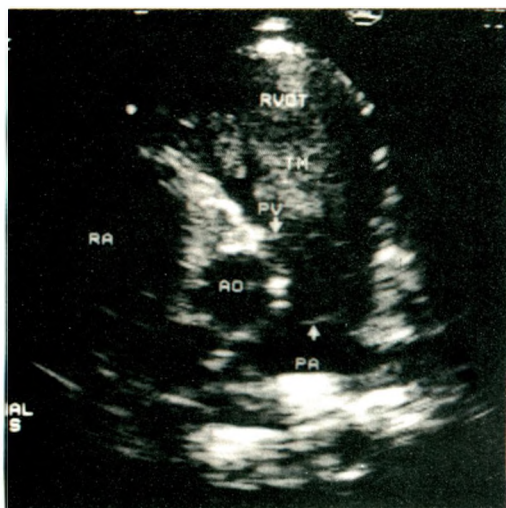


Fig. 1.: Transthoracic 2-D echocardiographic demonstration of the right ventricular (RV) mass, which prolapses into the pulmonary artery (PA) during systole. Parasternal short axis view. RA: right atrium, Ao: aorta, RVOT: right ventricular outflow tract, PV: pulmonary valve. TM: tumor mass

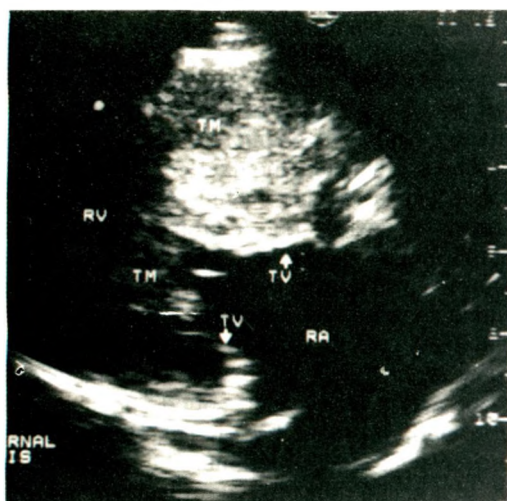


Fig. 2.: Transthoracic 2-D echocardiography of the tumor mass (TM) obstructing the inflow tract of the right ventricular (RV) cavity and invading tricuspid valve (TV). Parasternal long axis view. RA: right atrium.

(Vmax: 1.4 m/sec) at the TV. MRI study of the heart was done to define the extent of the cardiac involvement and to reveal any possible pulmonary embolism. The tumor appeared to be attached to the RV free wall and also to the tricuspid leaflets obstructing the inflow and prolapsing into the pulmonary artery (Figs.3 and 4). The lungs were clear with no signs of infarction.

The patient underwent surgical exploration with a presumptive diagnosis of a RV tumor. A mass, 16x8x6 cm in size and adherent to the anterior RV wall, interventricular septum, papillary muscles and TV, was resected (Fig. 5). The lobulated and friable tumor

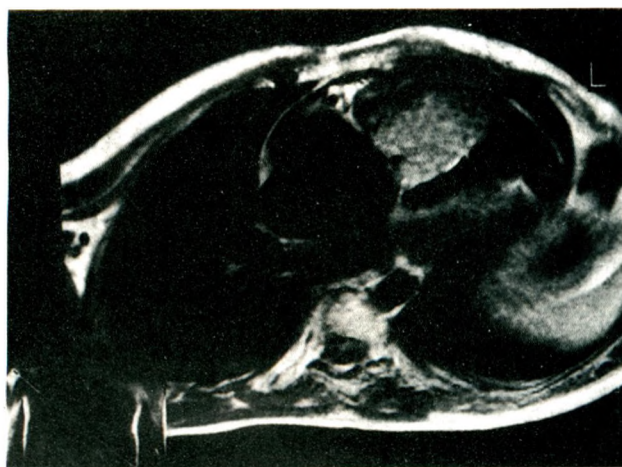


Fig.3.: T1-weighted magnetic resonance image in axial plane shows right ventricular cavity obstruction and tricuspid valve infiltration of the tumor.

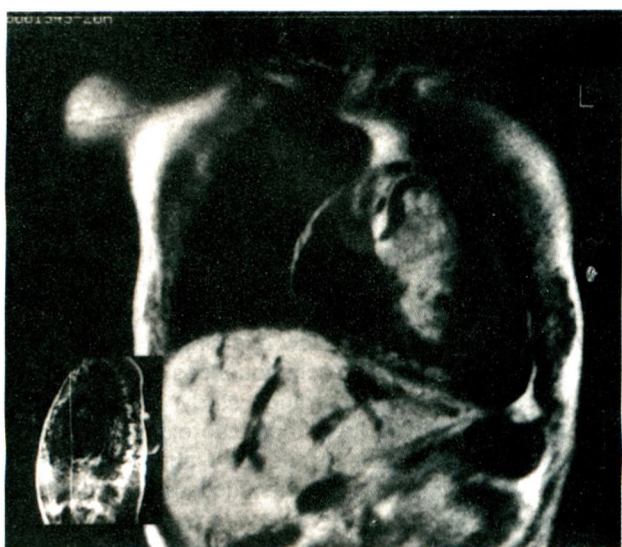


Fig.4.: T1-weighted magnetic resonance image in coronal plane demonstrates right ventricular tumor prolapse into the pulmonary artery.

mass, which extended from the base of the TV to the apex of the right ventricle, had a pedicle of 5x8 cm on the anterior RV wall. Anterior and septal leaflets of the TV was infiltrated by the tumor and it was not possible to preserve them during the resection. The valve was excised and replaced with a valve bioprosthesis (Biocor, No. 31). The pathological diagnosis was myxoma. The patient had an uneventful recovery and had no problems throughout the 3 months of follow-up.

DISCUSSION

Myxomas constitute from 35 to 50 percent of all cardiac neoplasms, of which 75 percent arise in the left atrium and nearly all of the rest in the right atrium. Myxoma of the right ventricle is extremely rare as is a

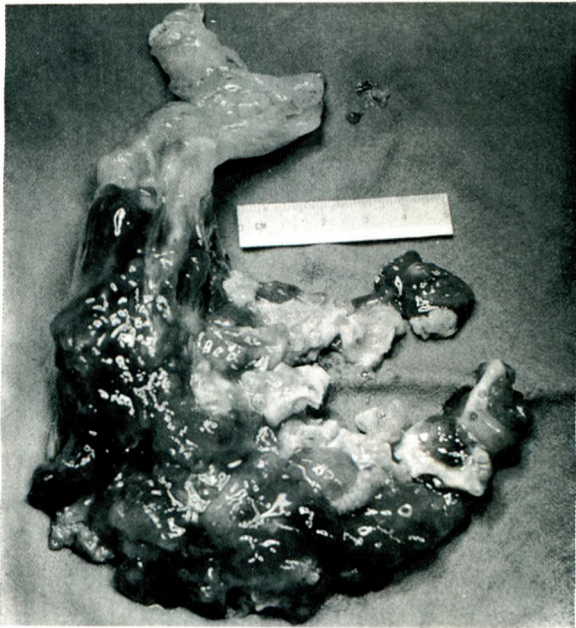


Fig. 5.: Macroscopic view of the excisional biopsy of the right ventricular tumor mass, which was 16x8x6 cm in size. This lobulated mass had a prominent pedicle and contained tricuspid valve leaflets, which were also excised during resection.

myxoma occurring in the left ventricle (2). RV myxoma usually gives rise to signs and symptoms secondary to inflow and outflow obstruction of the RV (1,3). The tumor may uncommonly present as pulmonary embolism, which is often fatal (3,4). Although the clinical features, ECG and chest radiogram may be suggestive, these are highly nonspecific for the definitive diagnosis. Until recently, these patients were subjected to cardiac catheterization and angiography for the definitive preoperative diagnosis. Currently, it is fairly easy to diagnose and define precisely a RV tumor by 2-D echocardiography (5), as done in this case. There have been several case reports of RV myxoma, diagnosed and treated surgically solely depending on echocardiography (5,6). It is also possible to characterize the hemodynamic consequences of the tumor by means of cardiac Doppler and color-flow examinations noninvasively. MRI may also have a complementary role in the diagnosis of RV masses. It may contribute important additional anatomic information regarding the tumor's relationship to the normal intracardiac structures and/or its extension to the adjacent vascular and mediastinal structures (7,8). Additionally, MRI, with its highly specific tissue characterization, might be helpful in the differential diagnosis of intracardiac masses. Occasionally, even the invasive techniques may not be successful in differentiating a RV thrombus from a tumor (9).

RV myxomas uncommonly originate in the TV (10) and valve involvement of a myxoma requiring TV replacement is extremely rare. To the best of our knowledge, there are only three such cases reported previously in medical literature (2, 11). Interestingly, in a case report with an organized RV thrombus attached to the RV wall and the TV mimicking a RV myxoma, the valve had to be replaced during surgical resection (9).

The cardiac surgeon exploring a RV myxoma should keep in mind that it might be necessary to replace the TV during the resection of the tumor. 2-D echocardiography and MRI may indicate this possibility preoperatively.

REFERENCES

1. Zager J, Smith JO, Goldstein S, Franch RH. Tricuspid and pulmonary valve obstruction relieved by removal of a myxoma of the right ventricle. *Am J Cardiol* 1973;32:101-104.
2. Burakovsky VI, Zuckerman GI, Kossatch GA, Golossovskaya MA, Javorskaya LA. Surgical treatment of cardiac myxomas. *J Thorac Cardiovasc Surg* 1988;96:800-805.
3. Boulafendis D, Heine J, Samaan HA. Right ventricular myxoma. *Int J Cardiol* 1984;5:216-219.
4. Gonzales A, Altieri PI, Marquez E, Cox RA, Castillo M. Massive pulmonary embolism associated with a right ventricular myxoma. *Am J Med* 1980;69:795-798.
5. Chia BL, Lim CH, Sheares JH, Choo MH. Echocardiographic findings in right ventricular myxoma. *Am J Cardiol* 1986;58:663-664.
6. Viswanathan B, Lubner JM Jr, Bell-Thomson J. Right ventricular myxoma. *Ann Thorac Surg* 1985;39:280-281.
7. Emmot WW, Vacek JL, Agee K, Moran J, Dunn MI. Metastatic malignant melanoma presenting clinically as obstruction of the right ventricular inflow and outflow tracts. Characterization by magnetic resonance imaging. *Chest* 1987;92:362-364.
8. Freeberg RS, Kronzon I, Rumancik WM, Liebeskind D. The contribution of magnetic resonance imaging to the evaluation of intracardiac tumors diagnosed by echocardiography. *Circulation* 1988;77:96-103.
9. Van Osdol KD, Hall RJ, Warda M, Massumi A, Klima T. Right ventricular thrombus: clinical and diagnostic features. *Tex Heart Inst J* 1983;10:359-364.
10. Hada Y, Wolfe C, Murray GF, Craige E, Hill C. Right ventricular myxoma. Case report and review of phonocardiographic and auscultatory manifestations. *Am Heart J* 1980;100:871-876.
11. Gawdzinski MP, Sypula S. The long term results of treatment of heart myxomas with special attention to very rare myxoma of the right ventricle. *J Cardiovasc Surg* 1996;37 (6 Suppl 1): 121-129.