

## **A CLASSICAL VASCULAR DILEMMA: LIMB SALVAGE OR AMPUTATION ?**

**Atike Tekeli, M.D.\* / Serdar Akgün, M.D.\* / Koray Ak, M.D.\*  
Selim İsbir, M.D.\* / Ali Civelek, M.D.\* / Feyyaz Baltacıoğlu, M.D.\*\***

\* *Department of Cardiovascular Surgery, School of Medicine, Marmara University, İstanbul, Turkey.*

\*\* *Department of Radiology, School of Medicine, Marmara University, İstanbul, Turkey.*

### **ABSTRACT**

Popliteal artery injuries are the most challenging of all extremity vascular injuries. The popliteal vein, infrapopliteal arteries and the tibial nerve are the most commonly injured structures in penetrating popliteal trauma patients. Despite the experience obtained from the major wars in this century, ongoing advances in vascular surgery and near 100% limb salvage reports from current literature in popliteal artery penetrating trauma, there is still an ongoing debate about the management of such injuries. These injuries require a multidisciplinary approach for appropriate management. One of the major conflicts is the decision between amputation or salvaging the limb. According to the current data and our clinical experience, evaluation and decision making in this group of injuries is mostly patient dependent.

In this case report, we present a young man with a left popliteal region gunshot injury. Immediately after the injury a limb salvage procedure was performed by our team. Now the patient has a conserved limb but functionally amputated extremity after 4 months of hospital stay.

**Key Words:** Penetrating vascular injury, Gunshot wounds, Treatment.

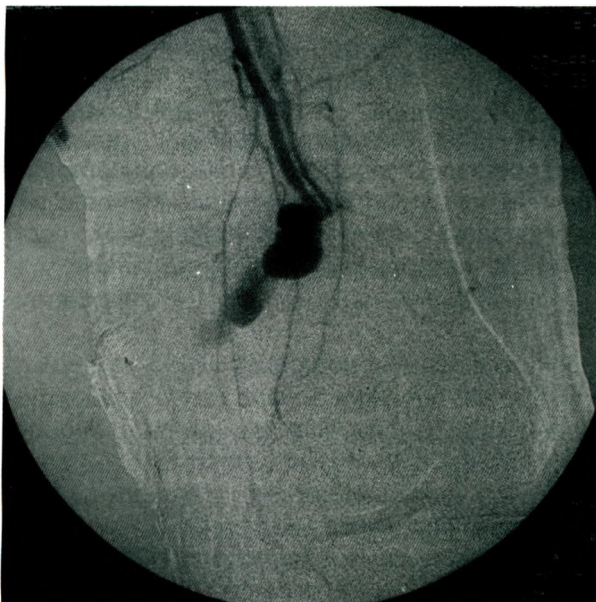
### **INTRODUCTION**

Successful management of popliteal vascular injuries requires a multidisciplinary approach. Popliteal artery injuries are among the most challenging of all extremity vascular injuries. The popliteal vein, infrapopliteal arteries and the tibial nerve are the most commonly injured structures in penetrating popliteal trauma patients. Penetrating traumas are mostly seen in wars and much experience has been obtained, but there is also an ongoing debate about the management of these injuries.

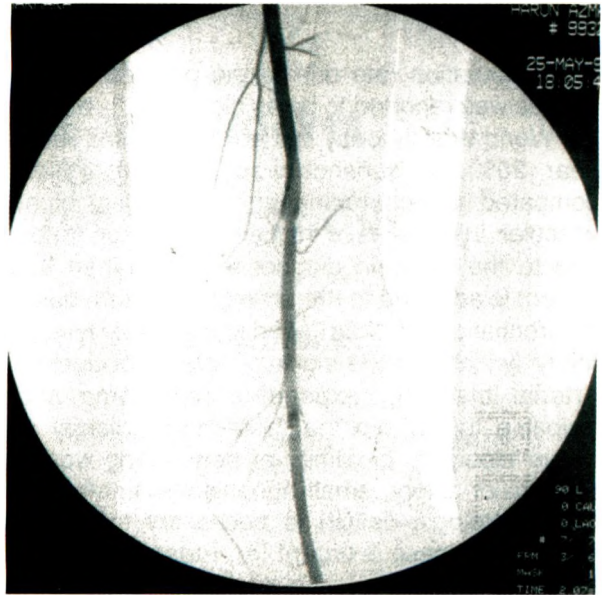
### **CASE REPORT**

A 24-year-old man was admitted to the emergency room with a left lower extremity gunshot injury. He was comatose due to massive blood loss. Tight circular left popliteal bandage application, rapid stabilization of hemodynamic state and blood transfusions were performed by the emergency staff on admission. On arrival at

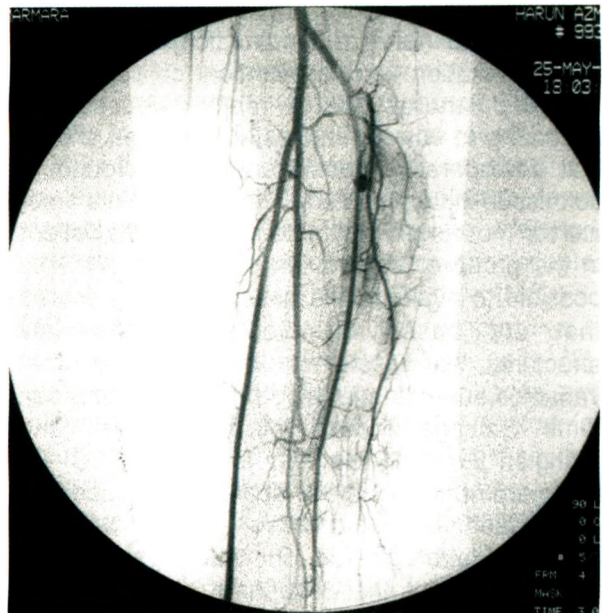
the emergency room, the warm ischemia time was documented to be 13 hours. There was also pallor, absence of distal pulses, pulsatile hematoma and complete motor and sensory deficit of the same limb without orthopedic problems. Preoperative left lower extremity digital subtraction angiography revealed extravasation of blood from the popliteal artery with the absence of distal flow (Fig. 1). The patient was taken to the operating room, first the ipsilateral common femoral artery was explored and clamped to control the bleeding. Exploration of the popliteal structures revealed that there was a complete transection of both the artery and the vein. Both the arterial and venous revascularisations were performed with the contralateral saphenous vein interposition. After vascular repair, anterior and posterior fasciotomies were performed through separate incisions to prevent the development of a compartment syndrome. The patient was heparinized for the first 5 postoperative days, then oral anticoagulation with warfarin was started. On the postoperative 7<sup>th</sup> day, due to the development of infection, repeated debridements were performed. On the postoperative 30<sup>th</sup> day, we confirmed the patency of the saphenous grafts by a control angiography (Figs. 2-3). After 45 days, fasciotomies were closed with split



**Fig.1.:** Preoperative arteriography showing complete transection of the left popliteal artery due to gunshot injury.



**Fig.2.:** Early postoperative control angiography showing the patent saphenous vein graft.



**Fig.3.:** Late postoperative angiography showing the patent saphenous graft and improved distal flow due to resolution of edema.

thickness skin grafts from the contralateral lower extremity. Two months later, another control angiography was carried out and revealed a better graft flow and distal flow due to the resolution of edema distal to the injury. Throughout this period, the patient had what is designated as a functional amputation.

## DISCUSSION

The amputation rate due to the popliteal artery injuries was reported to be as high as 73% during the World War II, today it is possible to find rates near 20% for gunshot wounds (1,2). When compared to penetrating arterial injuries, blunt vascular injuries have higher amputation rates due to the delay in diagnosis (3,4). When the patient is admitted to the emergency room, quick differentiation of "hard" findings of the arterial injury (which include signs of arterial occlusion, arterial bleeding, expanding hematoma and palpable thrill) from the "soft" ones (history of active bleeding, proximity of penetrating wound to a major artery, small nonpulsatile hematoma and neurologic deficit) is necessary to decide whether the case is urgent (5). Presence of hard signs indicates immediate operative arteriography and ultrasonography in both groups of patients (6). To increase the limb salvage rate and minimize the long term disability, good microsurgical techniques for vascular and nerve reconstruction, appropriate skeletal fixation and prevention of sepsis by antibiotic therapy are major necessities. According to current studies, it has been shown that postoperative sepsis and the surrounding soft tissue injury, instead of warm ischemia time, are the most important factors that put the patient in the group of amputation or salvage (2). It is possible to evaluate the patient with the scores that are based on disturbed anatomical structures, warm ischemia time and some other variables such as age, blood pressure etc... e.g; Limb Salvage Index Scoring System and Mangled Extremity Severity Scores (MESS) (7-9). Interpretation of these scores with respect to each patient and determination of the appropriate treatment strategies is our main goal in the management of these patients. In conclusion, this case represents a classical dilemma in vascular injury treatment. Our patient is still living with a functionally amputated left lower limb due to the tibial nerve injury and muscle necrosis. We conclude that it might have been better to amputate the patient's limb, because all the operations, the hospital stay and the outcome failure of the patient caused him and his family psychological and financial problems.

## REFERENCES

1. DeBakey ME, Simeone CF. *Battle injuries of the arteries in World War II: an analysis of 2471 cases.* *Ann Surg* 1946;123:534-537.
2. Wagner WH, Yellin AE, Weaver FA, Stain SC, Siegel AE. *Acute treatment of penetrating popliteal artery trauma: the importance of soft tissue injury.* *Ann Vasc Surg* 1994;8:557-565.
3. Thomas DD, Wilson RF, Wiencek RG. *Vascular injury about the knee. Improved outcome.* *Am Surg* 1989;55:370-377.
4. Shah PM, Agarwal N, Babu SC, Stahl WM, Clauss RH. *Causes of limb loss in civilian arterial injuries.* *J Cardiovasc Surg* 1986;27:278-281.
5. Weaver FA, Papanicolaou G, Yellin AE. *Difficult peripheral vascular injuries.* *Surg Clin North Am* 1996;76:843-859.
6. Fry WR, Smith RS, Sayers DV, et al. *The success of duplex ultrasonographic scanning in diagnosis of extremity vascular proximity trauma.* *Arch Surg* 1993;128:1368-1372.
7. Whitman GR, Mc Croskey BL, Moore EE, Pearce WH, Moore FA. *Traumatic popliteal and trifurcation vascular injuries: determinants of functional limb salvage.* *Am J Surg* 1987;154:681-684.
8. Russell WL, Sailors DM, Whittle TB, Fisher DF, Burns RP. *Limb salvage versus traumatic amputation. A decision based on a seven part predictive index.* *Ann Surg* 1991;213:473-481.
9. Melton SM, Croce MA, Patten JH, et al. *Popliteal artery trauma. Systemic anticoagulation and intraoperative thrombolysis improves salvage.* *Ann Surg* 1997;225:518-529.