

## **PRENATAL DIAGNOSIS OF A FETUS WITH TRISOMY 9 MOSAICISM: ULTRASONOGRAPHIC AND CYTOGENETIC FINDINGS**

**Rıza Madazlı, M.D. / Burçak Erzik, M.D. / Begüm Körbeyli, M.D.  
Seyfettin Uludağ, M.D. / Vildan Ocak, M.D.**

*Department of Obstetrics and Gynaecology, Cerrahpaşa School of Medicine,  
Istanbul University, Istanbul, Turkey.*

### **ABSTRACT**

We present a fetus with multiple ultrasonographic abnormalities in which prenatal diagnosis revealed trisomy 9 mosaicism in the fetal blood and complete trisomy 9 in the amniotic fluid and chorionic villi. Ultrasonographic abnormalities included micrognathia, overlapping fingers, horseshoe kidneys located at pelvis showing mild pelvicalyectasia, hypoplastic left ventricle with an echogenic foci, ventricular septal defect, pulmonary artery stenosis, diffuse perihepatic calcifications and single umbilical artery.

**Key Words:** Trisomy 9 Mosaicism, Prenatal diagnosis, Ultrasonography

### **INTRODUCTION**

Trisomy 9 in a mosaic or non-mosaic state, is an uncommon chromosomal abnormality. Trisomy 9 syndrome is marked by severe mortality and morbidity. The life span is typically measured in months, and multiple anomalies in multiple systems are characteristic of both mosaic and non-mosaic types of trisomy 9 (1).

Prenatal ultrasonographic features such as intrauterine growth retardation, facial dysmorphism, abdominal hyperechogenic image, skeletal, urinary and cardiac malformations have been reported with this syndrome (2,3). However, diffuse perihepatic calcifications have not been reported previously as a prenatal ultrasonographic feature.

The cytogenetics of this syndrome comprise complete trisomy 9 and mosaic trisomy 9 karyotypes. Amniotic fluid and chorionic villi trisomy 9 mosaicism with normal fetal karyotype has been reported several times (3-6). Only one case is reported in the literature with complete fetal trisomy 9 in the amniotic fluid and mosaicism in the postnatal karyotype (7).

We present a case with multiple ultrasonographic abnormalities in which prenatal diagnosis revealed trisomy 9 mosaicism in the fetal blood and complete trisomy 9 in the amniotic fluid and chorionic villi.

### **CASE REPORT**

A 32-year-old woman, gravida 2, para 0, was referred for detailed ultrasound examination at 22

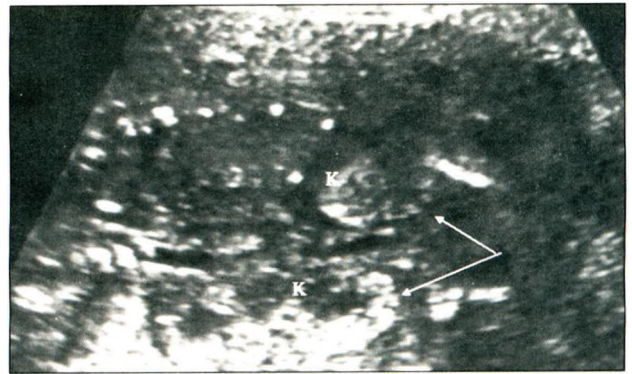
weeks of gestation with the suspicion of fetal abnormality. She had experienced a spontaneous abortion in the twelfth week of gestation in a previous pregnancy and had an unremarkable family history. Maternal serum alpha-fetoprotein (AFP), unconjugated estriol (uE3) and human chorionic gonadotropin (hCG) levels at 16<sup>+5</sup> weeks gestation were 0.98 MoM, 0.11 MoM and 0.59 MoM, respectively, and the calculated risk of trisomy 21 and 18 were 1/2600 and 1/195, respectively.

Ultrasonographic examination revealed a live singleton, small for gestational age fetus with normal amniotic fluid volume. The biparietal diameter, head circumference, abdominal circumference and femur length were 4.29 cm, 17.97 cm, 15.01 cm and 2.97 cm respectively, all below the fifth percentile for gestational age (8). Detailed sonographic evaluation of the fetus revealed micrognathia, overlapping fingers, horseshoe kidneys located at the pelvis showing mild pelvicalyectasia (6 mm), hypoplastic left ventricle with an echogenic foci, ventricular septal defect, pulmonary artery stenosis, diffuse perihepatic calcifications and a single umbilical artery (Figures - 1 a, b, c, d). The findings and possible diagnosis of a chromosomal abnormality were discussed with the couple and fetal blood sampling was performed on the same day.

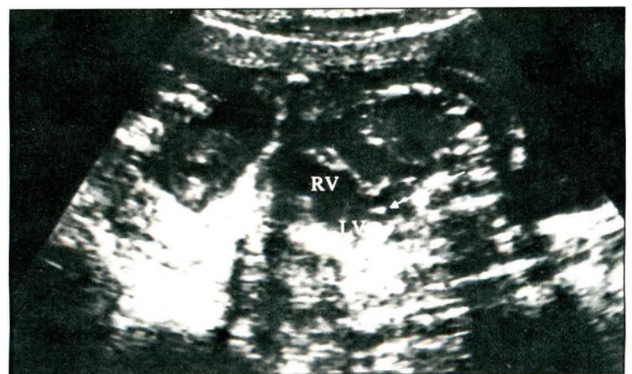
Culture of blood lymphocytes obtained by fetal blood sampling contained two cell lines: 47, XX + 9 (10) and 46, XX (30). Forty fetal lymphocyte metaphases were analysed and the average rate of trisomic cells observed in the fetal blood were 25 percent (10/40). The parents were informed that the fetal karyotype revealed trisomy 9 mosaicism. Surgical termination of the pregnancy



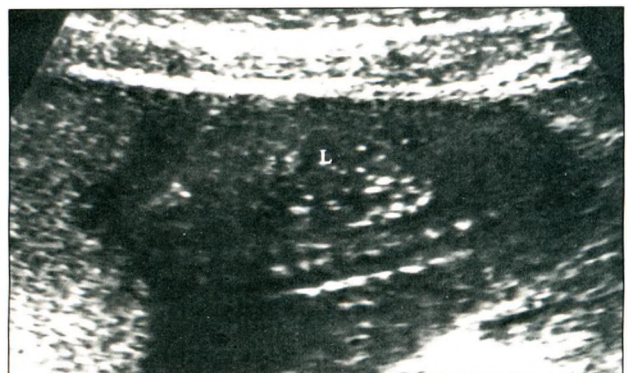
**Fig. 1 (a):** Right hand of the fetus, note overlapping fingers



**Fig. 1 (b):** Transverse oblique sonogram through the fetal abdomen demonstrating horseshoe kidneys (K, white arrows) located at the pelvis showing mild pelvicalyectasia (6 mm)



**Fig. 1 (c):** Sagittal sonogram through fetal thorax, four-chamber view of the heart demonstrating hypoplastic left ventricle with an echogenic foci (white arrow) and ventricular septal defect (RV: Right ventricle, LV: Left ventricle)

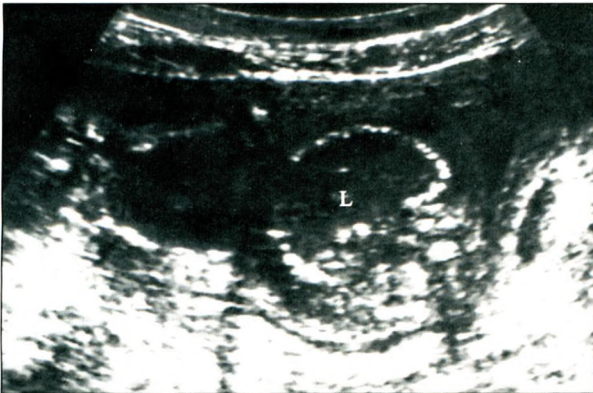


**Fig. 1 (d):** Sagittal sonogram (spine down) demonstrating diffuse perihepatic calcifications (L: Liver)

was decided as the parents requested, upon approval of the Ethics Committee.

A second ultrasonographic examination at 23 weeks of gestation before the termination of the

pregnancy, revealed persisting pathological findings with the addition of abdominal ascites (Fig.2). Amniocentesis and chorionic villus sampling were performed at the time of pregnancy termination. Karyotyping in both amniotic fluid and chorionic villi yielded trisomy 9 in all cell lines (20 metaphases each were analysed).



**Fig.2:** Transverse oblique sonogram through the fetal abdomen, note diffuse perihepatic calcifications and abdominal ascites (L: Liver)

Postmortem examination demonstrated a dysmorphic female fetus with a weight of 250 g and crown-rump length of 17 cm. Sloping forehead, low-set ears, micrognathia, overlapping fingers and 4 toes on the left foot with syndactyly of 2nd and 3rd toes were noted. Examination of the internal organs disclosed ventricular septal defect, hypoplastic left heart and pulmonary artery stenosis. Kidneys with a horseshoe appearance were located at the pelvis with mild ureteropelvic junction obstruction and the bladder was hypoplastic. Examination of the liver revealed subcapsullary calcifications, congestion and extramedullary hematopoiesis. The umbilical cord had a single umbilical artery.

## DISCUSSION

Trisomy 9, a relatively common finding in spontaneous abortions, is very rare in liveborn infants, and in many cases appears to represent mosaics. A rather consistent phenotype has been associated with trisomy 9, and similar features are present in complete or mosaic forms (9). The features commonly associated with trisomy 9 (complete or mosaic) include facial characteristics such as microcephaly,

dolichocephaly, small and upslanting palpebral fissures, large bulbous nose, micrognathia, deep-set eyes, and low-set malformed ears (9). Congenital heart defects and central nervous system anomalies have been noted in two-thirds of the cases, and renal malformations in half of the cases reported (10). Some authors have also described narrow temples, exophthalmos, high arched plate, calcaneovalgus deformity, limp dislocation, simian crease and gastrointestinal abnormalities (2).

The phenotypical features of the fetus in our case were consistent with the previous reports of trisomy 9. These include dysmorphic features of the head and face, overlapping fingers, renal and cardiac anomalies, which were all detected by ultrasonography. Additionally, hepatic calcifications were identified by prenatal ultrasound examination and verified by postmortem findings. Fetal infections (cytomegalovirus, herpes, toxoplasmosis), tumours (haemangioma, hepatoblastoma, teratoma, hamartoma) and vascular anomalies (portal vein thrombosis) may cause fetal hepatic calcifications (11). Fetal hepatic calcifications have also been associated with aneuploidy such as partial trisomy 8 and trisomy 18 (11,12). To the best of our knowledge, this is the first reported trisomy 9 case in which diffuse perihepatic subcapsullary calcifications were detected by ultrasonography.

Fetal karyotypes obtained from fetal blood showed 25 per cent (10/40) trisomy 9 cells, while that of amniocytes and chorionic villi showed 100 per cent (20/20). These differential frequencies of trisomy 9 among different tissues have also been reported by other authors (5-7). Most of the reports in the literature deal with cases where trisomy 9 mosaicism is detected in the amniotic fluid or chorionic villi and have normal karyotype in fetal blood, which of course is a serious problem and dilemma for genetic counselling. These discrepancies between different tissues may be related to different degrees of selection against trisomic cells or the nondisjunctional event leading to trisomy 9 happening relatively late in embryonic development, so that certain tissues receive trisomy 9 cells and others do not. Lack of significant differences in clinical phenotypes of mosaic vs. nonmosaic trisomy 9 cases indicate that there may be a low-grade or

tissue-specific mosaicism which can only be detected by analysing more metaphases, different tissues and by FISH studies conducted on a larger number of cells (9).

Another important observation in our case was the detection of low maternal serum uE3 and hCG levels in the second trimester triple screening test. There are reports demonstrating normal maternal serum AFP levels in fetuses with trisomy 9 in the second trimester (2,10). In the present case maternal serum AFP (0.98 MoM) level was also within normal limits. However, to the best of our knowledge, this is the first observation of low maternal serum uE3 (0.11 MoM) and hCG (0.59 MoM) levels in a fetus with trisomy 9. Low maternal serum uE3 and hCG levels in the second trimester triple screening increases the risk of trisomy 18 and this case indicates that trisomy 9 may also be considered.

While live births with trisomy 9 are very rare, this chromosomal abnormality should be considered when evaluating a fetus with multiple congenital abnormalities in a particular pattern, which includes brain, heart, genitourinary tract and limb anomalies as well as intrauterine growth retardation and perihepatic calcifications.

## REFERENCES

1. Saneto RP, Applegate KE, Frankel DG. Atypical manifestations of two cases of trisomy 9 syndrome: Rethinking development delay. *Am J Med Genet* 1998; 80: 42-45.
2. Merino A, De Perdigo A, Nombalais F, Yvinec M, Le Roux MG, Bellec V. Prenatal diagnosis of trisomy 9 mosaicism: Two new cases. *Prenat Diagn* 1993; 13: 1001-1007.
3. Van Der Berg C, Ramlakhan SK, Van Opstal D, Branderburg H, Halley DJJ, Los FJ. Prenatal diagnosis of trisomy 9: Cytogenetic, FISH, and DNA studies. *Prenat Diagn* 1997; 17: 933-940.
4. Slater HR, Ralph A, Daniel A, Worthington S, Roberts C. A case of maternal uniparental disomy of chromosome 9 diagnosed prenatally and the related problem of residual trisomy. *Prenat Diagn* 2000; 20:930-932.
5. Appelman Z, Rosensaft J, Chemke J, Caspi B, Ashkenazi M, Mogilner MB. Trisomy 9 confined to the placenta: prenatal diagnosis and neonatal follow-up. *Am J Med Genet* 1991; 40: 461-466.
6. Pfeiffer RA, Ulmer R, Kniewald A, Wagner-Thiessen E. Prenatal diagnosis trisomy 9 mosaicism possibly limited to fetal membranes. *Prenat Diagn* 1984; 4:387-389.
7. Sherer DM, Wang N, Thompson HO, et al. An infant with trisomy 9 mosaicism presenting as a complete trisomy 9 by amniocentesis. *Prenat Diagn* 1992; 12: 31-37.
8. Chitty LS, Altman DG. Appendix: Charts of fetal measurements. In: Rodeck CH, Whittle MJ, eds. *Fetal Medicine, Basic Science and Clinical Practice*. London: Churchill Livingstone, 1999; 1095-1140.
9. Cantu ES, Eicher DJ, Pai S, Donahue CJ, Harley RA. Mosaic vs Nonmosaic trisomy 9: report of a liveborn infant evaluated by fluorescence in situ hybridization and review of the literature. *Am J Med Genet* 1996; 62:330-335.
10. Schwartz S, Ashai S, Meijboom EJ, Schwartz MF, Sun CCJ, Cohen, MM. Prenatal detection of trisomy 9 mosaicism. *Prenat Diagn* 1989; 9: 549-554.
11. Bronshtein M, Blazer S. Prenatal diagnosis of liver calcifications. *Obstet Gynecol* 1995; 86: 739-743.
12. Jay A, Kilby MD, Roberts E, et al. Prenatal diagnosis of mosaicism for partial trisomy 8: a case report including fetal pathology. *Prenat Diagn* 1999; 19: 976-979.