

Clinical, radiographic, ultrasonographic diagnosis, and treatment of urolithiasis in two domestic cats - case report

Eren POLAT^{1,a,*}, Aydın SAGLIYAN^{1,b}

¹Firat University, Faculty of Veterinary Medicine, Department of Surgery, Elazığ, Türkiye

^a<https://orcid.org/0000-0002-3999-1310>; ^b<https://orcid.org/0000-0002-8226-0740>

*Corresponding author: erenpolat@firat.edu.tr

Received date: 11.05.2022- Accepted date: 16.06.2022

Abstract: In this case report, clinical, radiographic, and ultrasonographic diagnosis, and operative treatment of uroliths encountered in the urinary bladder of two domestic cats were shared. In the radiographic and ultrasonographic examinations of both cats brought with complaints of intermittent urination, uroliths were detected in their urinary bladders. After the uroliths were removed by cystotomy operation, it was determined that both cats were followed for six months and were in good health and no recurrence was observed.

Keywords: Cat, cystotomy, ultrasonography, urolithiasis

Evcil iki kedide karşılaşılan ürolitlerin klinik, radyografik, ultrasonografik tanısı ve tedavisi

Özet: Bu olgu sunumunda, iki evcil kedinin idrar kesesinde karşılaşılan ürolitlerin klinik, radyografik ve ultrasonografik tanısı ile operatif tedavisi paylaşıldı. Kesik kesik idrar yapma şikâyetleri ile getirilen her iki kedinin radyografik ve ultrasonografik muayenelerinde idrar keselerinde ürolitler tespit edildi. Sistotomi operasyonu ile ürolitler uzaklaştırıldıktan sonra altı ay boyunca takip edilen her iki kedinin de sağlık durumlarının iyi olduğu ve nüks gözlenmediği belirlendi.

Anahtar Kelimeler: Kedi, sistotomi, ultrasonografi, ürolithiazis

Introduction

Urolithiasis is one of the most common lower urinary system problems in cats and dogs. Uroliths are formed as a result of the accumulation in the urinary system by reaching supersaturation of the minerals that need to be removed from the body with urine. It is named nephrolith, renolite, ureterolite, urecystolite, and urethrolite, depending on where it occurs. According to the mineral composition it contains, uroliths are named calcium oxalate, magnesium ammonium phosphate, cystine, and urate (Koehler et al., 2008; Sancak et al., 2009; Albanan et al., 2013; Tiruneh & Abdisa, 2017; Kopecny et al., 2021).

Many pathological and physiological factors affect the formation of uroliths. Anatomical and metabolic abnormalities, poor diets, urinary tract infections, and changes in urine pH are

important factors in the formation of uroliths. Some demographic factors such as species, race, age, gender, and sterilization may predispose to urolith formation. For example; it has been reported that urinary crystal is detected more frequently in dogs, mostly in breeds such as Miniature schnauzer, Shih tzu, Lhasa apso, and Yorkshire terrier. In cats, urinary crystals are more likely to be seen in domestic shorthairs (such as British shorthairs), Himalayan, Persian, and Ragdoll breeds. According to the Minnesota Urolith Center, the most common uroliths in dogs is struvite, while in cats calcium oxalate crystals (Lulich et al., 2000; Osborne et al., 2000; Houston & Moore, 2009; Albasan et al., 2013).

Urolithiasis causes clinical symptoms such as intermittent and painful urination, hematuria, and frequent urination position in cats and dogs. Sometimes, complaints such as the inability to urinate occur due to obstruction of the urethra. In these cases, kidney dysfunction occurs due to the inability to urinate, resulting in hydronephrosis and uremia. In advanced stages, it can cause irreversible fatal complications such as urinary bladder rupture (Sancak et al., 2009; Tiruneh & Abdisa, 2017; Küçük, 2020).

In the diagnosis of urolithiasis, besides anamnesis and clinical findings, the use of ultrasonography together with direct and indirect radiography is important. The fact that the urinary bladder creates a natural contrast due to its physiological structure enables the diagnosis to be made easily in direct radiography applications. In the ultrasonographic examination, it is detected in the urinary bladder as masses that have a hyperechoic appearance and cause acoustic shadow artifacts (Rinkardt & Houston, 2004; Langston et al., 2008; Sancak et al., 2009; Albasan et al., 2013; Tion et al., 2015; Tiruneh & Abdisa, 2017).

Cystotomy is the most commonly used operation in the treatment of uroliths (urecystolitis) in the urinary bladder. In urolithiasis cases, the patient's blood values are very important in the preoperative period. In particular, the presence of uremia and hyperkalemia, metabolic acidosis, and serum creatinine levels should be carefully monitored. In the postoperative period after cystotomy, antibiotic applications for urinary tract infections and urinary tract antiseptics should be applied. Again in this period, if the urine pH value is alkaline, it will be beneficial to acidify the urine by applying ascorbic acid. Otherwise, this situation should be carefully evaluated, as ascorbic acid will cause the recurrence of urinary stones (Sancak et al., 2009; Albasan et al., 2013; Tion et al., 2015).

This study, it was aimed to convey our experience to our colleagues and contribute to the literature by discussing the diagnosis and treatment stages of urolithiasis cases detected in two domestic cats.

Case Description

In this case report, the diagnosis and operative treatment of uroliths encountered in the urinary bladders of two domestic cats brought with the complaint of intermittent urination were discussed. The information obtained in line with both cats' anamnesis and laboratory examination is presented in Table.

Table: Findings obtained in accordance with the anamnesis and laboratory examination of the patients

	Case 1	Case 2
Breed	Crossbreed	Crossbreed
Gender	Female	Male
Age	6 years	2 years
Sterilization	+	-
Diet	Urinary cat food (containing 34% protein)	Home cooking
Complaint	Intermittent urination for 1 week	Difficulty urinating
Disease history	2 months ago urinary tract infection	Healthy
Water consumption	About 300 ml of purified water	Tap water
pH of urine	6.0	5.0

In clinical examination with palpation, it was determined that the urinary bladders of both cats were full and they urinated with a massage. In the radiographic examination, solid foreign masses with a radiopaque appearance were detected in the urinary bladder of the cats (Figure 1-A, B).

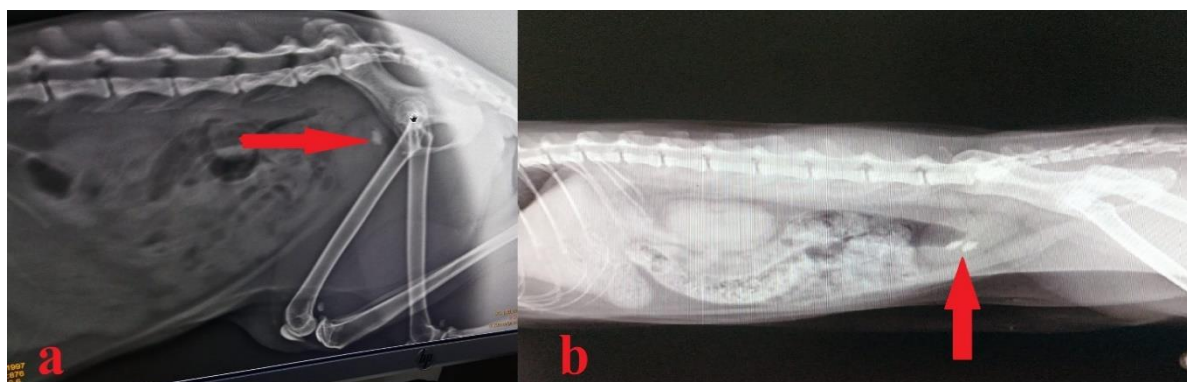


Figure 1: Uroliths (arrows) were detected on latero-lateral abdominal direct radiographs of cats with urolithiasis; case 1 (A), case 2 (B).

In the ultrasonographic examination, hyperechoic masses forming acoustic shadow artifacts were detected in the urinary bladders of both cats (Figure 2-A, B). According to the findings obtained as a result of anamnesis, clinical examination, and imaging methods, both cases were diagnosed with urolithiasis. While a single urolith was detected in case 1, two uroliths were detected in case 2.

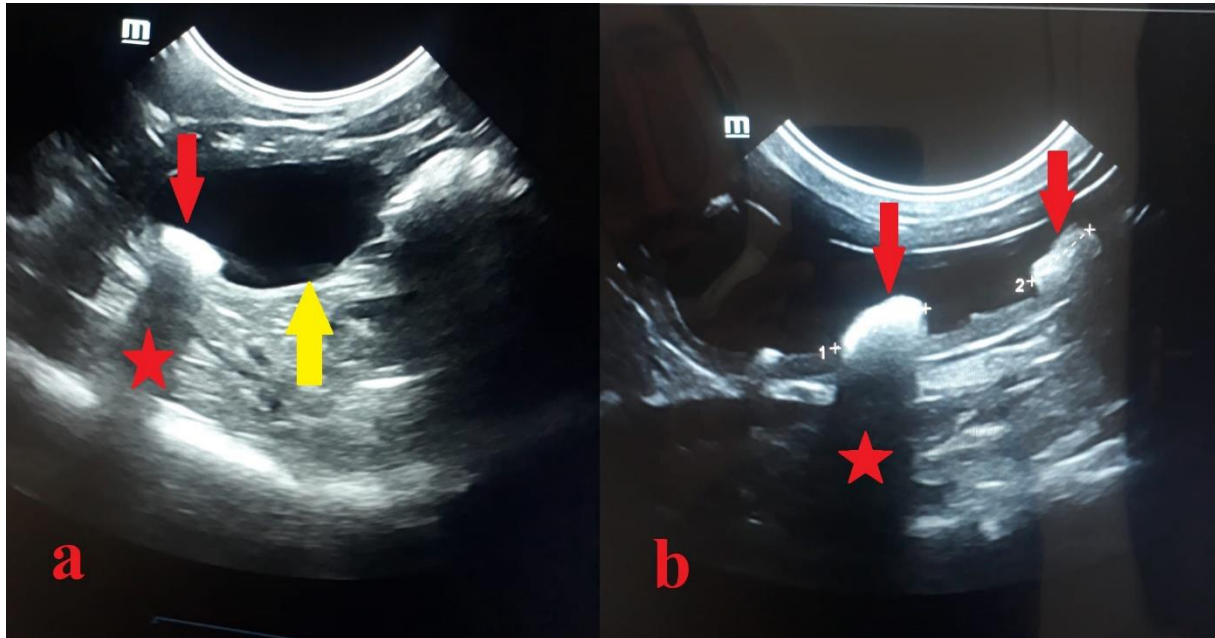


Figure 2: Uroliths (red arrows) and acoustic shadow artifacts (stars) were detected on abdominal ultrasonography of cats with urolithiasis; case 1 (A) and case 2 (B), urinary bladder (yellow arrow).

It was decided to remove the uroliths by performing a cystotomy operation on both cats with the diagnosis of urolithiasis. Before the operation, the patients were evaluated in terms of hyperkalemia, acidosis, and uremia. Since no abnormality was detected in the blood values of both patients, it was deemed appropriate to be operated on immediately. For the cystotomy operation, the operation area was prepared by shaving the abdomen from the level of the processus xiphoideus to the pubis. The patient was then placed on the operating table in the ventrodorsal position. A 2-3 cm long skin incision was made on the median line from the caudal of the umbilical cicatrix to both cats. Fat and connective tissue were bluntly dissected until the linea alba was visible. After exposing the linea alba, the abdomen was opened with scissors with a blunt end. Then, the urinary bladder was taken out from the abdomen with slow movements. The urinary bladder, which was surrounded by absorbent sponges, was opened by making a 0.5 cm long incision on its long axis from the region with the least vascularization. After removing the stones in the urinary bladder and washing the bladder with the help of

anatomical forceps, a 1.0 mm catheter was placed from the urinary bladder to the urethra by the anterograde route and it was checked whether there was an obstruction in the urethra. After cleaning the uroliths in the urinary bladder and urethra, the urinary bladder was closed with absorbable suture material (Vicryl, USP 3-0, USA) using *Schmieden* and *Cushing* sutures. After making sure that there was no leakage from the bladder, the abdomen was closed with a standard surgical procedure. Postoperatively, amoxicillin-clavulanic acid (Synulox, Zoetis, Turkey) was administered intramuscularly at a dose of 8.75 mg/kg/day. In addition, methenamine (Purinol, Recordati İlaç San., Turkey) at a dose of 50 mg/kg was administered orally, divided into three, during the day. In the controls performed on the 15th, 30th, 60th, and 180th days, it was determined that the general condition of the cats was good and there were no signs of recurrence of uroliths.

Discussion

Urolithiasis is a chronic lower urinary system problem in many animal species, which is characterized by intermittent urination, pain during urination, and hematuria (Küçük, 2020; Aké-Chiñas et al., 2022). It has been reported that urolithiasis is detected in 25% of cats with lower urinary system problems (Sancak et al., 2009). In this case report, it was learned that both cats had complaints of intermittent urination.

Studies are reporting that the incidence of urolithiasis cases in males and females is equal (Grauer, 1993). However, in some studies (Houston & Moore, 2009), it has been reported that urolithiasis cases are more likely to be seen in females, and some studies (Sancak et al., 2009) in males. In this study, one of the two cats with urolithiasis is male and the other is female.

Some types of uroliths are formed mostly in acidic urine (such as urate, uric acid, and calcium oxalate), while some types of uroliths are formed mostly in alkaline urine (such as struvite, calcium carbonate). Urine pH in cats and dogs varies between 6.0-7.5 (Rizzi, 2014). In one study, the urinary pH of cats was reported as 6.0 - 6.4 (Küçük, 2020). In this case report, one of the cats had a urinary pH of 6.0, while the other had a urinary pH of 5.0. The diets used in the nutrition of cats are very important in the formation of urolithiasis. In this study, it was determined that one of the cats with urolith was fed with a commercial food containing 34% crude protein developed against urinary diseases, and the other was fed with homemade food.

In the diagnosis of urolithiasis cases, direct and indirect radiography and ultrasonography are very important. The formation of a natural contrast due to the contents of the urinary bladder allows easy detection of radiopaque uroliths on direct radiographs. Again, in ultrasonographic examinations, uroliths in the urinary bladder can be detected as masses with a hyperechoic

appearance and an acoustic shadow artifact (Rinkardt & Houston, 2004; Langston et al., 2008; Sancak et al., 2009; Albasan et al., 2013; Tion et al., 2015; Tiruneh & Abdisa, 2017). In this case report, uroliths in the urinary bladder of both cats were revealed by direct radiography and ultrasonography.

Urolithiasis cases in the urinary bladder can be treated conservatively and operatively. In conservative treatment, appropriate diet applications are made according to the type of urolith. At the same time, urinary tract antiseptics and parenteral antibiotics are also applied. Again, ascorbic acid applications can be made in some urolith types (such as struvite), and allopurinol (xanthine oxidase inhibitor) applications can be made in some urolith types (such as urate). Uroliths, which are difficult to dissolve in the urinary bladder, obstruct the passage to the urethra and make urination difficult, may need to be removed with a cystotomy operation (Sancak et al., 2009; Albasan et al., 2013; Tion et al., 2015; Küçük, 2020). In this case report, it was decided to perform a cystotomy because conservative treatment of uroliths detected in both cats was not possible. As a result of the cystotomy, a single urolith was removed in one of the cats and two in the other.

Conclusion

It has been revealed that the importance of direct radiography and ultrasonography in the diagnosis of urinary bladder uroliths, the importance of diets applied to cats in urinary stones and cystotomy is a viable treatment options.

Financial Support

This research received no grant from any funding agency/sector.

Ethical Statement

This study does not present any ethical concerns.

Conflict of Interest

The authors declared that there is no conflict of interest.

References

Albasan, H., Osborne, C.A., Lulich, J.P., & Sancak, A.A. (2013). Köpek ve kedilerde ürolitiazis. *Türkiye Klinikleri Journal Veterinary Sciences*, 4(2), 39-52.

- Aké-Chiñas, M.A., Mendoza-López, C.I., Del-Angel-Caraza, J., Quijano-Hernández, I.A., Rodríguez-Alarcón, C.A., & Barbosa-Mireles, M.A. (2022). Canine struvite urolithiasis: Epidemiological and clinical characteristics in Mexico. *Journal MVZ Cordoba*, 27(1), 1-10. <https://doi.org/10.21897/rmvz.2338>
- Grauer, G.F. (1993). Medical treatment of canine uroliths. In: D. Slatter (Ed.), *Textbook of Small Animal Surgery* (1st ed., pp. 1488-1495). W.B. Saunders Company, Philadelphia.
- Houston, D.M., & Moore, A.P.E. (2009). Canine and feline urolithiasis: Examination of over 50 000 urolith submissions to the Canadian Veterinary Urolith Centre from 1998 to 2008. *Canadian Veterinary Journal*, 50(12), 1263–1268.
- Koehler, L.A., Osborne, C.A., Buettner, M.T., Lulich, J.P., & Behnke, R. (2008). Canine uroliths: frequently asked questions and their answers. *Veterinary Clinical Small Animal*, 39(1), 161–181. <https://doi.org/10.1016/j.cvsm.2008.09.007>
- Kopecny, L., Palm, C.A., Segev, G., & Westropp, J.L. (2021). Urolithiasis in dogs: evaluation of trends in urolith composition and risk factors (2006-2018). *Journal Veterinary Internal Medicine*, 35, 1406–1415. <https://doi.org/10.1111/jvim.16114>
- Küçük, O. (2020). *Pratik kedi ve köpek besleme-beslenme hastalıkları* (1st ed.). Verda Yayıncılık.
- Langston, C., Gisselman, K., Palma, D., & McCue, J. (2008). Diagnosis of urolithiasis. compendium on continuing education for veterinarians. *Compendium*, 30(8), 447-454.
- Lulich, J.P., Osborne, C.A., Bartges, J.W., & Lekcharoensuk, C. (2000). Canine lower urinary tract disorders. In: S. J. Ettinger, & E. C. Feldman (Eds.), *Textbook of Veterinary Internal Medicine* (5th ed., pp. 1747-1781). W.B. Saunders Company, Philadelphia.
- Osborne, C.A., Kruger, J.M., Lulich, J.P., Polzin, D.J., & Lekcharoensuk, C. (2000). Feline lower urinary tract disorders. In: S. J. Ettinger, & E. C. Feldman (Eds.), *Textbook of Veterinary Internal Medicine* (5th ed., pp. 1710-1747). W.B. Saunders Company, Philadelphia.
- Rinkardt, N.E., & Houston, D.M. (2004). Dissolution of infection-induced struvite bladder stones by using a noncalculolytic diet and antibiotic therapy. *Canadian Veterinary Journal*, 45, 838–840.
- Rizzi, T.E. (2014). Urinalysis in companion animals part 2: evaluation of urine chemistry & sediment. *Today's Veterinary Practice*, 86-91.

- Sancak, I.G., Özgencil, F.E., & Sancak, A.A. (2009). Fakülte kliniklerine gelen (2002-2003) kedi ve köpeklerde ürolitiazis olgularının klinik değerlendirilmesi. *Ankara Üniversitesi Veteriner Fakültesi Dergisi*, 56, 105-111.
- Tion, M.T., Dvorska, J., & Saganuwan, S.A. (2015). A review on urolithiasis in dogs and cats. *Bulgarian Journal of Veterinary Medicine*, 18(1), 1-18, <https://doi.org/10.15547/bjvm.806>
- Tiruneh, D., & Abdisa, T. (2017). Review on canine urolithiasis. *American Research Journal of Veterinary Medicine*, 1(1), 1-7.