

Ca(OH)² Apexification to a Tooth with Chronic Apical Abscess: A Case Report

Kübra MUMCU^{1*} Mehmet Sinan DOĞAN²

1. Harran University, Faculty of Dentistry, Department of Pediatric Dentistry, Şanlıurfa, TURKEY.
2. Harran University, Faculty of Dentistry, Department of Pediatric Dentistry, Şanlıurfa, TURKEY.

*Corresponding author: Mumcu K, MSc, Department of Pediatric Dentistry, Faculty of Dentistry, Harran University Şanlıurfa, Turkey.
E-mail: dr.kubramumcu@harran.edu.tr

Abstract

In the period when the root development of children's teeth continues, trauma or caries to the teeth stops this root development. If the pulp becomes devitalized in immature permanent teeth due to dental trauma or infection, apexification treatment should be performed to continue root development. In this case report, a chronic apical abscess was observed in an immature permanent central tooth whose pulp was exposed as a result of dental trauma and did not receive any treatment for two years. As a result of clinical-radiological examination, Ca(OH)² apexification treatment was planned. It has been observed that root formation continues in each session with the periodic renewal of Ca(OH)².

Case Report (HRU Int J Dent Oral Res 2022; 2(2): 134-138)

Keywords: Apexification, apexification with Ca(OH)₂, complicated crown fracture

Introduction

When periapical lesion and necrosis develop in an immature permanent tooth whose root apex is open or root development is incomplete, it isn't easy to treat with conventional endodontic treatment methods. Ensuring asepsis in the root canal and creating an apical stop at the root tip are the main elements in the success of endodontic treatment. In cases where apical closure does not occur naturally in an immature permanent tooth, the main purpose is to create a periapical barrier or stop instead of using root canal filling material to prevent excessive extrusion of the tooth.(1,2) For this purpose, apexification treatment is performed instead of traditional endodontic treatment. Apexification is a procedure that promotes the formation of an apical barrier to close the open apex of a devital immature permanent tooth so that filling materials can be retained within the root canal space. The capacity of materials such as calcium hydroxide [Ca(OH)²] to induce the formation of this calcific barrier at the apex makes apexification possible.

Clinically, when it is understood that the pulp of an immature permanent tooth is devital and the root will not develop further in terms of apical maturation and thickening of the dentin walls, apexification is performed to close the root tip (3).

Because calcium hydroxide is biologically compatible with pulp and periodontal tissue, it is a successful material that is frequently used in dentistry. Calcium hydroxide was first used by Frank in the treatment of apexification, so it was referred to as the "Frank technique" in the literature (4). The success of apexification treatment using calcium hydroxide is between 74-100% in studies. This success rate of calcium hydroxide;

- Stimulating apical development by providing asepsis in periapical tissues,
- Accelerating cementogenesis at the apex by transforming undifferentiated mesenchymal cells into cementoblasts,
- Ensuring the development of calcification under the necrosis layer formed due to its high pH,

- The Ca ions it contains have a reducing effect on capillary leakage,
- To prevent granulation tissue from advancing into the canal by filling the canal space,
- It has been observed that while activating alkaline phosphatase and pyrophosphatase enzymes, it inhibits osteoclastic activity and forms a hard tissue barrier with the help of all these mechanisms (4,5,6). For all these reasons, calcium hydroxide, has gained the widest acceptance in the treatment of apexification, although various materials have been proposed (6). In our case, we aimed to provide an apical stop using the Frank technique. In our case, the pulp of the left central tooth was exposed as a result of trauma, and a chronic apical abscess developed in the immature permanent tooth, which had not received any treatment for a long time. Root development was evident in each session of the patient, in whom we started apexification treatment using calcium hydroxide. In our patient, whose main aim was to create a stop at the apical level, successful treatment was achieved by providing root development.

Case Report

In the anamnesis taken from the parents of a 9-year-old girl, who applied to the pediatric dentistry clinic of Harran University, it was learned that she fell while walking backwards and forwards two years ago and had a fracture in her left central incisor. In the intraoral examination, a complicated crown fracture with pulp exposure area and its area in tooth number 21 and a fistula on the labial surface of the tooth was seen. In the radiographic examination, it was determined that root development was not completed, and there was a radiolucent area around the root. It was learned that the patient did not have any systemic health problems (Figure 1-2).

Informed consent was obtained from the parents, and treatment was started. It was decided to treat tooth 21 with $\text{Ca}(\text{OH})_2$ apexification. Since the pulp exposure area was large in the first session, irrigation with 2.5% sodium hypochlorite was started. During irrigation, the pen tip pieces were removed from the exposure area. (Figure 3) After adequate irrigation, the root canal was dried with sterile paper cones and filled with calcium hydroxide temporary canal sealer (Kalsin, Turkey) and temporarily filled with glass ionomer cement. (Kavitan Plus, Pentron, Czech Republic).

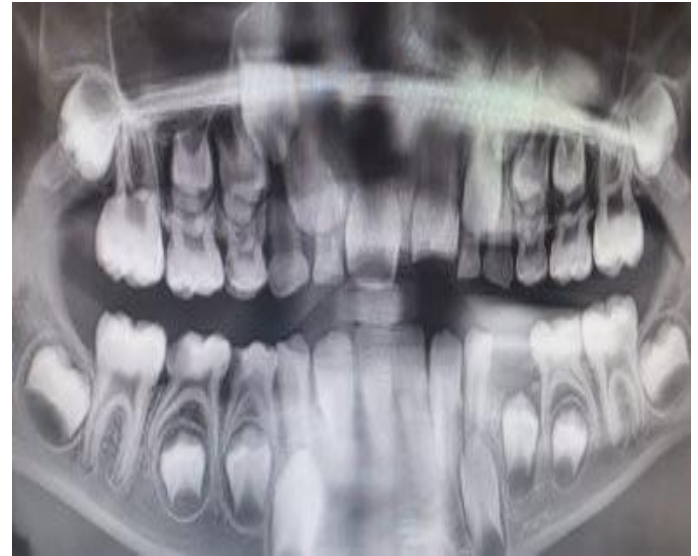

Figure 1. Radiographic image taken before treatment

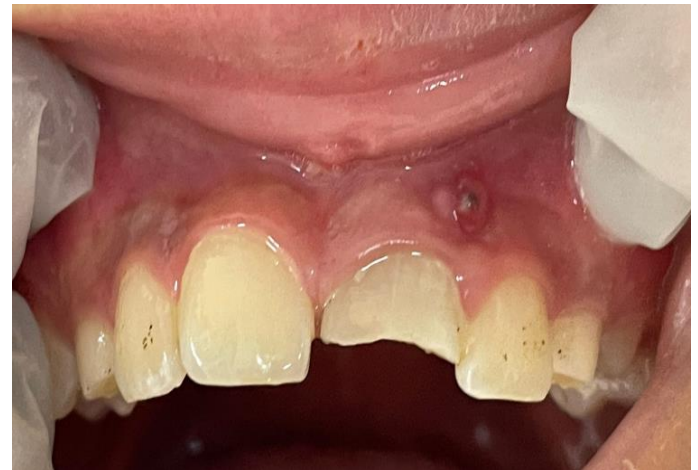

Figure 2. Clinical image taken before

In the session 1 month later, it was observed that there was no pain on percussion and palpation in tooth 21 and the fistula tract was closed. The root canal was washed with 2 ml of 2.5% NaOCl solution to remove the calcium hydroxide and smear layer in the canal. Root development was checked by taking a periapical film. After adequate irrigation, it was temporarily resealed with glass ionomer cement (Figure 4-5).

In the session three months later, the periapical film was taken with standard canal files (Denco K and H File standard Canal file, Shenzhen perfect medical, China) after irrigation with sodium hypochlorite to see root formation and the presence of apical plug. (Figure 6-7) Periodic 3-month appointments were given to the patient, and intracanal $\text{Ca}(\text{OH})_2$ regeneration, root development, and apex formation were followed up.

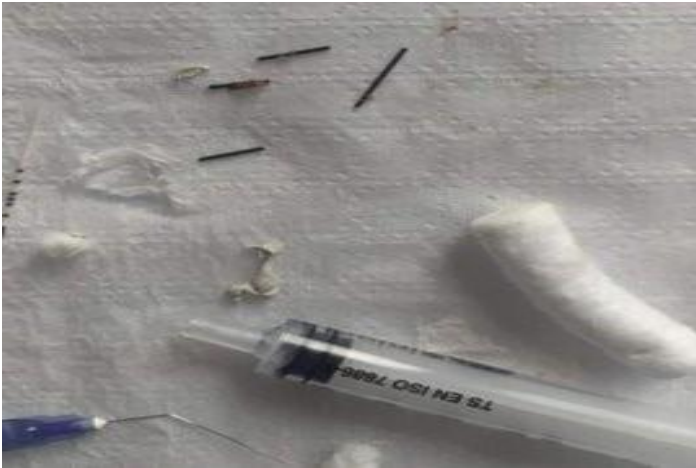

Figure 3. Pen tip pieces that came out of the canal the as a result of irrigation in the 1st session

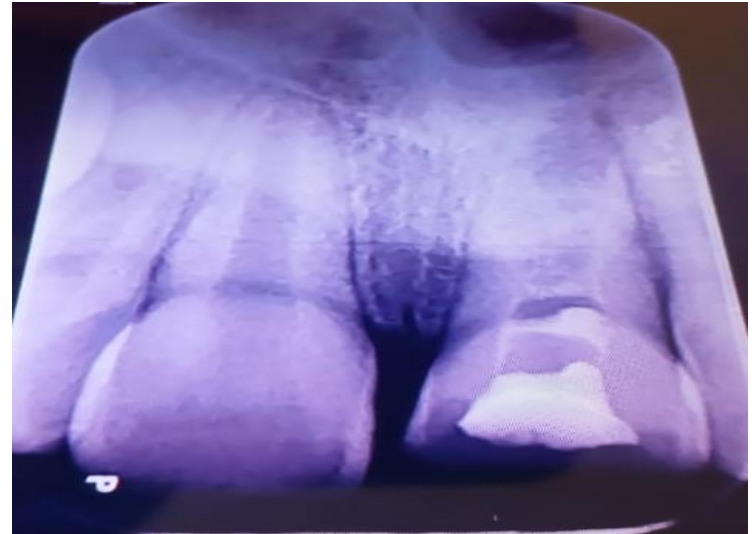


Figure 6. Radiographic image taken in the 3rd session

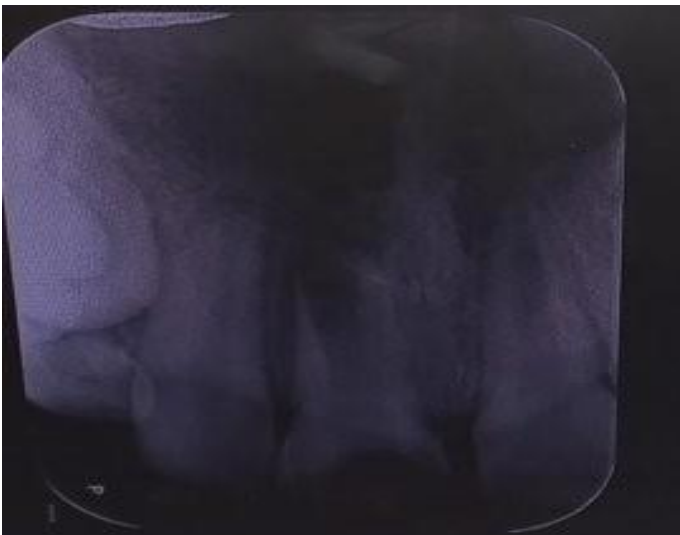


Figure 4. Radiographic image taken before treatment in the 1st session

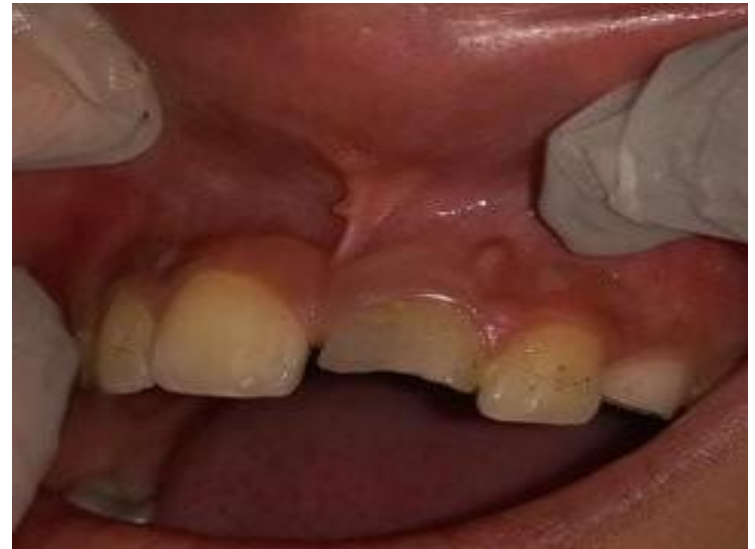

Figure 7. The clinical image taken before the treatment in the 3rd session

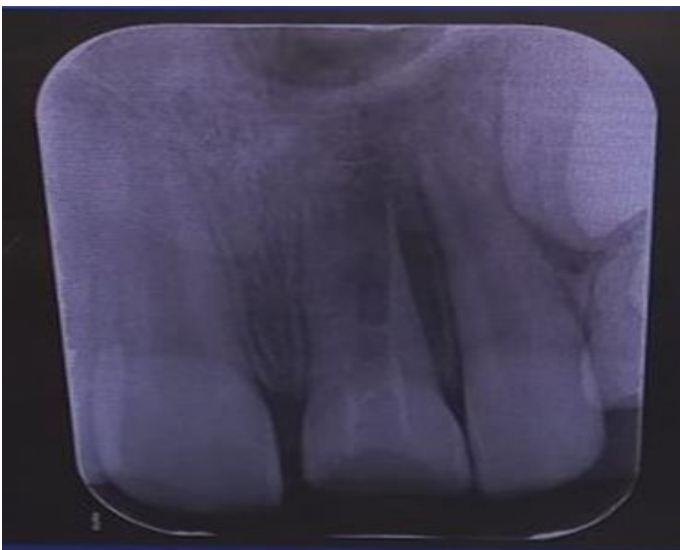

Figure 5. Radiographic image taken after calcination in the 2nd session

Discussion

Pulp necrosis can be caused by trauma or various damages and usually results in the root development stop of immature permanent teeth. Immature permanent necrotic teeth remain with open apex and thin and short root walls. Other causes of open apex include: chronic periapical periodontitis causing apical resorption, apical resorption due to trauma, destruction of apical narrowing during mechanical debridement, apicalectomy without the use of root tip filling material, and horizontal root fracture (7).

Conventional root canal treatment cannot be used for endodontic treatment of immature permanent necrotic teeth. Since the apex of these teeth is open, it is difficult to create a barrier at the apical level. Many endodontic treatment methods are used for this: Many procedures can be applied including reverse use of gutta-perchas on anterior maxillary teeth, orthograde use of polyantibiotic drugs or materials such as calcium hydroxide, retrograde closure of open apices, and orthograde use of mineral trioxide aggregate in a single session. This form of treatment is called apexification (8). In our case, chronic apical abscess developed as a result of trauma, as no treatment was given in the early period. We decided to perform apexification with orthograde use of calcium hydroxide as a treatment. We prefer calcium hydroxide because it is easy to use and obtain.

It has been demonstrated in many studies that calcium hydroxide, which is an intracanal drug used for apexification and available in many forms, has had great success from the past to the present. However, the time taken for successful apexification differed in these studies. Walia et al. observed that the treatment time of narrow open-ended teeth was shorter in older children than in younger children. In contrast, Dominguez et al found that the presence or absence of apical pathology prior to treatment hardly affects the duration of treatment for successful apical closure. Sheehy and Roberts found that the mean time for apical barrier formation is approximately 5 to 20 months. In addition, the type of apical closure in apexification also changes (9).

One study by Ballezio found three types of apical barrier formation (10);

1. Physiological development of the apical portion with a final root length equal to the contralateral tooth.
2. Head-like barrier formation.
3. Apical development with final root length, forming different layers of mineralized tissue in a slightly shorter time than the opposite intact tooth.

Weine, on the other hand, described four different types of apical healing in the treatment of apexification with calcium hydroxide. These recovery types can be explained as follows:(11)

1. There is no radiographic change, the barrier can be felt with hand sensitivity.
2. The barrier at or near the apex can be observed by radiography.
3. Root tip closed without change in canal size.
4. Root development, continued and the apex closed.

In control sessions; If the file used for control does not pass through the apical area, the patient does not feel that the file is touching, and the tip of the paper subject

inserted into the canal is dry, the apexification process is completed; otherwise the apexification application should be continued.(11)In our case, according to the studies of Ballezio and Weine, it was observed that root development continued and there was a tendency towards equal root length as in the contralateral tooth.

Another factor affecting the success of apexification is disinfecting the root canals. This can be achieved using mechanical instrumentation and chemical irrigation for disinfection. (12) Sodium hypochlorite is the most commonly used solution for root canal disinfection. Sodium hypochlorite (NaOCl); effective against biofilms. At the same time, it dissolves the organic structures in the root canal. However, NaOCl solutions are insufficient to remove the hard tissue residues accumulated during mechanical instrumentation and dissolve the inorganic structures of the smear layer. Therefore, application of the chelating agent ethylenediaminetetraacetic acid (EDTA) is necessary. However, EDTA has been found to destroy active chlorine when combined with NaOCl. It can also abrade dentin if overused. For this reason, EDTA is recommended to be used as a final irrigant before root filling or placing intermediate dressings. (13,14) The use of EDTA to remove Ca(OH)₂ from root canals may damage the hard tissue formed clinically after EDTA apexification. (15) Another irrigation solution other than NaOCl is chlorhexidine (CHX); It has extensive activity against gram (+) and gram (-) bacteria. However, CHX has less effect on microbial biofilm than NaOCl. In addition, another disadvantage is that unlike NaOCl, CHX does not have the ability to dissolve textures. Therefore, NaOCl is still used as a primary irrigation solution in endodontics. (16) In our case, for all these reasons, we used NaOCl and saline as irrigation solution.

As for the success rate of apexification with calcium hydroxide, Sheehy and Roberts, Gu et al., and Morse et al. showed 74-100%, 94% and 100%, respectively, with the use of different forms of Ca(OH)₂ (9).

As an alternative to apexification, regeneration is one of the treatment methods applied in immature permanent necrotic teeth. However, regeneration is mostly recommended for short roots with wide-open root tips, thin canal walls and teeth without root formation potential. In addition to these, regeneration is also recommended in cases where the prognosis of the tooth is hopeless despite the apexification procedure. Apexification, on the other hand, is recommended in teeth whose apex opening has almost completed root formation. Regenerative endodontic treatments are a biologically based process that aims to replace damaged

structures (necrotic) such as roots and dentin with cells of the pulp-dentin complex (vital cells) (17). The triple antibiotic paste used in the revascularization method, which is one of the regeneration applications, has a harmful effect on the stem cells in the apical papilla, causes bacterial resistance and coronal coloration, the source of the stem cell is difficult to identify in adult stem cell therapy, the problem of creating functional pulp tissue in pulp implantation and the risk for patient health, difficulty in obtaining high porosity and equal pore size in synthetic scaffold materials, development of sensitivity reactions in natural scaffold materials, unpredictability of the concentration and composition of cells trapped in the fibrin clot when blood clot is used as scaffold, clinical application of platelet-rich fibrin is difficult and it requires special equipment,

Since there are limitations in gene therapy method, such as the inability to obtain the vector providing gene transfer, these techniques cannot be used frequently in clinical applications today. Studies in the literature are mostly animal experiments or in-vitro studies, and studies on humans are composed of case reports. Due to their field of work, it is important for pediatric dentists to have detailed information about promising regenerative applications, to share their results by conducting studies, and to strive to improve existing methods. It is thought that more in-vivo and in-vitro human, animal and laboratory studies on the subject with long-term follow-up can eliminate the existing disadvantages in terms of clinical applications (18).

Apexification treatment in children is to continue the root development, as well as to positively affect the child's psychology by providing function and aesthetics. The primary aim of the dentist should be to apply a treatment that ensures the continuity of the tooth's vitality and, where this is not possible, the continuation of the root formation of the tooth (12).

References

1. Hachmeister DR, Schindler WG, Walker WA 3rd, Thomas DD. The sealing ability and retention characteristics of mineral trioxide aggregate in a model of apexification. *J Endod.* 2002;28(5):386-90.
2. Guerrero F, Mendoza A, Ribas D, Aspiazu K. Apexification: A systematic review. *J Conserv Dent.* 2018;21(5):462-465.
3. Huang GT. Apexification: the beginning of its end. *Int Endod J.* 2009;42(10):855-66.
4. Çelenk S, et al. Apeksifikasyon (vaka raporu). *CÜ Dişhek Fak Derg.* 2000;3(2):130-2.
5. Bezgin T, Sönmez H. Current Approaches in Apexification Treatment. *Türkiye Klinikleri J Dental Sci* 2012;18(3), 304-311.
6. Rafter M. Apexification: a review. *Dent Traumatol.* 2005;21(1):1-8.
7. Agrafioti A, Giannakoulas DG, Filippatos CG, Kontakiotis EG. Analysis of clinical studies related to apexification techniques. *Eur J Paediatr Dent.* 2017;18(4):273-284.
8. Pate A, Choksi D, Idnani B. Apexification: creating obstruction for construction. *Journal of dental sciences.* 2018; 8(1):7-13.

9. Ghosh S, Mazumdar D, Ray PK, Bhattacharya B. Comparative evaluation of different forms of calcium hydroxide in apexification. *Contemp Clin Dent.* 2014;5(1):6-12.
10. Ballesio I, Marchetti E, Mummolo S, Marzo G. Radiographic appearance of apical closure in apexification: follow-up after 7-13 years. *Eur J Paediatr Dent.* 2006;7(1):29-34.
11. Demiriz L, Çetiner S. Nekrotik Pulpalı İmmatür Dişlerde Tedavi Yaklaşımları. *ADO Klinik Bilimler Dergisi.* 2011;5(1): 770-781.
12. Mohammadi Z. Sodium hypochlorite in endodontics: an update review. *Int Dent J.* 2008;58(6):329-41.
13. Ballal NV, Gandhi P, Shenoy PA, Shenoy Belle V, Bhat V, Rechenberg DK, Zehnder M. Safety assessment of an etidronate in a sodium hypochlorite solution: randomized double-blind trial. *Int Endod J.* 2019;52(9):1274-1282.
14. Grawehr M, Sener B, Waltimo T, Zehnder M. Interactions of ethylenediamine tetraacetic acid with sodium hypochlorite in aqueous solutions. *Int Endod J.* 2003;36(6):411-7.
15. Ok E, Altunsoy M, Tanriver M, Çapar İD. Effectiveness of different irrigation protocols on calcium hydroxide removal from simulated immature teeth after apexification. *Acta Biomater Odontol Scand.* 2015;1(1):1-5.
16. Erik, CE, Maden M, Çelik G. Endodontide Kullanılan İrrigasyon Solüsyonları. *SDÜ Sağlık Bilimleri Dergisi.* 2018; 9(3):31-38.
17. Panda P, Mishra L, Govind S, Panda S, Lapinska B. Clinical Outcome and Comparison of Regenerative and Apexification Intervention in Young Immature Necrotic Teeth-A Systematic Review and Meta-Analysis. *J Clin Med.* 2022;11(13):3909.
18. Ceyhan D, Akdik C. Apeksifikasyondan Apeksogenezise Geleneksel ve Güncel Tedavi Yöntemleri. *EÜ Dişhek Fak Derg.* 2018; 39(1): 8-18.
19. Kırzioğlu Z, Altun A. Genç daimi dişlerde kök ucu oluşumunun devamını sağlayan tedavi yöntemi: apeksifikasyon. *Cumhuriyet Dental Journal.* 2011;12(2):168-178.