



ORIGINAL RESEARCH

PROTECTIVE EFFECTS OF 2-MERCAPTOETHANE SULFONATE (MESNA) ON PROTAMINE SULFATE INDUCED BLADDER DAMAGE

Beyhan Sağlam¹, Esra Cıkler¹, Ali Zeybek², Şule Çetinel¹, Feriha Ercan¹, Göksel Şener³

¹Department of Histology and Embryology, School of Medicine, Marmara University, İstanbul, Turkey ²Department of Anatomy, School of Medicine, Kocaeli University, Kocaeli, Turkey ³Department of Pharmacology, School of Pharmacy, Marmara University, İstanbul, Turkey

ABSTRACT

Objective: This morphological and biochemical study aims to investigate the putative protective effects of 2-mercaptoethane sulfonate (MESNA) on protamine sulfate (PS) induced bladder injury.

Material and methods: Wistar albino female rats were catheterized and intravesically infused with phosphate buffered solution-PBS (control group) or PS (PS group) dissolved in PBS. In the PS + MESNA group after the PS instillation MESNA (50 mg/kg) was injected intraperitoneally for three days. Bladder morphology was investigated by light and scanning electron microscopy. Tissue samples were also obtained to determine bladder malondialdehyde and glutathione levels.

Results: In the PS group ulcerated areas, an irregular mucus layer, inflammatory cell infiltration, increased number of mast cells were observed. In the PS + MESNA group a relatively normal urothelial topography, glycosaminoglycan layer and decreased number of mucosal mast cells and inflammatory cells were observed. Increased malondialdehyde levels as a result of PS induction lead us to propose that free radicals may have a critical role in this injury. The decrease in malondialdehyde and increase in glutathione levels in the PS + MESNA group was in accordance with morphological findings.

Conclusion: Based on the results, MESNA treatment significantly prevented PS induced degenerative changes in the bladder

Keywords: MESNA, Protamine sulfate, Urinary bladder

2-MERCAPTOETAN SÜLFONAT (MESNA)'IN, PROTAMİN SÜLFATIN TETİKLEDİĞİ MESANE HASARI ÜZERİNDEKİ KORUYUCU ETKİLERİ

ÖZET

Amaç: Bu morfolojik ve biyokimyasal çalışmanın amacı 2-mercaptoetan sulfonat (MESNA)'ın protamin sülfat (PS)' in tetiklediği mesane hasarı üzerindeki koruyucu etkilerinin araştırılmasıdır.

Gereç ve Yöntem: Wistar albino dişi sıçanlar kateterize edilerek mesane içine fosfat tamponu (kontrol grubu) ya da fosfat tamponu içinde çözünmüş PS (PS grubu) infüze edildi. PS + MESNA grubundaki sıçanlara PS verilmesinden sonra, 3 gün boyunca, 50 mg/kg MESNA i.p. olarak enjekte edildi. Mesane morfolojileri ışık ve taramalı elektron mikroskopi düzeylerinde incelendi; ayrıca dokudaki malondialdehit ve glutatyon düzeylerine de bakıldı.

Bulgular: PS grubunda ülserli alanlar, düzensiz mukus tabakası, inflamatuvar hücre infiltrasyonu ve mast hücre sayısında artış gözlemlendi. PS + MESNA grubunda PS grubuna oranla, normal ürotel görüntüsü ve glikozaminoglikan tabakası ile inflamatuvar hücrelerin ve mukozal mast hücrelerinin sayısında azalma izlendi. PS' nin tetiklemesi ile oluşan hasarda önemli rol oynayabilecek olan serbest radikallerin ortaya çıkması sonucunda malondialdehit düzeyi artmış glutatyon düzeyi ise düşmüş bulundu. PS + MESNA grubunda morfolojik bulgularla uyumlu olarak, malondialdehit düzeyi önemli derecede düşmüş, glutatyon düzeyi ise artmıştır.

Sonuç: Bu bulgular, mesane mukozasında PS' in tetiklediği morfolojik hasar ve biyokimyasal değişikliklerin MESNA tedavisi ile önemli düzeyde önenebileceğini göstermektedir.

Keywords: MESNA, Protamin sülfat, Mesane

INTRODUCTION

Protamine sulfate (PS) is an arginine-rich protein with a molecular weight of 5000. It has strong alkali and polycationic components¹. When protamine is added to heparin in vitro, stable deposits occur between the two components because of ionic influence. After it was shown

that protamine sulfate neutralizes heparin in vivo, it was used to aid recovery from the anticoagulant effect of heparin¹. PS changes the permeability of different types of epithelium based on its concentration in the environment. Later, other effects of protamine sulfate were observed^{2,3}, including its effects on permeability of the

Corresponding author: Şule Çetinel, M.D.,
Department of Histology and Embryology,
School of Medicine, Marmara University,
Tıbbiye Cad. No: 49, Haydarpaşa, İstanbul, Turkey.
E-mail: sulecet@superonline.com

Marmara Medical Journal 2005;18(1);6-12



endothelium and the types of epithelium²⁻⁴. PS and urea given intravesically cause de-epithelization of the epithelial tissue. This procedure is now used as an in situ treatment for bladder carcinoma⁵.

Interstitial cystitis (IC) is a sterile bladder condition that occurs almost exclusively in women (90%). This disease is characterized by urinary frequency, urgency, burning and suprapubic pain.⁶ Among the proposed theories are infection⁷ autoimmunity⁸ the presence of toxic substances in the urine⁹ and psychiatric causes¹⁰. The morphological criteria for research into IC were established by The National Institute of Health (NIH), and the National Institute of Arthritis, Digestive, Diabetic and Kidney Diseases (NIDDKD). Mononuclear inflammation, mucosal hemorrhage, and deficiencies in the mucous layer of the bladder, epithelial disruption and increased mast cells in the urothelium are the criteria included¹⁰.

2-Mercaptoethane sulfonate (MESNA) is a synthetic small molecule that has the potential to scavenge reactive oxygen metabolites (ROM) by virtue of its sulfhydryl group.¹¹ MESNA was proven to be effective as an antioxidant drug in various in vivo and in vitro models¹². MESNA binds acrolein within the urinary tract and detoxifies it; the resulting inert the other does not induce damage to the urothelium^{13,14}. It is widely used as a systemic protective agent against the toxicity of chemotherapy and is primarily used to reduce hemorrhagic cystitis induced by cyclophosphamide¹⁵. Although MESNA has been widely used as an agent against cyclophosphamide-induced cystitis, significant hemorrhagic cystitis, defined as an episode of symptomatic (burning, frequency, and dysuria), microscopic, or macroscopic hematuria has been encountered clinically¹⁶. In addition, MESNA was shown to inhibit the development of bladder tumor in rats¹⁷ and by increasing the kidney levels of free thiol levels it was shown to prevent renal oxidative damage in rats treated with ferric nitrilotriacetate¹⁸. Owing to its direct suppressive effect on the production of hydrogen peroxide, thiol-containing MESNA may be considered as an antioxidant drug to limit the toxic effects of free radicals produced by all kinds of oxidative injuries.

In the present study, the putative protective effect of MESNA against PS-induced urinary bladder damage was examined using morphological

techniques such as light and scanning microscopy, and biochemical approaches such as measurement of urinary bladder malondialdehyde (MDA) and glutathione (GSH) levels.

METHODS

Animals: Wistar albino adult female rats weighing 180-200 g. were used in this study. They were housed individually in light and temperature controlled rooms on a 12/12 light-dark cycle. They had free access to standard pellet laboratory chow and water.

Experimental group: Three groups of 6 rats each were used, including the control, PS and PS + MESNA groups. Bladder injury was induced with grade x PS (Sigma Chemical Co., St. Louis, Missouri) applied intravesically by a PE50 catheter at a dose of 5 mg/ml twice in 24 hours (protamine sulfate group). Each time 0.2 ml solution was instilled to the bladder. In the PS + MESNA group 2 hours after the second PS dose, 150 mg/kg MESNA was injected intraperitoneally twice daily for 3 days (PS + MESNA group). In the control group only phosphate buffered solution was instilled twice daily. All instillations were performed with the animal under light anesthesia. Bladder samples were removed after the experiments and processed for morphological and biochemical investigations.

Microscopic Preparation: For light microscopy, urinary bladder samples were fixed in 10% formaldehyde and processed routinely.. Tissue sections (5 µm) were stained with hematoxylin and eosin (H&E) for general morphology and with 0,5% acidified toluidine blue (ph 2,5) for mast cells. Stained sections were examined under an Olympus BX51 photomicroscope.

For scanning electron microscopy the samples were fixed in 4% phosphate buffered gluteraldehyde (0.13 M and PH 7,4) for 4 hours, postfixed with 1% OsO4 for one hour, and processed routinely for scanning electron microscopic investigation. These samples were observed under Jeol JSM scanning electron microscope (SEM).

Malondialdehyde and Glutathione Assays: Tissue samples were homogenized with ice-cold trichloroacetic acid (1 g tissue plus 10 ml 10% TCA) in an Ultra Turrax tissue homogenizer. The MDA levels were assayed for products of lipid peroxidation by monitoring thiobarbituric acid reactive substance formation as described previously¹⁹. Lipid peroxidation was expressed in



terms of MDA equivalents using an extinction coefficient of $1.56 \times 10^5 \text{ M}^{-1} \text{ cm}^{-1}$ and results are expressed as nmol MDA/g tissue. Glutathione was determined by a spectrophotometric method based on the use of Ellman's reagent²⁰. Briefly, after centrifugation at 3000 rev./min for 10 min, 0.5 ml of supernatant was added to 2 ml of 0.3 mol/l $\text{Na}_2\text{HPO}_4 \cdot 2\text{H}_2\text{O}$ solution. A 0.2 ml solution of dithiobisnitrobenzoate (0.4 mg/ml 1% sodium citrate) was added and the absorbance at 412 nm was measured immediately after mixing. Glutathione levels were calculated using an extinction coefficient of $13600 \text{ M}^{-1} \text{ cm}^{-1}$. Results are expressed in mol GSH/g tissue.

Mast Cell Counts: Paraffine sections stained with toluidine blue were used for both granulated and degranulated mast cell counting. Ten areas in each sample were selected and mast cells containing metachromatic granules were counted separately at 400x magnification in the mucosa by one or more observers and the observers were blind to the group from which each sample was obtained. An eye-piece graticule (0.0785 mm^2) was used in order to avoid overlapping of counting areas. Areas selected in each region were surveyed for mast cells and the mast cell density was then expressed as cell number per unit area.

Statistical analysis: Statistical analysis was carried out using GraphPad Prism 3.0 (GraphPad Software, San Diego, CA; USA). All data were expressed as means \pm SEM. Groups of MDA and GSH data were compared with an analysis of variance (ANOVA) followed by Tukey's multiple comparison tests. Mann Whitney U nonparametric test was used to evaluate mast cells. Values of $p < 0.05$ were regarded as significant.

RESULTS

In the control group, normal mucosa and overlying mucus layer (Fig. 1a), a small number of mast cells (Fig. 1b) was observed in the bladder wall at the light microscopy level. Regular mucosal topography (Fig. 1c) was observed at SEM level.

In the PS group, loss of urothelial cells, focal decrease of the cell layer of urothelium and irregularity of mucus layer, severe inflammatory cell infiltration (Fig. 2a) and increased number of both granulated and degranulated mast cells (Fig. 2b) were observed with the light microscope. Detachment and loss of urothelial cells and local ulcerated areas were the dominant features at SEM level (Fig. 2c).

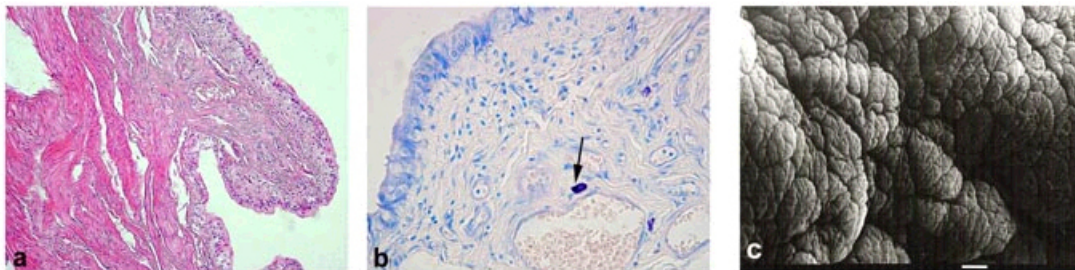


Fig 1: Control group: a) Urothelial mucosa with regular mucus layer and epithelial cells H-E X 200. b) A small number of mast cells (->) in mucosa, toluidine blue staining, X400. c) Luminal surface of the bladder with mucosal folding, mucous covered areas and polygonal shaped apical cells (*), scale bar: 10µm.

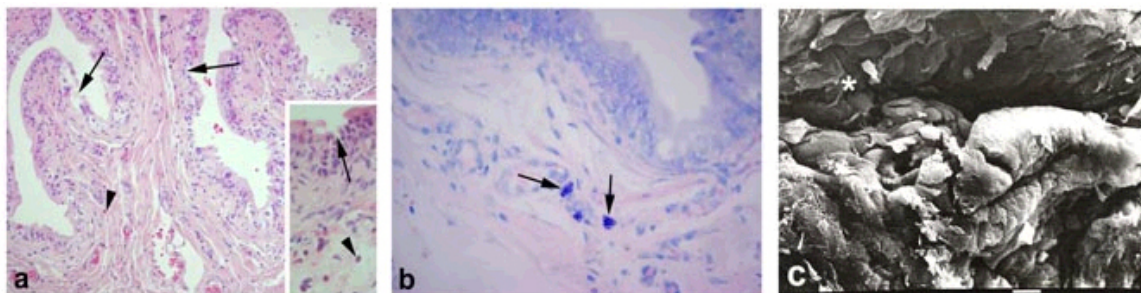


Fig 2: PS group: a) Degeneration of the urothelial layer and local ulceration areas (->) with severe accumulation of neutrophils (>), H-E staining, X 200, inset X400. b) Increased number of mast cells, in mucosa, toluidine blue staining, X400. c) Ulcerations in most of the urothelium with mucus and epithelial cell loss (*), scale bar: 10µm.



In the PS + MESNA group, the urothelium retained its integrity. A decrease in the density of inflammatory (Fig. 3a) and mast cell (Fig. 3b) population was evident when compared to the PS group at light microscopic level. SEM observations showed regeneration of luminal mucosa (Fig. 3c) but local degenerated sites were still present.

The number of granulated and degranulated mast cells per square millimeter in the mucosa of bladder stained with toluidine blue was counted. According to the statistical analysis there was a significant increase in both the granulated ($p < 0.01$) and degranulated ($p < 0.01$) mast cell number in the protamine sulfate group when compared with the control and protamine sulfate plus MESNA group. MESNA treatment reduced

the number of both granulated and degranulated mast cell in mucosa of PS- induced urinary bladder (Fig. 4).

Protamine sulfate induction caused a prominent increase in MDA levels (22.5 ± 2.1 nmol/g) an end product of lipid peroxidation, compared to the control group (11.3 ± 1.2 nmol/g, $p < 0.01$). Bladder tissues in the PS + MESNA group responded to MESNA treatment with a decrease in MDA levels (11.9 ± 1.2 nmol/g, $p < 0.01$, Fig. 5a) and this response was statistically significant ($p < 0.01$). The decrease in bladder GSH levels in the protamine sulfate group (0.51 ± 0.1 μ mol/g) was also significant when compared to the control group (1.7 ± 0.3 μ mol/g, $p < 0.01$) and increased by MESNA treatment (1.6 ± 0.1 μ mol/g, $p < 0.05$, Fig. 5b).

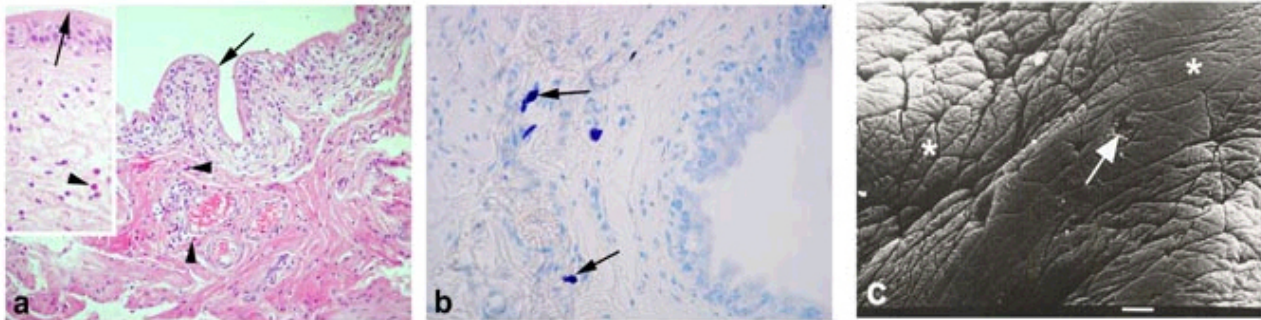


Fig 3: PS + MESNA group: a) Regeneration of urothelium (->) in most areas and decrease in number of inflammatory cells (>) in mucosa, H-E staining, X 200, inset X400. b) Decreased number of mast cells in mucosa, toluidine blue staining, X400. c) Healing of the urothelial mucosa (*) and mucus layer, scale bar: 10µm.

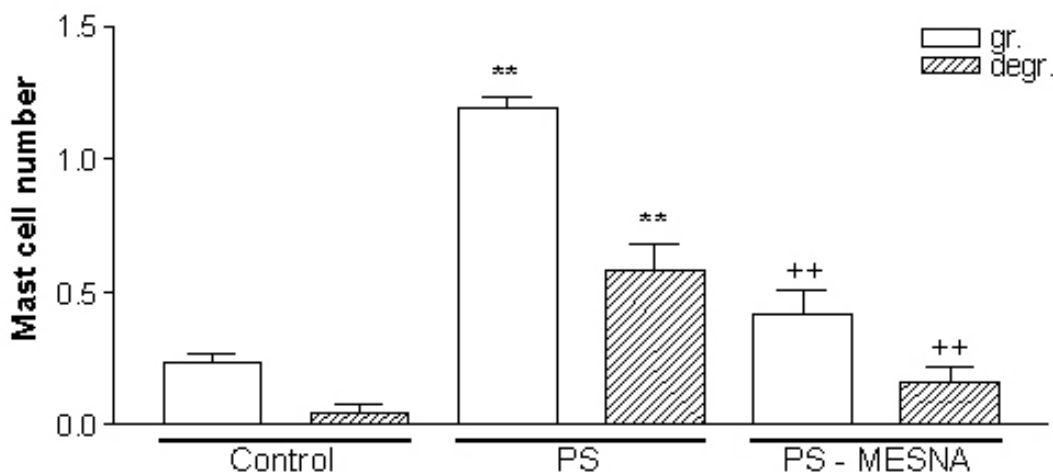


Fig 4: Number of mast cells per 0.0789 mm² in control, PS and PS+MESNA groups. ** $p < 0.01$: compared to control group; ++ $p < 0.01$ compared to PS group.

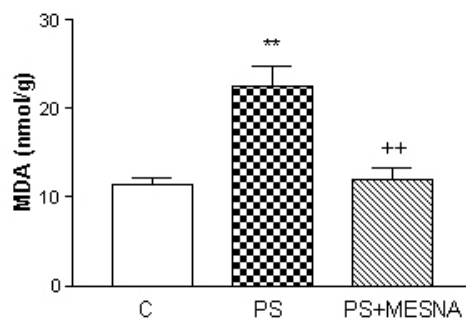


Fig. 5a

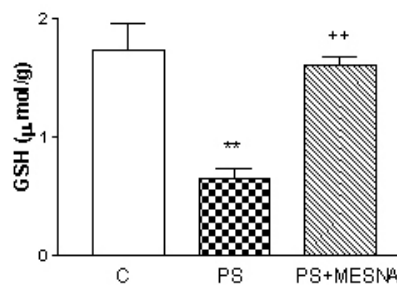


Fig.5b

Fig 5: Urinary bladder a) malondialdehyde (MDA) and b) glutathione (GSH) levels of the control, protamine sulphate (PS), and MESNA-treated-PS (PS+MESNA) groups. ** $p < 0.01$ compared to control; ++ $p < 0.01$ compared to PS group.

DISCUSSION

The results of the present study demonstrate that MESNA has protective effects on PS-induced urinary bladder damage. The degenerative morphological and biochemical changes of the urinary bladder are reversed by MESNA treatment. As the oxidative injury on cellular structures is reduced by MESNA, intracellular antioxidant GSH, which is otherwise oxidized during the process of inactivating free radicals, is not changed.

Bladder urothelium integrity relies primarily on its surface glycosaminoglycans (GAG) and the structure of cell-cell contacts to maintain its permeability²¹. Sulfated polysaccharides have a higher affinity for quaternary amines than for water on the bladder surface and they inactivate native bladder polysaccharide²¹. Experimental studies showed that when the electron negative surface polysaccharide is neutralized by the polycation of PS, the epithelium leaks urea, calcium, and water²². These deleterious effects of PS were reversed by subsequent intravesical treatment of GAG (heparin)²³. Many studies have shown that protamine increases the permeability of different types of epithelium^{24,25}. Generally defects or any changes in the GAG layer of the urothelium have an initiating role in interstitial cystitis²¹. In the current study we observed focal loss of the urothelial layer, and loss and irregularity of the GAG layer in most areas, similar to the study of Parsons et al.^{24,22}. Scanning electron microscopy observations in patients with IC showed a decrease in the mucous layer, degeneration of cell junctions and increase in the number of microvilli²⁵. Our light and scanning electron microscopy observations on PS

administration showed a decrease in the mucous layer, dilatation of the superficial cells and ulcerated areas at the apical surface.

It has been shown that MESNA is rapidly oxidized to the MESNA disulfide form (DIMESNA) in plasma, and DIMESNA is then reduced to MESNA, an active thiol form, by cytosolic enzymes in renal tubular epithelia. When MESNA is administered at high doses, the autooxidation process will be saturated and a higher plasma concentration of free MESNA will be presented to the renal tubules. Following absorption by the tubular cells, this substance will supply free thiol groups, which will continue the detoxification of toxic oxygen metabolites²⁶. Thus, the protective effect of MESNA on the urinary bladder, as observed in the present study, may be attributed to its thiol-supplying action. In an in vitro study, it was shown that hyperthermia-induced cytotoxicity in Chinese hamster ovary cells was reduced and intracellular glutathione levels were increased by MESNA pretreatment²⁷. MESNA is primarily used as a chemoprotector agent to reduce hemorrhagic cystitis induced by oxazaphosphorine (e.g. cyclophosphamide and ifosfamide)²⁸. Methotrexate-induced cytotoxicity was also limited with MESNA by inhibiting excessive hydrogen peroxide production during chemotherapy¹¹.

Lipid peroxidation, mediated by free oxygen radicals, is believed to be an important cause of destruction and damage to cell membranes, since polyunsaturated fatty acids of the cellular membranes are degraded by this process with consequent disruption of membrane integrity. Membrane peroxidation can lead to changes in membrane fluidity and permeability and also to



enhanced rates of protein degradation, and these will eventually lead to cell lysis²⁹. In the present study, the level of MDA, an end product of lipid peroxidation, is significantly increased in the PS-induced urinary bladder. Our results demonstrate that MESNA inhibits MDA elevation significantly and reverses it to control levels. Thus MESNA could be protective against PS- induced oxidative urinary bladder damage by preserving the cellular integrity.

Glutathione, a key antioxidant, is an important constituent of intracellular protective mechanisms against various noxious stimuli, including oxidative stress. On the other hand, reduced glutathione, which constitutes the main component of endogenous non-protein sulfhydryl pool, is known to be a major low molecular weight scavenger of free radicals in the cytoplasm³⁰. These data are in accordance with the findings of a recent study which demonstrated that MESNA treatment caused marked reductions in tissue lipid peroxidation levels and normalized glutathione activities in ischemia-reperfusion induced renal damage³¹ and cyclophosphamide and ifosfamide-induced urinary bladder damage³².

Observations suggest that ROMs play a role in the recruitment of neutrophils into postischemic tissue, but activated neutrophils are also a potential source of ROMs^{33,34}. In this study, as expected, PS induction caused a neutrophil infiltration and mast cell activation and furthermore this increased infiltration and activation was inhibited by MESNA treatment. This might also result in reduced lipid peroxidation and thus, less accumulation of MDA, since activation of neutrophils might lead to the generation of more oxygen reactive metabolites.

Mast cell recruitment is the result of the inflammation present in the inflamed bladder tissue³⁵. Besides the inflammatory cells mast cells contribute the inflammation via the agents in their granules such as histamine, heparin, tyrtase, etc. This study showed PS induction leads to an increase in both granulated and degranulated mast cells. In the MESNA treated group after PS induction, there is a reduction in both granulated and degranulated mast cells which points that MESNA reducing the inflammation via the inhibition of lipid peroxidation also leads to a reduction in the number of both granulated and degranulated mast cells.

In conclusion, in view of previous observations and our data, with potent free radical scavenger and antioxidant properties, MESNA seems to be a promising agent for protecting tissues from oxidative damage and preventing organ dysfunction due to PS induction and can be used as a therapeutic agent in inflammatory urinary bladder diseases such as interstitial cystitis.

REFERENCES

1. Horrow JC. Protamine a review of its toxicity. *Anesth Analg* 1985;64:348-361.
2. Peterson MW, Gruenhaupt D. Protamine interaction with the epithelial cell surface. *J Appl Physiol* 1992;72: 236-241.
3. Quinton PM, Philpott CW. A role for anionic sites in epithelial architecture. *J Cell Biol* 1973;56:787-796.
4. Tzan CJ, Berg J, Lewis SA. Effect of protamine sulfate on the permeability properties of the mammalian bladder. *J Membrane Biol* 1993;133:227-242.
5. Niku DS, Stein PC, Scherz HC, Parsons CL. A new method for cytodestruction of bladder epithelium using protamine sulfate and urea. *J Urol* 1994;152:1025-1028.
6. Johansson SL, Fall M. Pathology of interstitial cystitis. *Urol Clin North Am* 1994; 21: 55-62.
7. Fall M, Johansson SL, Vahlne A. A clinicopathological and virological study of interstitial cystitis. *J Urol* 1985;133:771-773.
8. Sant GR. Diagnosis of interstitial cystitis. A clinical, endoscopic and pathologic approach. In: Hanno PM, Staskan DR, Krane RJ, Wein AJ. *Interstitial Cystitis*. London.: Springer. 1990: 107.
9. Fowler JE, Jr Lynes WL, Lau JLT, Ghosh L, Mounzer A. Interstitial cystitis is associated with intraurethelial Tamm-Horsfall protein. *J Urol* 1988;140:1385-1389.
10. Gillenwater JY, Wein AJ. Summary of the National Institute of Arthritis, Diabetes, Digestive and Kidney Diseases Workshop on Interstitial Cystitis, National Institutes of Health, Bethesda, Maryland, August 28-29, 1987. *J Urol* 1988;140 :203-206.
11. Gressier B, Lebegue S, Brunet C, et al: Pro-oxidant properties of methotrexate: evaluation and prevention by anti-oxidant drug. *Pharmazie* 1994;49:679-681.
12. Gressier B, Lebegue N, Brunet C, et al. Scavenging of reactive oxygen species by letosteine, a molecule with two blocked-SH groups. omparison with free -SH drugs. *Pharm World Sci* 1995;17:76-80.
13. Goren MP, McKenna LM, Goodman TL. Combined intravenous and oral mesna in outpatients treated with ifosfamide. *Cancer Chemother Pharmacol* 2003; 40:371-375.
14. Kurovski V, Wagner T. Urinary excretion of ifosfamide, 4-hydroxyfosfamide, 3- and 2-dechloroethylifosfamide, mesna, and dimesna in patients on fractionated intravenous ifosfamide and concomitant mesna therapy. *Cancer Chemother Pharmacol* 1997;39:431-439.
15. Berrigan MJ, Marinello AJ, Pavelic Z, Williams CJ, Struck RF, Gurtoo HL. Protective role of thiols in cyclophosphamide-induced urotoxicity and depression of hepatic drug metabolism. *Cancer Res* 1982;42:3688-3695.



16. West NJ. Prevention and treatment of hemorrhagic cystitis. *Pharmacother* 1997; 17:696–706.
17. Nishikawa A, Morse MA, Chung FL. Inhibitory effects of 2-mercaptoethane sulfonate and 6-phenylhexyl isothiocyanate on urinary bladder tumorigenesis in rats induced by N-butyl-N-(4-hydroxybutyl) nitrosamine. *Cancer Lett* 2003;193:11–16.
18. Umemura T, Hasegawa R, Sai-Kato K, et al. Prevention by 2-mercaptoethane sulfonate and N-acetylcysteine of renal oxidative damage in rats treated with ferric nitrilotriacetate. *Jpn J Cancer Res* 1996;87:882–886.
19. Beuge JA, Aust SD. Microsomal lipid peroxidation. *Method Enzymol* 1978;52:302–311.
20. Beutler E. Glutathione in red blood cell metabolism. A manual of Biochemical Methods. Published by Grune and Stratton. New York, 1975: 112–114.
21. Lilly JD, Parsons L. Bladder surface glycosaminoglycans. Is a human epithelial permeability barrier?. *Surg. Gynecol Obstet* 1990;171:493-496.
22. Parsons CL, Lilly JD, Stein P. Epithelial dysfunction in nonbacterial cystitis (interstitial cystitis). *J Urol* 1991;145:732-735.
23. Parsons CL, Housley T, Schmidt JD, Lebow D. Treatment of interstitial cystitis with intravesical heparin. *Br J Urol* 1994;73:504-507.
24. Parsons CL, Boychuk D, Jones S, Hurst R, Callahan H. Bladder surface glycosaminoglycans: An epithelial permeability barrier. *J Urol* 1990;143:139-142.
25. Anderström CRK, Fall M, Johansson SL. Scanning electron microscopic findings in interstitial cystitis. *Br J Urol* 1989;63:270-275.
26. Skinner R, Sharkey IM, Pearson ADJ, Craft AW. Ifosfamide, mesna, and nephrotoxicity in children. *J Clin Oncol* 1993;11:173–190.
27. Lord-Fontaine S, Averill DA. Enhancement of cytotoxicity of hydrogen peroxide by hyperthermia in Chinese hamster ovary cells: role of antioxidant defenses. *Arch Biochem Biophys* 1999;363:283–295.
28. Souid AK, Fahey RC, Aktas MK, et al. Blood thiols following amifostine and mesna infusions, a pediatric oncology group study. *Drug Metab Dispos* 2001;29:1460–1466.
29. Garcia JJ, Reiter RJ, Guerrero JM, Escames G, Yu BP, Oh CS, Munoz-Hoyos A. Melatonin prevents changes in microsomal membrane fluidity during induced lipid peroxidation. *FEBS Lett* 1997;408:297–300.
30. Ross D. Glutathione, free radicals and chemotherapeutic agents. Mechanisms of free-radical induced toxicity and glutathione-dependent protection. *Pharmacol Ther* 1988;37:231–249.
31. Kabasakal L, Sehirli AO, Cetinel S, Cikler E, Gedik N, Sener G. Mesna (2-mercaptoethane sulfonate) prevents ischemia/reperfusion induced renal oxidative damage in rats. *Life Sci* 2004, Sep 24;75:2329-2340.
32. Vieira MM, Macedo FY, Filho JN, et al.. Ternatin, a flavonoid, prevents cyclophosphamide and ifosfamide-induced hemorrhagic cystitis in rats. *Phytother Res* 2004 Feb;18:135-141.
33. Granger DN, Korthuis RJ. Physiological mechanisms of postischemic tissue injury. *Annu Rev Physiol*. 1995;57:311–332.
34. Zimmerman BJ, Grisham MB, Granger DN: Role of oxidants in ischemia-reperfusion induced granulocyte infiltration. *Am J Physiol* 1990;258:G185–G190.
35. Theoharides TC, Kempuraj D, Sant GR. Mast cell involvement in interstitial cystitis: a review of human and experimental evidence. *Urology* 2001;57 (suppl.6A):47-55.