



## CASE REPORT

### CASTLEMAN DISEASE

Aslı Gül Akgül, Bedrettin Yıldızeli, Mustafa Yüksel

*Department of Thoracic Surgery, School of Medicine, Marmara University, Istanbul, Turkey*

#### ABSTRACT

Castleman disease or giant lymph node hyperplasia, is a rare disorder that is located most commonly in the visceral mediastinum. We report a Castleman disease represented with hilar lymph node hyperplasia. Diagnosis and treatment of this rare disorder is discussed.

**Keywords:** Castleman, Lung, Mediastinal tumor, Surgery

### CASTLEMAN HASTALIĞI

#### ÖZET

Castleman hastalığı ye da dev lenf nodülü hiperplazisi, genellikle viseral mediyasteni tutan nadir bir hastalıktır. Yazımızda hiler lenf hiperplazisi ile prezante olan bir Castleman olgusu sunmaktayız.

**Anahtar Kelimeler:** Castleman, Akciğer, Mediyastinel tümör, Cerrahi

## INTRODUCTION

Castleman disease, which is also referred to as giant lymph node hyperplasia, angiofollicular lymph node hyperplasia, localized nodal hyperplasia, lymph node (lymphoid) hamartoma and benign lymph node lymphoma was first described by Castleman in 1956<sup>1</sup>. It is a rare disorder and can be found wherever lymphoid tissue is present<sup>2,3</sup>, but 71% of the cases are located in the chest, along the tracheobronchial tree in the mediastinum or lung hilus<sup>4,5</sup>. The clinical presentation and course varies, whether patients have the more frequent localized form or the much rarer multicentric form. We report a case of Castleman disease diagnosed by surgery.

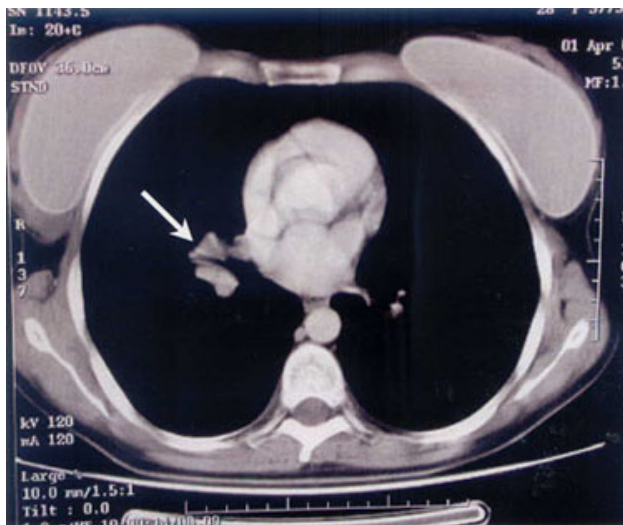
## CASE REPORT

A 28 year-old asymptomatic woman was found to have a hilar enlargement in the right hemithorax on chest x-ray. Her medical history was unremarkable except appendectomy. She was not immunosuppressed, had not under any kind of medical therapy. She had never smoked. Her family history and physical examination were

unremarkable. In her laboratory findings the sedimentation rate was 103 mm/h, Hb: 10 g/dl, ferrum: 31 ug/dl and trombocyte: 450000/ uL. PPD was 13mm and thought as negative. Computed Tomography (CT) of the chest revealed a right hilar lymphadenopathy (Fig. 1) which was a spesific localisation for hilar lymph nodes so was confirmed by radiologists. Fiberoptic bronchoscopy was performed and; a hypervascularised place at the left main bronchial wall was observed and the right middle lobe bronchus was hyperemic and edematous. Biopsy and microbiological examinations of the bronchoalveolar lavage and brush were not pathognomonic. Diagnostic investigations for connective tissue diseases were unremarkable. Ampiric antituberculosis therapy (Rifampicin + Ethambutol + Isoniazide + Morphazinamide) was instituted by pneumologists. As the patient was young and presumptive diagnosis was benign pathology, surgical approach was delayed and response to the medical treatment was followed - up for 8 months. Control CT revealed no change in diameter of the hilar lymphadenopathy.

*Corresponding author: Prof. Mustafa Yüksel, M.D.  
Department of Thoracic Surgery, School of Medicine, Marmara University  
Hospital, Tophanelioğlu Caddesi, No: 14-16 Alyunizade, İstanbul, Turkey  
E-mail: [myuksel@marmara.edu.tr](mailto:myuksel@marmara.edu.tr)  
Tel: (216) 3259133 Fax: (216) 3252426*

*Marmara Medical Journal 2005;18(2);81-83*



**Fig. 1:** Thorax CT: Right hilar lymphadenopathy

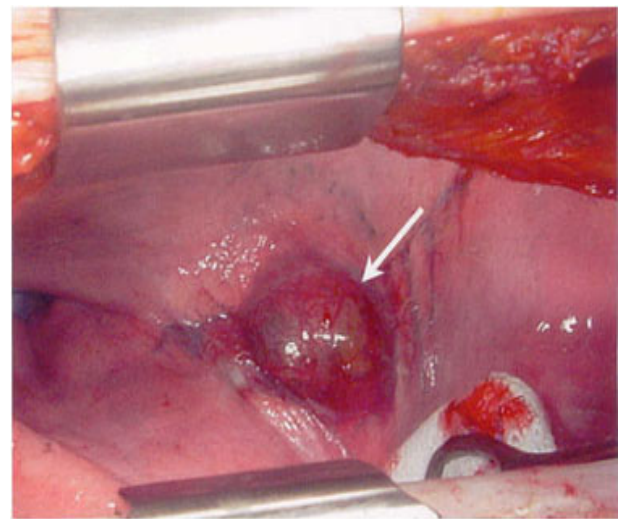
With suspicion of a low grade malignancy surgical biopsy via right posterolateral thoracotomy was performed and the enlarged hilar lymph node was excised (Fig. 2). The pathology of the specimen revealed angiofollicular mediastinal lymph node hyperplasia, 'Castleman Disease', mixed type. Postoperative recovery was uneventful and follow-up examination at 4 months was normal. Sedimentation rate, trombocytes and other cell blood countings were evaluated to be in normal ranges.

## DISCUSSION

Castleman disease is an uncommon, frequently benign, lymphoproliferative disorder-characterized by a peculiar form of lymph node hyperplasia<sup>1</sup> of unknown etiology mostly involving the mediastinum<sup>6,7</sup>.

The differential diagnoses of the hyaline-vascular variety make us to consider other causes of hypervascular adenopathies: Kaposi's sarcoma, hypervascular metastases, etc. The plasma cell subtype should be differentiated from other causes of hypovascular adenopathies (primary or secondary neoplasms, infectious and granulomatous diseases). The most important differential diagnoses include artero-venous malformations, carcinoid, and hemangiopericytomas<sup>8</sup>.

The etiology of Castleman disease remains elusive, although dysregulated overproduction of interleukin-6 (IL-6) is thought to be central to disease progression. The multicentric variant of Castleman disease is associated with human herpes virus 8 in many cases<sup>9-11</sup>. This virus encodes a functional analogue of IL-6, providing



**Fig. 2:** Surgical specimen

further evidence that this cytokine has a pivotal role in the disease<sup>12</sup>.

Males and females are equally affected<sup>7</sup>. Symptoms are apparently due to tracheobronchial compression. 25% to 48% of the tumors being found incidentally as in our case. Less than half of the patients have constitutional symptoms, which may include fever, malaise, weight loss and failure to thrive and in rare instances, amenorrhea, diarrhea, cough, dyspnea, chest pain, back pain and respiratory infection<sup>10</sup>.

The disease may vary from a localized mass to a systemic disorder with widespread lymphadenopathy, fevers, recurring infections, and autoimmune manifestations. It can affect any part of the body that contains lymphoid tissue, although 70% of cases are intrathoracic<sup>12</sup>.

Laboratory findings may include also elevation in levels of macrophage colony stimulating factor, TNF beta, gamma interferon, erythrocyte sedimentation rate, and C-reactive protein. The patient may also have anemia, hypergammaglobulinemia, hypoalbuminemia, leukocytosis, or leukopenia and thrombocytosis or thrombocytopenia<sup>9,10</sup>. Our patient had anemia, high sedimentation rate and trombocytosis.

Magnetic Resonans Imaging (MRI) findings are nonspecific. However, CT demonstrates the macroscopic appearance of the lesions better: well-margined nodule with strong contrast enhancement in local form; thickening of peribronchovascular interstitium and centrilobular nodules in diffuse involvement<sup>13</sup>. Currently the role of Positron- Emission Tomography (PET) scan in diagnosis of Castleman disease is unknown.



Tissue diagnosis is mandatory to avoid mismanagement: needle biopsy has low diagnostic accuracy and thoracoscopic biopsy is dangerous because of the high vascularization of the tumor increasing risk of bleeding<sup>14</sup>. Although recent literature has shown that the thoracoscopic resection of Castleman disease is possible<sup>4</sup>, open surgery is preferred<sup>5</sup>.

Surgical removal managed with care to avoid immediate or perioperative bleeding is probably the best diagnostic and also curative procedure: symptoms disappear after surgery. Radical excision is mandatory but often the tumour is not easily removed from the underlying tissues: some subtotal excision had been performed without short-term recurrences reported<sup>13</sup>. If the tumor is not resectable, as in the multicentric form, or if there is incomplete regression of clinical symptoms, the treatment is not well defined. In such circumstances, prednisone alone or in combination with other immunosuppressive agents such as methotrexate, intravenous immunoglobulins, interferon, or plasmapheresis have been used<sup>10,15</sup>. Radiation therapy has been used with mixed success in patients who are poor surgical candidates or in those with unresectable lesions<sup>1,14-16</sup>. Other treatments include retinoic acid, humanized anti IL-6 receptor antibodies<sup>9,17</sup> and bone marrow transplantation<sup>16</sup>. Since we performed a complete resection in our case, no additional treatment was needed.

Castleman disease, albeit uncommon, should be included in the differential diagnosis of mediastinal tumors and surgical removal is probably the best diagnostic and also curative procedure: symptoms disappear after surgery.

## REFERENCES

1. Castleman B, Iverson L, Menendez VP. Localized mediastinal lymph node hyperplasia resembling thymoma. *Cancer* 1956;9:822-830.
2. Irsutti M, Paul JL, Selves J, Railhac JJ. Castleman disease: CT and MR imaging features of a retroperitoneal location in association with paraneoplastic pemphigus. *Eur Radiol* 1999;9:1219-1221.
3. Poyanly A, Genç FA, Sencer S, Yanar H, Kapran Y. Cervical Castleman's disease: imaging findings. A case report. *Eur Radiol* 2000;10:1190-1192.
4. Seirafi PA, Ferguson E, Edwards FH. Thoracoscopic resection of Castleman Disease. *Chest* 2003;123:280-282.
5. Rena O, Casadio C, Maggi G. Castleman's disease: unusual intrathoracic localization. *Eur J Cardiothorac Surg* 2001;19:519-521.
6. Ferrozzi F, Tognini G, Spaggiari E, Pavone P. Focal Castleman disease of the lung MRI findings. *J Clin Imaging* 2001;25:400-402.
7. Johkoh T, Müller NL, Ichikado K, et al. Intrathoracic multicentric Castleman's disease: CT findings in 12 patients. *Radiology* 1998;209:47-81
8. Spedini C, Lombardi C, Lanzani G, Di Fabio D, Chiodera PL. Castleman's Disease presenting as an asymptomatic solitary pulmonary nodule. *Monaldi Arch Chest Dis* 1995;50:363-365.
9. Nishimoto N, Sasai M, Shima Y, et al. Improvement in Castleman's disease by humanized anti-interleukin-6 receptor antibody therapy. *Blood* 2000;95:56-61
10. Perez N, Bader-Meunier B, Roy CC, et al. Pediatric Castleman Disease: Report of seven cases and review of literature. *Eur J Pediatr* 1999;158:631-663.
11. Soulier J, Grollet L, Oksenhendler E, et al. Kaposi's sarcoma-associated herpes virus-like DNA sequences in multicentric Castleman's disease. *Blood* 1995;86:1276-1280.
12. Wilkinson S, Forrester-Wood CF. Surgical resection of a solitary plasmacytoma originating in a rib of a patient with Castleman's Disease. *Ann Thorac Surg* 2003;75:1018-1019.
13. Reynolds SP, Gibbs AR, Weeks R, Adams H, Davies BH. Massive pleural effusion: an unusual presentation of Castleman's disease. *Eur Respir J* 1992;5:1150-1153.
14. Chronowski GM, Ha CS, Wilder RB, Cabanillas F, Manning J, Cox JD. Treatment of unicentric and multicentric Castleman disease and the role of radiotherapy. *Cancer* 2001;92:670-676.
15. Repetto L, Jaiprakash MP, Selby PJ, Gusterson BA, Williams HJ, McElwain TJ. Aggressive angiofollicular lymph node hyperplasia (Castleman's disease) treated with high dose melphalan and autologous bone marrow transplantation. *Hematol Oncol* 1986;4:213-217.
16. Beck JT, Hsu SM, Wijdenes J, et al. Brief report: alleviation of systemic manifestations of Castleman's disease by monoclonal anti-interleukin-6 antibody. *N Engl Med* 1994;330:602-605.
17. Barrie JR, English JC, Muller N. Castleman's disease of the lung: radiographic, high resolution CT and pathologic findings. *AJR, Am J Roentgenol* 1996;166:1055-1056.