

Plate osteosynthesis for proximal humerus fractures through a deltoid-split approach under traction in lateral decubitus position: preliminary results

 Ahmet Emin Okutan

Samsun University, Faculty of Medicine, Department of Orthopaedic Surgery, Samsun, Turkey

Cite this article as: Okutan AE. Plate osteosynthesis for proximal humerus fractures through a deltoid-split approach under traction in lateral decubitus position: preliminary results. J Health Sci Med 2022; 5(6): 1747-1751.

ABSTRACT

Aim: We aimed to present deltoid split approach under traction in lateral decubitus position that we perform for the treatment of proximal humerus fractures (PHFs) and to present the preliminary surgical and clinical outcomes of our patients.

Material and Method: Twelve patients who underwent plate osteosynthesis through a deltoid split approach under traction in lateral decubitus position between May 2019 and January 2021 were evaluated. Patient demographics, Neer classification, and time from injury to surgery were collected in all patients preoperatively. Radiation exposure time and operating time was recorded intraoperatively. Radiological outcomes were assessed, including time to union, and neck-shaft angle. Functional outcomes were evaluated using the Constant score at the minimum 12-month follow-up.

Results: Twelve patients (5 male, 7 female) were evaluated with a mean age 58.6 ± 10.7 years (range, 32 to 72 years) at the time of surgery. The mean follow-up period was 117.4 ± 3.8 months. The mean operation time was 60.7 ± 15.2 min (range, 44 to 92 min). The mean radiation exposure time was 6.1 ± 3.0 s (range, 3.3 to 14.2 s). Fracture union was observed in all patients at mean 14.6 ± 2.5 weeks (range, 8 to 20 weeks). The mean neck-shaft angle after the union was 134.5 ± 3.4 degrees (range, 124 to 143 degrees). The mean Constant score was at the final follow-up was 76.4 ± 8.7 (range, 63 to 90).

Conclusion: Patient positioning in the lateral decubitus position under traction can be considered as a safe, reliable, and reproducible method in selected patients with PHFs.

Keywords: Proximal humerus fracture, fixation, traction, lateral decubitus

INTRODUCTION

The management of the proximal humeral fractures (PHFs) remains a technical challenge to internal fixation, based on complex fracture configuration, appropriate approach selection, and anatomical reduction (1-3). However, the potential effect of patient positioning on surgical outcomes has not been evaluated. The effect of a traction table that can provide or improve reduction is indisputable for the proximal femur fractures (4). Why should not this also be considered for the PHFs?

Although there continues to be controversy regarding the optimal treatment of PHFs, anatomical reduction is an essential for the fixation of the PHFs (5,6). The purpose of this study was to describe a lateral decubitus position under traction that led to facilitate anatomical reduction in the treatment of the PHFs and to present the preliminary surgical and clinical outcomes. We hypothesize that this position will provide better anatomical reduction

and would shorten the operating time compared with previously reported literature.

MATERIAL AND METHOD

This retrospective study was carried out with the permission of the Ondokuz Mayıs University Clinical Researches Ethics Committee (Date: 18.05.2022, Decision No: 2022/240). All procedures were carried out in accordance with the ethical rules and the principles of the Declaration of Helsinki.

Patients who underwent internal fixation of a proximal humerus fracture between 2019 and 2021 were identified. A total of 12 patients who underwent plate osteosynthesis through a deltoid split approach under traction in lateral decubitus position were included in this study. All patients had Neer type two-, three- or four-part PHFs (7). Time from injury to surgery, radiation exposure time, operation time, union rate, time to union, neck-shaft angle and Constant score were extracted in all patients retrospectively and the data set was created.

Surgical Technique

All patients were placed in a lateral decubitus position under general anesthesia. To keep the patient in a stable position, ventral and dorsal supports were used. To avoid pressure injuries, all bony points were padded. The operative extremity is wrapped in an elastic bandage with care being taken not to compress the hand to avoid any neurovascular complications. Then, the involved upper extremity was secured at 30 degrees of abduction and axial traction was performed with 3 kg hanging from the forearm to saline stand via a pulley. The C-arm was positioned medially and laterally to achieve the projection of the involved shoulder (Figure 1). The shoulder was draped in a sterile manner.

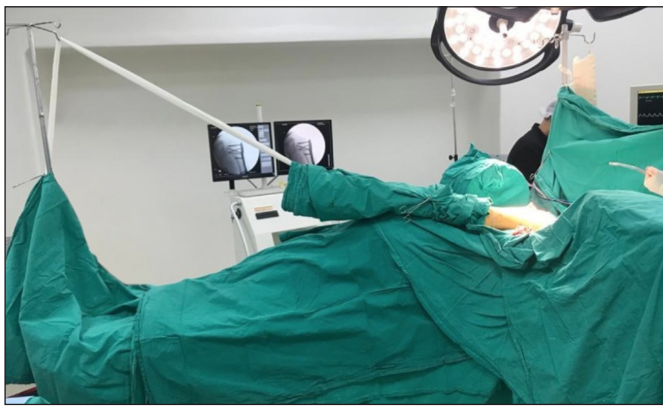

Figure 1. The operative arm is placed into the traction device and traction is applied with a 3 kg. Intraoperative view of patient positioning.

A fluoroscopy control was performed before the incision and an acceptable reduction due to traction was observed in most cases. Then, bony landmarks and the location of axillary nerve were marked with a surgical pen. A skin incision of 6-8 cm was made on the anterolateral aspect of the shoulder. The deltoid muscle was split, and the neurovascular bundle was identified by digital palpation. The distance from the axillary nerve to the tip of the acromion varies from 5 to 7 cm. Two windows were created proximal and distal to the axillary nerve. The proximal window was used for reduction. Traction sutures were placed in tuberosity fragments. Humeral head was reduced with use of a blunt dissector and

calcar continuity was ensured under fluoroscopy control (Figure 2). The sagittal alignment was also directly provided by the traction effect. A proximal humerus internal locking plate was meticulously placed under neurovascular bundle after provisional reduction of the fracture. The plate position was confirmed, and a cortical screw was inserted into the shaft through the oval hole. Then, the locking screws were placed into the superior holes and the distal shaft holes of plate, respectively. Finally, the calcar screws were inserted via proximal and distal mobilization of the axillary nerve and fluoroscopy control was performed (Figure 3). Then, the traction sutures were passed and knotted through the side holes of the plate. The deltoid muscle fibers were approximated, and the wound was closed.

Postoperative Follow-up

All patients wore a shoulder sling in 30 degree of abduction for six weeks. Active elbow and wrist motion were encouraged immediately after surgery. Active-assisted shoulder range of motion (ROM) exercises were started at four weeks. Active ROM, strengthening and weight bearing were permitted gradually at six to eight weeks postoperatively when bone healing was seen.

RESULTS

Twelve patients (5 male, 7 female) were evaluated with a mean age 58.6±10.7 years (range, 32 to 72 years) at the time of surgery. The mean follow-up period was 17.4±3.8 months (range 12 to 24 months). Detailed patient demographics are shown in Table 1.

Table 1. Patient demographics	
Characteristic	Data
Number of Patients	12
Age, yr, mean±SD (Range)	55.4±10.4 (32-69)
Sex, M/F, n	5/7
Side, R/L, n	6/6
BMI, kg/m2, mean±SD (Range)	29.1±3.4 (22.5-37.3)
Time from injury to surgery, d, mean±SD (Range)	1.2±0.4 (0-2)
Follow-up time, mo, mean±SD (Range)	19.2±5.2 (12-28)

BMI: body mass index; F: female; M: male; L: left; R: right; SD: standard deviation

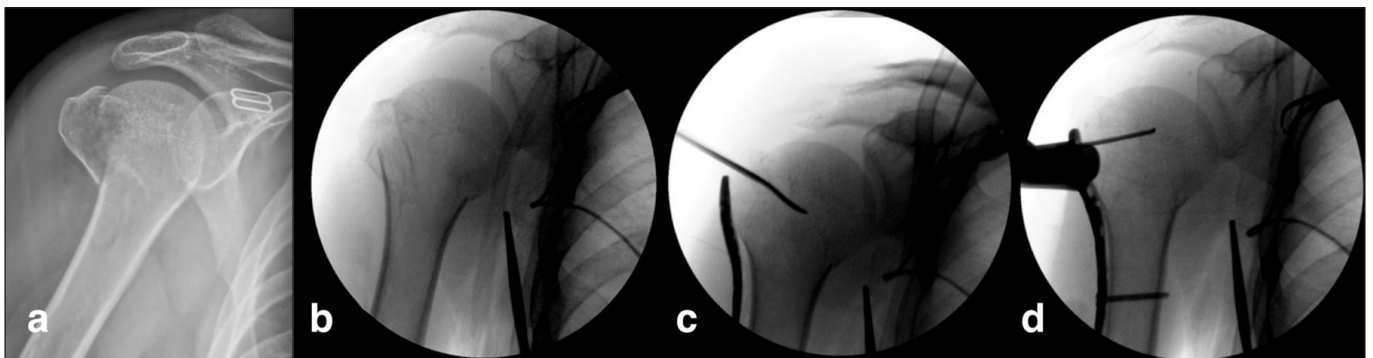


Figure 2. Patient with Neer type III proximal humerus fracture a pre-operative X-ray (a), intra-operative fluoroscopy views, preliminary reduction under traction (b), a proximal humerus plate is inserted, then calcar continuity provided by elevator (c), one cortical screw is placed distally and locking screws are placed into head (d).

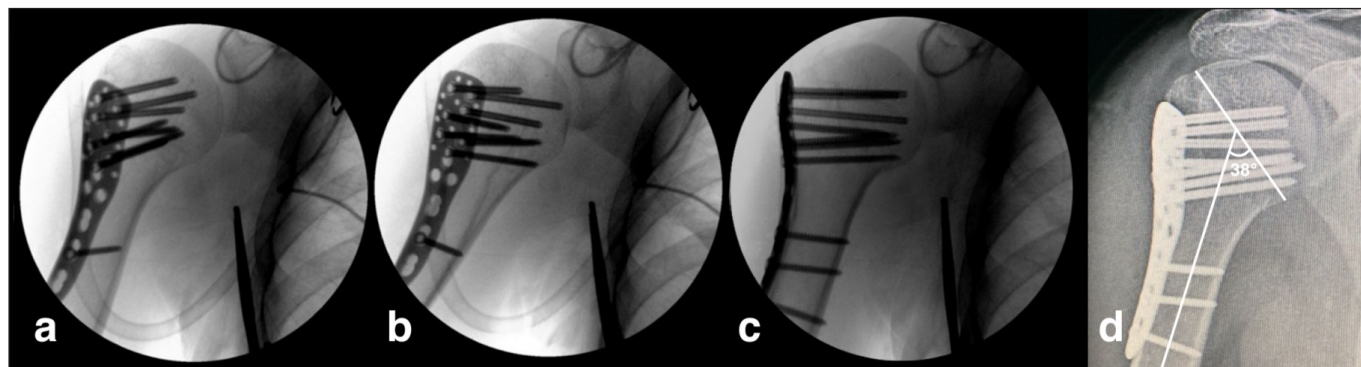


Figure 3. Internally (a), externally (b) and neutral (c) rotation fluoroscopy views of proximal humerus end of the operation. 1- year postoperatively radiograph is shown with 142 degrees of neck-shaft angle (d).

The mean operation time was 60.7 ± 15.2 min (range, 44 to 92 min). Patient positioning and setting up for fluoroscopy were not recorded in the operation time. The mean radiation exposure time was 6.1 ± 3.0 s (range, 3.3 to 14.2 s). Fracture union was observed in all patients at mean 14.6 ± 2.5 weeks (range, 8 to 20 weeks). The mean neck-shaft angle after the union was 134.5 ± 3.4 (range, 124° to 143°). All patients were showed good to excellent clinical outcomes. Mean range of motions was 74.1° (range, 50° to 90°) for abduction, 65.8° (range, 40° to 90°) for external rotation at 90 degrees of abduction, and 118.3° (range, 70° to 160°) for forward flexion at one year postoperatively. The mean Constant score was at the final follow-up was 76.4 ± 8.7 (range, 63 to 90). Outcomes of patients are shown in **Table 2**.

Complications developed in 2 patients. Screw cut-out was seen in patient 2 at 6 months after surgery, without loss of alignment and collapse. Only involved screw was removed. In patient 12, avascular necrosis developed and conversion to reverse shoulder arthroplasty was performed. Other complications including deep or superficial infection, axillary nerve damage or traction related complications were not observed in any of remaining patients.

DISCUSSION

In this study, we describe a new patient positioning technique for the proximal humerus fractures. The lateral decubitus position under traction is a safe and effective method with satisfactory clinical and radiological results.

The importance of anatomical reduction after PHFs have been emphasized in recent studies (5). Bouliane et al. (8) reported that patients achieving simultaneous shaft impaction, shaft medialization, calcar reduction, and neutral neck-shaft angle would be less likely to lose reduction even if the absence of the calcar screw. Dheenadhayalan et al. (6) described the radiographic signs of poor outcomes in PHFs as a terrible triad: neck-shaft angle less than 120 degrees, superior displacement of tuberculum majus, and medial gap of more than 4 mm. Hence, the success or failure of PHFs is deeply rooted in the anatomical reduction quality. If the inherently bone to bone stable fracture configuration does not achieve, the fixation points weaken over time and fixation failure may occur. Therefore, we aimed to improve the reduction quality using a traction in lateral decubitus position. Benefits of this technique include facilitating the anatomical reduction, providing the sagittal alignment directly, eliminating the need for manual reduction

Table 2. Surgical, radiological and clinical outcomes of patients at one year postoperatively

Case	Age/sex	Neer type	Operation time (min)	Radiation exposure time (s)	Union time (wk)	Neck shaft angle ($^\circ$)	Range of motions ($^\circ$)			Constant score	Follow-up time (mo)	Complications
							Abduction	External rotation	Forward flexion			
1	54/M	4-part	75	9,1	16	132	60	60	140	70	24	None
2	63/F	3-part	46	4,5	16	136	70	50	130	68	22	Screw Cut-out (Screw Removed)
3	32/F	2-part	55	5,6	12	130	90	70	150	90	22	None
4	69/M	3-part	62	7,1	20	135	60	50	90	63	20	None
5	58/M	4-part	92	14,2	12	124	70	60	100	68	18	None
6	60/F	3-part	58	4,5	8	138	80	80	140	72	17	None
7	55/F	3-part	50	3,8	16	142	90	90	160	82	17	None
8	63/F	4-part	82	6,4	20	136	70	70	120	76	16	None
9	48/F	3-part	45	5,8	12	140	90	70	150	88	14	None
10	72/M	2-part	62	4,1	16	134	90	70	70	86	14	None
11	62/M	3-part	58	4,7	16	139	70	80	100	74	13	None
12	68/F	2-part	44	3,3	12	143	50	40	70	80	12	Avascular necrosis (Converted to RTSA)

RTSA: reverse total shoulder arthroplasty

maneuvers, performing the procedure either alone or with only one assistant. Calcar continuity was achieved in all patients and the mean neck-shaft angle after the union was observed 134.5 ± 3.4 degrees in the present study.

The optimal surgical access for the PHFs is another relevant controversy of the current literature (9-13). The commonly used approach is the classic deltopectoral approach. This method is safe and well known, and this can be extended without risk to the damage of the axillary nerve; however, it limits posterior visualization, especially in presence of displaced greater tuberosity fracture (9). Conversely, the deltoid-split approach provides a direct visualization of the plating zone with minimal soft tissue dissection (14). However, the iatrogenic injury to the axillary nerve is remains a concern (15). Previous studies showed that both deltopectoral and deltoid-split approaches had similar functional results (10,16). On the other hand, Xie et al. (10) reported that the deltoid split approach resulted in a shorter operation time than the deltopectoral approach in their meta-analysis.

Shortening the operating time and avoiding the radiation-related complications are essential but are not the goal of surgery. While there is no limit to operating time or radiation exposure time, these times should be as low as reasonably achievable (17). Many studies reported that the deltoid split approach resulted in a shorter operating time than the deltopectoral approach. (10) On the other hand, the deltopectoral approach had advantage of less radiation exposure time (16). According to the outcomes of the present study, the operating time and the radiation exposure time in our technique are better than both deltoid-split and deltopectoral techniques in supine or beech chair positions when compared with previous studies (Table 3) (16,18). The mean operating time was 60.7 ± 15.2 min, and the mean

radiation exposure time was 6.1 ± 3.0 s in the present study.

Several studies examined the effects of shoulder movements on axillary nerve position. Cheung et al. (19) reported the shoulder abduction has to greatest effect on the distance of the axillary nerve to acromion. They recommended splitting the deltoid no more than 5 cm distal to the acromion in order to prevent the axillary nerve damage. Moreover, increasing shoulder abduction would increase the strain of the axillary nerve, and it should be kept in mind during the deltoid-split approach. In our study, the shoulder was secured at 30 degrees of abduction. On the other hand, the effect of the calcar screws on the fracture stability has been emphasized in most studies (20). Furthermore, some authors recommended avoiding calcar screws in terms of the risk of axillary nerve damage (21). However, Shin et al. (22) reported that the modified deltoid split approach with axillary nerve mobilization yielded excellent outcomes. They showed no patients had sensory or motor deficits in the axillary nerve with their technique. Traver et al. (23) also showed that prolonged soft tissue retraction may led to the risk of axillary nerve damage. In the present study, no axillary nerve damage was observed in any of the patients. These results support that the described technique is a successful method in selected patients with PHFs.

Some issues need to be mentioned for the present method. The lateral decubitus positioning technique decreases the working area for the surgeon due to medially and laterally positioning of the C-arm. In addition, the described technique via deltoid-split approach might not be a solution for advanced PHF types such as head splitting or fracture dislocations. However, the deltopectoral approach can also be considered as an alternative option for these cases (24).

Table 3. Recent studies on surgical treatment of proximal humerus fractures

Authors, year	N	Mean age, year	Neer classification (1-/2-/3-/4-part)	Patient position	Approach	Operation time, min, mean \pm SD (range)	Radiation exposure time, s, mean \pm SD (range)	Follow-up month (range)	Constant score	Complications
Buchmann[25], 2021	149	64.84	NA	NA	DP	121.33 \pm 52.5)	191.1	12	NA	15
	49	63.86	NA	NA	MIO-DS	108.02 \pm 43.3	181.4	12	NA	1
Rouleau[9], 2020	41	62	0/21/14/2	NA	DP	96 \pm 34	NA	28 \pm 18	NA	7
	44	63	0/20/20/0	NA	MIO-DS	92 \pm 33	NA	25 \pm 12	NA	12
Borer[14], 2020	23	62	0/7/11/5	Beach-chair	DP	102 (77-115)	NA	62 (43-88)	82	5
	39	67	0/11/23/5	Beach-chair	MIO-DS	85 (75-112)	NA	41 (24-54)	79	5
Wang[18], 2020	51	62.02	0/16/21/12	Beach-chair	DP	62.94 \pm 10.18	4.37 \pm 0.72	16.04	86.49	2
	64	62.09	0/18/30/16	Beach-chair	MIO-DS	82.25 \pm 12.36	7.27 \pm 0.93	16.25	83.75	3
Kim[16], 2019	17	52.6	0/17/0/0	Supine	DP	145.9 (136-154)	1.59 (0.5-2.4)	24	78.4	0
	19	58.7	0/17/0/0	Supine	MIO-DS	109.7 (98-120)	38.5 (32.2-45.7)	24	75.6	0
Zhao[11], 2017	19	63.6	0/7/12/0	Beach-chair	DP	61.4 \pm 7.0	NA	10 (4-24)	86.9	3
	17	64.3	0/8/9/0	Beach-chair	MIO-DS	53.6 \pm 7.3	NA	10 (4-24)	88.8	2
Buecking[13], 2014	60	67	0/15/46	Beach-chair	DP	67 (61-74)	96 (72-120)	12	73	7
	60	69	0/15/46	Beach-chair	MIO-DS	62 (57-67)	120 (96-144)	12	81	8
Acklin[12], 2013	96	62	NA	Beach-chair	MIO-DS	73 \pm 37	108 \pm 121	18 \pm 6	75	15

DP: deltopectoral; MIO-DS: minimally invasive osteosynthesis-deltoid splitting; SD: standard deviation; NA: not available; Complications: Cut-out/ Nonunion/ Fixation Failure/ Avascular Necrosis/ Loss of Reduction/ Nerve Injury

The study has several limitations. The small sample size is a major limitation which might under-covered some of the outcomes. Although we have reported the preliminary results, the larger cohorts would provide more reliable information. In addition, electromyography or nerve conduction tests for objective evaluation were also not performed to analyze axillary nerve condition with more detail. Nevertheless, we believe that our study provides valuable contribution about plate osteosynthesis for PHFs.

CONCLUSION

Patient positioning in the lateral decubitus position under traction can be considered as a safe, reliable, and reproducible method in selected patients with PHFs. It provides good to excellent clinical outcomes in the early period, facilitates the anatomical reduction. However, further prospective comparative studies are needed to make definitive conclusions.

ETHICAL DECLARATIONS

Ethics Committee Approval: The study was carried out with the permission of the Ondokuz Mayıs University Clinical Researches Ethics Committee (Date: 18.05.2022, Decision No: 2022/240).

Informed Consent: All patients signed the free and informed consent form.

Referee Evaluation Process: Externally peer-reviewed.

Conflict of Interest Statement: The author has no conflicts of interest to declare.

Financial Disclosure: The author declared that this study has received no financial support.

Author Contributions: The author declare declare that they have all participated in the design, execution, and analysis of the paper, and that they have approved the final version.

REFERENCES

- Jawa A, Burnikel D. Treatment of proximal humeral fractures: a critical analysis review. *JBJS Rev* 2016; 4.
- Omid R, Trasolini NA, Stone MA, Namdari S. Principles of locking plate fixation of proximal humerus fractures. *J Am Acad Orthop Surg* 2021; 29: e523-e35.
- Buyukkusu MO, Kulduk A, Misir A, Cetinkaya E, Camurcu IY, Gursu SS. Effect of surgical approaches on deltoid innervation and clinical outcomes in the treatment of proximal humeral fractures. *J Dis Relat Surg* 2020; 31: 515-22.
- Flierl MA, Stahel PF, Hak DJ, Morgan SJ, Smith WR. Traction table-related complications in orthopaedic surgery. *J Am Acad Orthop Surg* 2010; 18: 668-75.
- Min KS, Sheridan B, Waryasz GR, et al. Predicting reoperation after operative treatment of proximal humerus fractures. *Eur J Orthop Surg Traumatol* 2021; 31: 1105-12.
- Dheenadhayalan J, Prasad VD, Devendra A, Rajasekaran S. Correlation of radiological parameters to functional outcome in complex proximal humerus fracture fixation: A study of 127 cases. *J Orthop Surg (Hong Kong)* 2019; 27: 2309499019848166.
- Neer CS, 2nd. Displaced proximal humeral fractures. I. Classification and evaluation. *J Bone Joint Surg Am* 1970; 52: 1077-89.
- Bouliane M, Silveira A, AlEidan A, et al. Factors associated with maintaining reduction following locking plate fixation of proximal humerus fractures: a population-based retrospective cohort study. *JSES Int* 2020; 4: 724-9.
- Rouleau DM, Balg F, Benoit B, et al. Deltopectoral vs. deltoid split approach for proximal humerus fracture fixation with locking plate: a prospective randomized study (HURA). *J Shoulder Elbow Surg* 2020; 29: 2190-9.
- Xie L, Zhang Y, Chen C, Zheng W, Chen H, Cai L. Deltoid-split approach versus deltopectoral approach for proximal humerus fractures: a systematic review and meta-analysis. *Orthop Traumatol Surg Res* 2019; 105: 307-16.
- Zhao L, Yang P, Zhu L, Chen AM. Minimal invasive percutaneous plate osteosynthesis (MIPPO) through deltoid-pectoralis approach for the treatment of elderly proximal humeral fractures. *BMC Musculoskelet Disord* 2017; 18: 187.
- Acklin YP, Stoffel K, Sommer C. A prospective analysis of the functional and radiological outcomes of minimally invasive plating in proximal humerus fractures. *Injury* 2013; 44: 456-60.
- Buecking B, Mohr J, Bockmann B, Zettl R, Ruchholtz S. Deltoid-split or deltopectoral approaches for the treatment of displaced proximal humeral fractures? *Clin Orthop Relat Res* 2014; 472: 1576-85.
- Borer J, Schwarz J, Potthast S, et al. Mid-term results of minimally invasive deltoid-split versus standard open deltopectoral approach for PHILOS (proximal humeral internal locking system) osteosynthesis in proximal humeral fractures. *Eur J Trauma Emerg Surg* 2020; 46: 825-34.
- Saran N, Bergeron SG, Benoit B, Reindl R, Harvey EJ, Berry GK. Risk of axillary nerve injury during percutaneous proximal humerus locking plate insertion using an external aiming guide. *Injury* 2010; 41: 1037-40.
- Kim YG, Park KH, Kim JW, et al. Is minimally invasive plate osteosynthesis superior to open plating for fixation of two-part fracture of the proximal humerus? *J Orthop Surg (Hong Kong)* 2019; 27: 2309499019836156.
- Hayda RA, Hsu RY, DePasse JM, Gil JA. Radiation Exposure and Health Risks for Orthopaedic Surgeons. *J Am Acad Orthop Surg* 2018; 26: 268-77.
- Wang JQ, Lin CC, Zhao YM, Jiang BJ, Huang XJ. Comparison between minimally invasive deltoid-split and extended deltoid-split approach for proximal humeral fractures: a case-control study. *BMC Musculoskelet Disord* 2020; 21: 406.
- Cheung S, Fitzpatrick M, Lee TQ. Effects of shoulder position on axillary nerve positions during the split lateral deltoid approach. *J Shoulder Elbow Surg* 2009; 18: 748-55.
- Oppeboen S, Wikeroy AKB, Fuglesang HFS, Dolatowski FC, Randsborg PH. Calcar screws and adequate reduction reduced the risk of fixation failure in proximal humeral fractures treated with a locking plate: 190 patients followed for a mean of 3 years. *J Orthop Surg Res* 2018; 13: 197.
- Knezevic J, Mihalj M, Cukelj F, Ivanisevic A. MIPO of proximal humerus fractures through an anterolateral acromial approach. Is the axillary nerve at risk? *Injury* 2017; 48: 15-20.
- Shin YH, Lee YH, Choi HS, Kim MB, Pyo SH, Baek GH. A modified deltoid splitting approach with axillary nerve bundle mobilization for proximal humeral fracture fixation. *Injury* 2017; 48: 2569-74.
- Traver JL, Guzman MA, Cannada LK, Kaar SG. Is the axillary nerve at risk during a deltoid-splitting approach for proximal humerus fractures? *J Orthop Trauma* 2016; 30: 240-4.
- Harun A, Selin E. What should be the surgical position choice in a patient having proximal humeral fracture with developed hypotension? *J Orthopedic Surg Techniques* 2021; 4.