



## Vaginal Fibrosarcoma in a Brown Swiss Cow

Mushap KURU<sup>1</sup>✉, Enver BEYTUT<sup>2</sup>, Semra KAYA<sup>1</sup>, Emin KARAKURT<sup>2</sup>, Cihan KAÇAR<sup>1</sup>

1. Kafkas University, Faculty of Veterinary Medicine, Department of Obstetrics and Gynecology, Kars, TURKEY.
2. Kafkas University, Faculty of Veterinary Medicine, Department of Pathology, Kars, TURKEY.

Geliş Tarihi/Received:  
01.12.2015

Kabul Tarihi/Accepted:  
13.06.2016

Yayın Tarihi/Published:  
31.12.2016

**Abstract:** The presented case includes the vaginal fibrosarcoma hanging out through the lips of vulva of a 3-year old, brown Swiss cow and removal of the mass with operative intervention. In the clinical examination of the cow, no disorder other than the mass was detected. A hemorrhagic, necrotic, lobular mass spreading to various regions of vagina and hanging out through the lips of vulva was identified in clinical examination. The mass with the diameter of 15 x 12.5 x 13 cm was removed from the site by operative intervention. Histopathological and immunohistochemical examinations revealed that the mass was vaginal fibrosarcoma. The cow has been followed up for 6 months postoperatively. No complication or recurrence was observed. In conclusion, we believe that the vaginal fibrosarcoma in the presented case which was diagnosed as a result of histopathological and immunohistochemical examinations in a -3 year old cow will contribute to the scientific literature.

**Keywords:** Cow, fibrosarcoma, histopathological, immunohistochemical.

## İsviçre Esmeri Bir İnekte Vaginal Fibrosarkom

**Öz:** Sunulan olguyu, 3 yaşında olan İsviçre Esmeri bir inekte vulva dudakları arasından dışarı sarkan vaginal fibrosarkom ve kitlenin operatif girişim ile uzaklaştırılması oluşturmaktadır. İneğin klinik muayenesinde kitle dışında herhangi bir rahatsızlık tespit edilmedi. Klinik muayenede, vaginanın çeşitli bölgelerine yayılmış olan hemorajik, nekrotik, lobüler ve vulva dudakları arasından dışarı sarkan bir kitlenin olduğu tespit edildi. Yapılan operatif müdahale ile 15 x 12.5 x 13 cm çapındaki kitle bölgeden uzaklaştırıldı. Histopatolojik ve immunohistokimyasal değerlendirmeler sonucunda kitlenin vaginal fibrosarkom olduğu tespit edildi. Operasyon sonrası inek 6 ay boyunca takip edildi. Herhangi bir komplikasyon şekillenmediği ve nüks oluşmadığı gözlemlendi. Sonuç olarak, sunulan olgu da histopatolojik ve immunohistokimyasal incelemeler sonucu 3 yaşlı bir inekte tanısını konulan vaginal fibrosarkom olgusunun bilimsel literatüre katkı sağlayacağı kanısındayız.

**Anahtar Kelimeler:** Fibrosarkom, Histopatolojik, İmmunohistokimyasal, İnek.

## INTRODUCTION

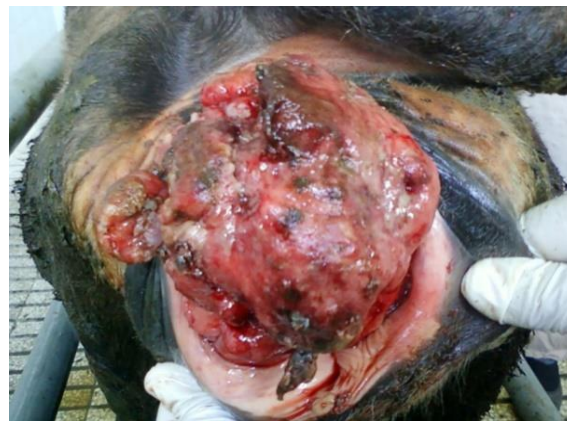**F**ibrosarcoma which is a tumor of mesenchymal origin that is rarely observed in cattle in the genital organs such as the vagina and penis (1,2). The tumor can exhibit mushroom-shaped growth and can spread over a large area and can hang out of the vulva lips (3,4). A study performed on the prevalence of vaginal and vulvar tumors in dairy cows (n=1.100) found tumors of the vagina or vulva in 24 cows (4). In another study conducted with 1.335 cattle, 138 tumor cases were detected during the clinical examination. When these tumors were classified according to their organ placement, 12 tumors were detected in the vulva, only one of them was found to be a fibrosarcoma (5). Tumors in the vagina such as fibrosarcoma can lead to infertility by preventing mating, they can also cause difficult births (6). Furthermore, removing breeding animals from the herd can cause financial losses because of the potential of tumor metastasis to other organs (4). It has been claimed that the surgical removal of tumors such as fibrosarcoma rarely leads to metastasis (2), and furthermore, other studies found no complication or metastasis after extirpating a fibrosarcoma with surgical removal or cauterization.

In this case, histopathological and immunohistochemical findings of a vaginal fibrosarcoma are described in a Brown Swiss cow.

## CASE REPORT

The case involved a 3-year-old Brown Swiss cow that was brought to the clinic of the Department of Obstetrics and Gynecology, Faculty of Veterinary Medicine, University of Kafkas. It was reported that the cow had given natural birth 2 months ago. The owner of the cow had noticed the mass 10 days prior and said that the mass was growing gradually. In the clinical examination, we detected a hemorrhagic, necrotic, lobular mass between the vulva lips that was hanging out and had spread to various parts of the vagina (Figure 1). There was no other disease or finding observed in the cow except the mass in the

vulva. The decision was then made to remove this mass via surgery.



**Figure 1.** The appearance of the mass before the operation.

**Şekil 1.** Operasyon öncesi kitlenin görünümü.

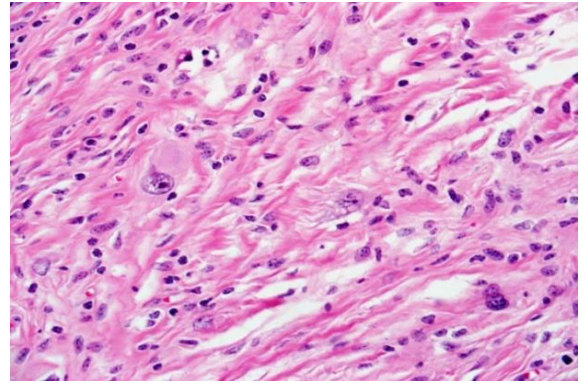
After applying aseptic and antiseptic measures to the area, 7 mL of local anesthetic for lower epidural anesthesia (2% lidocaine, Adokain<sup>®</sup>, Sanovel, Turkey) was applied. Subsequently, 30 mL of local anesthetic (2% lidocaine) was injected under the skin around the mass. The mass was surgically removed and sent to the laboratory for histopathological examination. During the operation, bleeding regions were ligated. The incisions were stitched to prevent the vaginal tissue from adhering to each other. During the postoperative period, 15 mL injections of intramuscular antibiotics (200.000 IU procaine benzympenicillin, 200 mg dihydrostreptomycin sulfate, Reptopen-S<sup>®</sup>, CEVA-DIF, Turkey) was applied to the cow for 7 days. No complication was observed when the cow was examined 6 months after the operation.

The mass extirpated in the surgical operation, was measured at 15 x 12.5 x 13 cm and submitted to the Department of Veterinary Pathology for histopathological evaluation. Tissue samples from the tumoral mass were fixed in 10% buffered formalin, processed routinely and stained with Hematoxylin & Eosin (H&E) and Masson's Trichrome.

Serial sections from the mass were stained immunohistochemically using the avidin-biotin-peroxidase complex (ABC) technique (7) for vimentin, S-100, desmin and Ki-67 markers. The 4  $\mu$  sections were placed on poly-L-lysine coated slides, and after deparaffinization and rehydration, they were incubated with a solution of 3% hydrogen peroxide in methanol for 20 minutes to prevent endogenous peroxidase activity. A microwave oven was used to reveal the antigenic receptor. After that, the sections were incubated in rabbit serum for 30 minutes. Then, the slides were separately incubated with mouse Monoclonal anti-Desmin (ScyTek), monoclonal mouse-anti vimentin (Novocastra), Mouse Anti-S-100 Monoclonal Antibody (ScyTek) and Mouse monoclonal Ki67 antibody (Biocare) primary antibodies. After the sections had been incubated with biotinylated rabbit anti-mouse immunoglobulins for 60 minutes at RT, they were incubated with peroxidase-conjugated streptavidin for 30 minutes at RT. Following completing of all incubations, the sections were washed 3 times for 5 minutes with PBS. The sections were incubated with a solution of 3,3'-diaminobenzidine tetrahydrochloride (DAB) chromogen for 10 to 15 minutes and then they were incubated with Mayer's hematoxylin for 5-20 seconds.

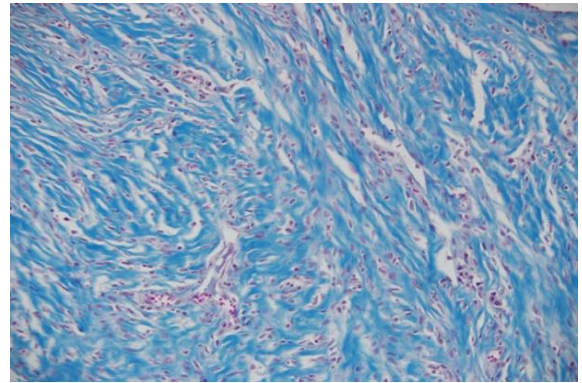
A histopathological examination revealed that the tumor tissue was composed of spindle-shaped cells with basophilic nuclei, a swirl-like proliferation, and widely distributed collagen connective tissue (Figure 2). Pleomorphism and hyperchromasia were also found in tumor cells. Furthermore, the mitotic index was found to be remarkably low, with 1-2 cells at the 40x magnification. There was also an increment in the number of lymphocytes and plasmocytes as a focal settlement in the tumor cells of the neoplastic tissue. Prominent collagen bands were detected in the tumor tissue using Masson Trichrome staining (Figure 3). In the immunohistochemical examination, it was determined that the tumor cells were strongly positive for vimentin (Figure 4) and slightly positive for S-100 (Figure 5) due to the cytoplasmic reaction. Furthermore, a low number of tumor cells also exhibited a Ki-67-positive nuclear reaction (Figure 6).

In conclusion, the mass was diagnosed as vaginal fibrosarcoma by immunohistochemical and histopathological findings.



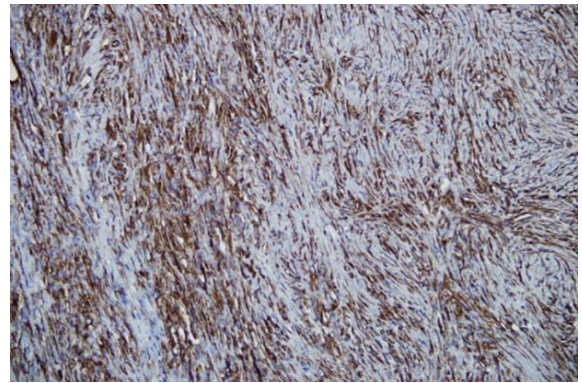
**Figure 2.** Tumor tissue composed of spindle-like cell proliferation, HEx40.

**Şekil 2.** İğ benzeri hücre proliferasyonundan oluşan tümör dokusu, HEx40.



**Figure 3.** Common collagen connective tissue in the tumor tissue, Masson's Trichromex20.

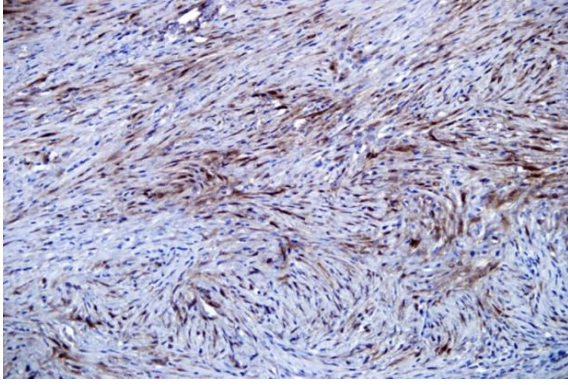
**Şekil 3.** Tümör dokusunda yaygın kollagen bağ dokusu, Masson's Trichrome x20.



**Figure 4.** Common positive reactions for vimentin in tumor cells, ABCx20.

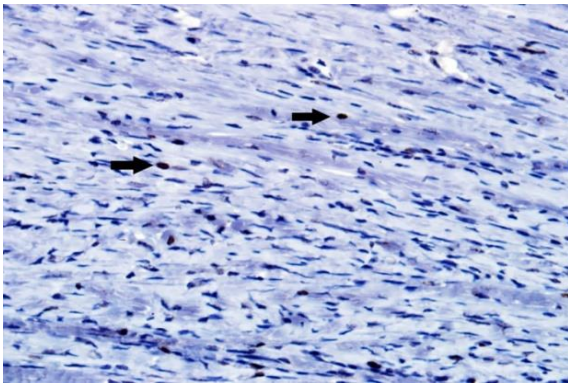
**Şekil 4.** Tümör hücrelerinde vimentin yaygın pozitif reaksiyon, ABCx20.





**Figure 5.** S-100 positive reaction in tumor cells, ABCx20.

**Şekil 5.** Tümör hücrelerinde S-100 pozitif reaksiyon, ABCx20.



**Figure 6.** Ki-67 positive reaction in a low number of tumor cells (arrows), ABCx40.

**Şekil 6.** Az sayıda tümör hücresinde Ki-67 pozitif reaksiyon (oklar), ABCx40.

## RESULTS and DISCUSSION

Tumors such as squamous cell carcinoma, leiomyoma, fibroma, fibropapilloma, hemangioma, fibrosarcoma, leiomyoma-sarcoma, and melanoma have been reported in the vagina or vulva of cows (4). However, fibroma and fibrosarcoma are rarely observed in the vagina or vulva (4). Such tumors can cause gynecological and urological issues depending on their size (6). In the case reported in this study, there was a vaginal fibrosarcoma in a cow which occurred before giving birth, became larger after the delivery and prevented mating as well as artificial insemination. There was no complication observed in the cow after the surgical operation. Various studies have reported no complication or metastasis after the surgical removal of vaginal tumors such as fibrosarcoma (3,6).

Even though cases of fibrosarcoma can be observed in various parts of a cow's body, they are rarely seen in the vagina. In this case, which is consistent with the literature (3,5), the investigators observed the characteristic swirl-like proliferation of spindle-shaped tumor cells with pleomorphism and hyperchromasia. It is well known that the mitosis number of the cells in the microscopic area is critical in the prognosis of the tumor (2). In this case, the mitotic index was found to be low. Some researchers (2,8) have reported that the mitotic index in mammary gland fibrosarcoma was higher compared to those occurring in the vagina. The low mitotic index in our case can be associated with the disappearance of the tumor without metastasis or recurrence after the removal of it via a surgical operation. Although leiomyosarcomas are of smooth muscle cell origin and fibrosarcomas are of fibrous tissue origin, routine histological methods are not sufficient for the differential diagnosis of tumors of mesenchymal origin. On the other hand, collagen bands can also be observed in these types of tumors by Masson trichrome staining (2,9). In our case, routine histological findings and the results of Masson trichrome staining indicated that the tumor was a fibrosarcoma. At the same time, we emphasize the importance of tumor marker evaluation (for proteins such as vimentin, desmin, and S-100) using immunohistochemical methods (9,10). We observed that the tumor cells were strongly positive for vimentin and slightly positive for S-100 with a cytoplasmic reaction, whereas the tumor cells were negative to desmin. Therefore, we concluded that the tumor originated from fibrous tissue.

Our results may contribute to the veterinary medicine literature by summarizing of findings in a 3-year-old cow diagnosed with vaginal fibrosarcoma using histopathological and immunohistochemical investigations. We also believe that a surgical treatment will be useful in the field of veterinary medicine.

## REFERENCES

1. Hesaraki S., Abedi GH., Rismanchi S., 2010. Penile fibrosarcoma tumor in a bull. *Iranian Journal of Veterinary Research*, 11, 283-286.
2. Maclachlan NJ., Kennedy PC., 1990. *Tumors of the*

- genital systems. In "Tumors in Domestic Animals", Ed., JE Moulton, 3<sup>rd</sup> ed., 547-574, University of California Press, California.
3. Musal B., Ulutas P., Aydogan A., 2007. Vaginal fibrosarcoma in a cow. *Irish Veterinary Journal*, 60, 424-425.
  4. Yeruham I., Perl S., Orgad U., Yakobson B., 1999. Tumours of the vulva and vagina in cattle – A 10-year survey. *The Veterinary Journal*, 158, 237-239.
  5. Naghshineh R., Sohrabi-Haghdoost I., Mokhber-Dezfuli MR., 1991. A retrospective study of the incidence of bovine neoplasms in Iran. *Journal of Comparative Pathology*, 105, 235-239.
  6. Çolak A., Sağlam YS., Kamiloğlu A., Karaman M., 1997. Bir inekte rastladığımız vaginal tümör olgusu. *Kafkas Üniversitesi Veteriner Fakültesi Dergisi*, 3, 93-96.
  7. Hsu S., Raine L., Fanger H., 1981. Use of avidin-biotin-peroxidase techniques: A comparison between ABC and unlabeled antibody (PAP) procedures. *Journal of Histochemistry & Cytochemistry*, 29, 577-580.
  8. Orr JP., 1984. Fibrosarcoma affecting the mammary gland of a cow. *The Canadian Journal of Comparative Medicine*, 48, 219-222.
  9. Avcı H., Serin G., Aydogan A., Birincioglu S., 2010. Primary vaginal fibroleiomyosarcoma in a 4-year-old Holstein-Friesian cow. *Turkish Journal of Veterinary and Animal Sciences*, 34, 307-311.
  10. Enginler SO., Gunduz MC., Sabuncu A., Senunver A., Yildiz F., Arun SS., 2011. Vaginal leiomyosarcoma in a holstein cow. *Kafkas Üniversitesi Veteriner Fakültesi Dergisi*, 17, 325-327.