

The Importance of The Atlas Vertebra and Its Variations

Hüseyin Baylan

Sakarya Üniversitesi Tıp Fakültesi Anatomi Anabilim Dalı, Sakarya

Özet

Rutin osteoloji uygulamasında varyasyonel bir atlas karşımıza çıkabilir çünkü atlas omuru insandaki en çok varyasyona sahip omurdur. Boyna yapılan cerrahi operasyonlarda özellikle atlas omurunun varyasyonları cerrahlar tarafından önceden bilinmelidir çünkü atlas omuru ile çok yakın seyreden arteria vertebralis'lerin hasarlanması önlenmelidir. Arteria vertebralis'lerin meninksleri, dura mater'i, omuriliğin boyun kısmını ve spinal ganglionları kanlandırmasından dolayı bu arterin hasarı vertebrobasiler iskemiye bağlı migren, vertigo, diplopi gibi durumlara yol açabilir. Vertebral venler ve arterin etrafındaki sinir pleksusu da atlasın travmalarında incinip klinik semptom ve komplikasyonları zenginleştirebilir.

Anahtar Kelimeler: atlas vertebra, processus transversus, varyasyon, boyun omuru

Abstract

During routine osteology demonstration one may notice a variational atlas vertebra because the atlas is the most variable vertebra in man. The variations of it should be known especially before the operations to the neck performed by the surgeons because the vertebral arteries are close to it. And the vertebrobasilar ischemia which may lead to some bad conditions like migraine, vertigo, diplopia can be due to injuries of the vertebral arteries which supply blood to the meninges, dura mater, cervical part of the spinal cord and spinal ganglions. The vertebral veins and the nervous plexus around the artery may also be injured in traumas of this region so these structures involved may enrich the clinical symptoms and complications.

Keywords atlas vertebra, transverse process, variation, cervical vertebra

Introduction

The first cervical vertebra, namely the atlas, supports the head and is not a typical vertebra due to its shape and having neither body nor spinous process (Figure1).

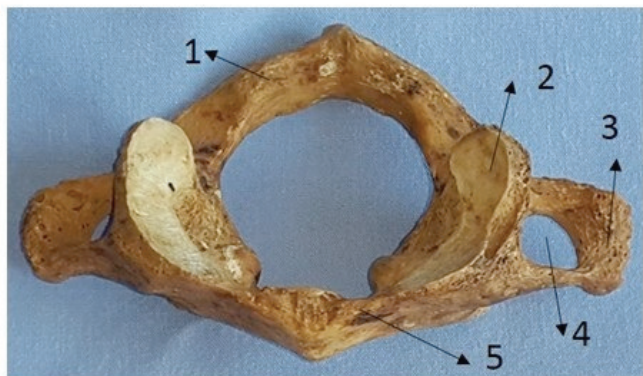


Figure 1: Superior aspect of a usual atlas vertebra without a variation

1. Arcus posterior atlantis
2. Facies articularis superior (massa lateralis)
3. Processus transversus
4. Foramen transversarium
5. Arcus anterior atlantis
6. Sulcus arteria vertebralis

A short anterior and a long posterior arches are joined with two thick lateral masses in the atlas anterolaterally. In the midline of the atlas, both arches have a tuberculum at outer edges in the anteroposterior directions. The lateral masses articulate with occipital condyles superiorly, and with the superior articular facet of the axis inferiorly. There is also a synovial joint for the dens of the axis at the inner face of the anterior arch of the atlas to provide the position of the atlas with the help of the transverse ligament¹. A usual atlas has transverse processes bilaterally with foramina transversarium. Among upper six cervical vertebrae, the atlas has the longest transverse processes that are useful for fine balancing of the head movements thanks to some muscles inserted to the atlas¹.

The transverse process consists of anterior and posterior parts that form the foramina transversarium where the vertebral vessels and nervous plexus are transmitted². The anterior part is called costal element or costal process because it is believed to be the homologue of the rib¹. The posterior part is directed forwards and laterally and it is the true transverse process

behind the foramen.

The foramen transversarium is limited by the "costotransverse bar" laterally which is grooved superiorly for the cervical spinal nerves crossing the vertebral vessels posteriorly².

At the superior aspect behind the lateral mass, the posterior arch has a groove for vertebral artery, venous plexus and dorsal rami of first cervical nerve³. The posterior atlantooccipital membrane attaches to the posterior arch of the atlas and at each lateral border the vertebral artery and the first cervical nerve pierce it³.

In textbooks, atlantal width is between 74 mm and 95 mm in males and between 65 mm and 76 mm in females¹. However, the distance between tips of the transverse processes of the atlas ranged from 29.8 to 84.9 mm (mean 74.6 mm) in an article⁴.

The vertebral artery is very crucial for neurology because it supplies the meninges, dura mater in the posterior cranial fossa, cervical part of the spinal cord and spinal ganglions^{5,6}. Exiting from the transverse foramen of the atlas, the vertebral artery directs to a groove for itself at the posterior arch of the atlas behind the superior facet, then it enters the occipital triangle and subsequently passes through the opening of the posterior atlantooccipital membrane to enter the cranial cavity through foramen magnum^{3,5,7}. After entering foramen magnum the two corresponding vertebral arteries converge to form the basilar artery¹.

There are some crucially important anatomical structures around the transverse processes of the atlas. For instance, the styloid process is anterior to the transverse process and between these two processes are the last three cranial nerves (X, XI, and XII) and the internal jugular vein. The occipital artery, the posterior belly of the digastric muscle and the stylohyoid muscle are all lateral to the transverse process of atlas. Lastly, the suboccipital triangle is posterior to the transverse process^{1,8}.

Above the posterior arch of the atlas, small vessels from internal vertebral plexuses leave the vertebral canal and join with

small veins in the suboccipital triangle to form a venous plexus that enters the transverse foramen of the atlas around the vertebral artery. This venous plexus descending ends as the vertebral vein ¹.

Human atlas morphology correlates with head and neck posture ⁹. The most variable vertebra in man is the atlas and the aetiological factors of these variations were explained on an embryological basis ^{10,11}.

The common variations of atlas reported in literature include incomplete unilateral or bilateral foramen transversarium ^{1,12,13}, complete or incomplete retroarticular foramen (has lots of synonyms ¹⁴), double foramina (or accessory transverse foramina) ⁶, abnormal foramina on posterior arch, incomplete posterior arch (split posterior arch), split anterior arch, spur on anterior arch, a thick body, a thin vertebral artery groove, abnormal inferior articular facet ³, split superior articular process, different shapes of superior articular facet (oval, 8-shape, kidney shape, bilobed, trilobed and irregular, triangular, V-shape and leaf shape ³), partial or total fusion of atlas with the occipital bone ¹⁵, and some accessory bony arches embracing the vertebral artery ^{10,16}. Some accessory foramina may be encountered in the atlas ¹⁷.

Variations in the course of the vertebral artery are postulated to be the cause of variant foramina transversarium but not well known ^{2,6,18}. The vertebral artery occupies more than half of the diameter of the transverse foramen ^{5,6}. As a result, the vertebral artery may be a factor to change the size of the transverse foramina formation due to tortuosity and bone erosion ¹⁹.

Atlas injuries are reported as 25% of all injuries to the atlantoaxial complex ²⁰. But the transverse process fractures are reported as rare ²¹. The fractures of the transverse process may injure vertebral arteries resulting in subarachnoid haemorrhages ²². Especially in the neck operations, the transverse process of the atlas is told as an important landmark by surgeons ²³. When planning the operations to the neck region the vertebral artery injuries should be avoided by surgeons. Especially the incomplete foramen transversarium makes the second part of the vertebral artery vulnerable in posterior

cervical operations ¹². Injuries of the vertebral artery may affect the brain stem and cerebellum resulting in neurological problems like unconsciousness, respiratory and cardiovascular impairments ⁴. A compression on the vertebral artery may cause vertebrobasilar ischemia which may lead to common symptoms like migraine, vertigo, diplopia, shoulder pain, neck pain or severe incidents of cerebrovascular incidents ²⁴. Fortunately, in surgical operations, iatrogenic injury of the vertebral artery is reported to be rare ²⁵. Besides in atlantoaxial region there are lots of surgical procedures like the interlaminar clamp and hook plating, lateral screw, and plate fixation, and interspinous wiring being used in order to treat cervical instability ⁴. Atlas development is reported to be a factor in some situations such as transient vertebrobasilar insufficiency, Barre-Lieou syndrome, and chronic upper cervical syndrome ²⁶. An article highlights that cerebellar haemorrhage complications in supratentorial craniotomy operations may be due to the obstruction of the flow in the internal jugular vein which sits anteriorly to the transverse process of the atlas ⁸.

As a conclusion, an incomplete transverse foramen may be confused radiologically with acquired anomalies when interpreting about X-ray and CT scans. Because of the crucial neighbourhoods, the variations of the foramina transversarium should be well known before planning head and neck operations by disciplines like neurosurgery, orthopaedic surgery to prevent especially vertebral artery injuries in order not to cause any neurological deficits.



References

1. Susan Standing, *Gray's anatomy: the anatomical basis of clinical practice*. (Elsevier Health Sciences, 2015).
2. C Taitz, H Nathan, and B Arensburg, *Journal of Neurology, Neurosurgery & Psychiatry* 41 (2), 170 (1978).
3. C Gupta, P Radhakrishnan, Vikram Palimar, Antony Sylvan D'souza, and NL Kiruba, *J Morphol Sci* 30 (2), 77 (2013).
4. GOKSIN Sengul and HH Kadioglu, *Turkish neurosurgery* 16 (2), 69 (2006).
5. Tarik H Abd El-Bary, Manuel Dujovny, and James I Ausman, *Surgical neurology* 44 (4), 392 (1995).
6. Paul Bundi Karau and Paul Odula, *Anatomy Journal of Africa* 2 (1), 61 (2013).
7. Bernard George and Jan Cornelius, *Operative techniques in Neurosurgery* 4 (4), 168 (2001); Arnold H Menezes and Vincent C Traynelis, *Child's Nervous System* 24 (10), 1091 (2008); MG Yasargil, Stuttgart: Georg Thieme Verlag 119 (1969).
8. Eduardo Seoane and Albert L Rhoton, *Surgical neurology* 51 (5), 500 (1999).
9. Müge Sandıkçioğlu, Søren Skov, and Beni Solow, *The European Journal of Orthodontics* 16 (2), 96 (1994).
10. Jarostaw Wysocki, Mariusz Bubrowski, Jerzy Reymond, and Jan Kwiatkowski, *Folia Morphologica-Warszawa-English Edition* 62 (4), 357 (2003).
11. Robert Wayne Bailey, *The cervical spine*. (Lea & Febiger, 1974).
12. Qudusia Sultana, Ramakrishna Avadhani, KL Varalakshmi, and MH Shariff, *Nitte University Journal of Health Science* 5 (2) (2015).
13. N Vasudeva and R Kumar, *Cells Tissues Organs* 152 (3), 230 (1995).
14. R Shane Tubbs, Philip C Johnson, Mohammadali M Shoja, Marios Loukas, and W Jerry Oakes, *Journal of Neurosurgery: Spine* 6 (1), 31 (2007).
15. Satheesha Nayak, Venkata Ramana Vollala, and Deepthinath Raghunathan, *Neuroanatomy* 4, 39 (2005).
16. Satheesha Nayak, *Neuroanatomy* 6, 28 (2007).
17. RJ Terry and M Trotter, in *Morris' human anatomy: a complete systematic treatise* (The Blakiston New York, 1953), pp. 288; H Sherk and W Parke, (Philadelphia: JB Lippincott, 1989).
18. Servikal Omurgada Aksesuar Transvers Foramen, *Turkish neurosurgery* 21 (3), 384 (2011).
19. Divya Agrawal, Biswa Bhusan Mohanty, Sunita Sethy, Bijaylaxmi Parija, Santosh Kumar Hazary, and Prafulla Kumar Chinara, *Int J Cur Res* 4, 120 (2012); LA Hadley, *The American journal of roentgenology, radium therapy, and nuclear medicine* 80 (2), 306 (1958); SE Hyppä, EM Laasonen, and V Halonen, *Neuroradiology* 7 (1), 49 (1974).
20. AM Levine and CC Edwards, *The Orthopedic clinics of North America* 17 (1), 31 (1986).
21. John A Gehweiler Jr, Denise E Duff, Salutarío Martínez, Michael D Miller, and William M Clark, *Skeletal Radiology* 1 (2), 97 (1976).
22. CP Johnson, T How, M Scraggs, CR West, and J Burns, *Forensic science international* 109 (3), 169 (2000).
23. Tzung-Shiahn Sheen, K Lawrence Yen, Jenq-Yuh Ko, and Mow-Ming Hsu, *Otolaryngology-Head and Neck Surgery* 122 (2), 284 (2000).
24. A Krishnamurthy, SR Nayak, S Khan, Latha V Prabhu, Lakshmi A Ramanathan, C Ganesh Kumar, and A Prasad Sinha, *Rom J Morphol Embryol* 48 (3), 263 (2007); Ahmet Kavakli, Atif Aydinlioglu, Hakki Yesilyurt, Ilter Kus, Semih Diyarbakirli, Saadet Erdem, and Omer Anlar, *Saudi medical journal* 25 (3), 322 (2004).
25. Nabil A Ebraheim, Rongming Xu, Muhammad Ahmad, and Bruce Heck, *Spine* 23 (3), 320 (1998)
26. M Buna, W Coghlan, M deGruchy, D Williams, and O Zmiywsky, *Journal of Manipulative and Physiological therapeutics* 7 (4), 261 (1984); BGH Lamberty and S Đivanovič, *Cells Tissues Organs* 85 (1), 113 (1973); J Mitchell, *Cells Tissues Organs* 163 (2), 113 (1998); C Taitz and H Nathan, *Cells Tissues Organs* 127 (3), 212 (1986).