

An additional tendon of the extensor digitorum brevis muscle of the foot: is there an accessory muscle?

Nurcan Erçıktı¹, Nihal Apaydın², Niyazi Acer³

¹Department of Anatomy, Gülhane Military Medical Academy, Ankara, Turkey

²Department of Anatomy, Faculty of Medicine, Ankara University, Ankara, Turkey

³Department of Anatomy, School of Medicine, Erciyes University, Kayseri, Turkey

Abstract

An accessory muscle adjacent to the extensor digitorum brevis muscle was encountered between the extensor digitorum brevis muscle and the tendon of the peroneus brevis on the right foot of a 75-year-old male cadaver. This accessory muscle and its tendon is of clinical significance for clinicians performing tendon transfers and other surgical procedures in the region, or when they use EDB as pedicles or free flaps at the ankle area or in other body parts.

Keywords: accessory muscle; extensor digitorum brevis; variation

Anatomy 2015;9(3):189–191 ©2015 Turkish Society of Anatomy and Clinical Anatomy (TSACA)

Introduction

Extensor digitorum brevis muscle (EDB) is located on the dorsum of the foot. It arises from the forepart of the upper and lateral surfaces of the calcaneus and passes to the dorsum of the foot to insert on the dorsal aponeurosis of the 2nd to 4th toes. EDB is supplied by the deep peroneal nerve.^[1] Del Pinal and Herrero^[2] reported that EDB muscle flap can be used either as a pedicle or as a free flap with minimal donor site morbidity, therefore its tendon or presence of an accessory muscle here may be important. EDB tendons may vary in number, sometimes there are two tendons, or even one tendon, and cases without EDB have also been described. Occasionally, a slip may join the long extensor tendon of the little toe, increasing the tendons to five.^[3]

Case Report

An accessory EDB muscle was found on the right foot of a 75-year-old male cadaver during the routine dissection for undergraduate medical students in Department of Anatomy of Gülhane Military Medical Academy. The cadaver showed no signs of trauma or deformity on the right or left foot. We observed the accessory muscle as

separated from the EDB, 4.01 mm lateral to the tuberosity of the fifth metatarsal bone. The muscle belly was measured 2.83 mm. Continuing the dissection distally, we observed a long tendon of this muscle, 15.03 mm in length, inserting on the base of the proximal phalanx of the little toe (**Figures 1 and 2**). The thickness of the tendon was measured as 3.8 mm at its middle portion. The accessory EDB muscle was innervated by the deep peroneal nerve.

Discussion

Supernumerary or accessory muscles are not uncommon in the foot and ankle. The variations of the EDB have been reported before; however, the variation described here, an accessory muscle separate from the EDB, inserting with a long tendon to the base of the proximal phalanx of the little toe, is noteworthy as it has not been reported earlier.

Hill and Gerges^[4] reported two accessory tendons coursing medial and lateral to the main tendon, whereas the main tendon of the extensor hallucis longus muscle inserted normally. Asomugha et al.^[5] described an acces-




Figure 1. Left foot of the cadaver showing additional tendon of the extensor digitorum muscle (arrows). EDB: extensor digitorum brevis; EDL: extensor digitorum longus; PB: peroneus brevis muscle; PT: peroneus tertius

sory flexor muscle which inserted into the middle phalanx of the fifth toe. It differed from the ‘expansions’ of the tibialis posterior tendon. However, this accessory muscle was located at the plantar surface of the foot, not on the dorsal surface as in our case. Another well-known accessory tendon on the dorsal surface of the foot arises from the tendon of the fibularis brevis muscle; this is known as the digiti minimi quinti muscle. Jadhav et al.^[6] reported the presence of the digiti minimi quinti as 51% in an Indian population. This case is different from their report, as in our case the muscle is a part of EDB, not the

fibularis brevis. Bibbo et al.^[7] reported an accessory extensor tendon on the first metatarsophalangeal joint.

Christ and Brand-Saberi^[8] suggested that the etiology of these variations may be related to the partitioning of the common extensor muscle mass into discrete muscles during embryological development. During development, programmed cell death is known to play a role in shaping limbs, particularly by leading to separation of digital rays.^[9] Variability within these developmental processes, such as accessory tendons or the duplication or complete absence of muscles, may contribute to anomalies in leg musculature. Kaneff and Andreev^[10] suggested that biochemical, environmental, or genetic factors likely lead to the described anomaly within the first nine weeks of development.

The EDB and its accessory muscle and its tendon are therefore clinically important as they can be used as pedicles or free flaps with minimal donor site morbidity Baltensperger et al.^[11] suggested that EDB muscle is a feasible flap for the ankle area and Bakhach et al.^[12] and del Pinal and Herrero^[2] as a distally based flap.

Conclusion

The accessory EDB muscle and its tendon described for this time in this case are of particular significance to clinicians performing tendon transfers and other surgical procedures in the region, or using EDB as pedicles or free flaps at the ankle area or in other body parts.

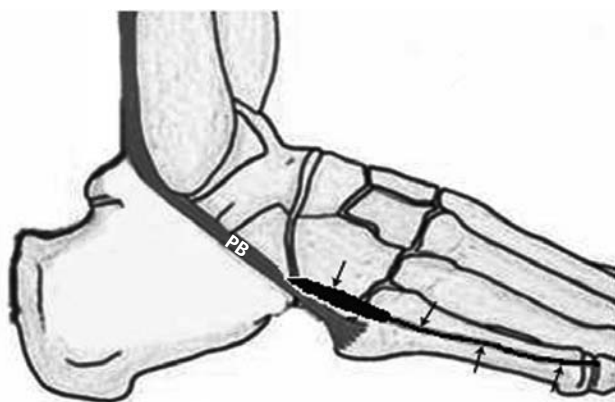


Figure 2. Schematic drawing of the case demonstrating the origin and insertion of the variant EDB muscle and its tendon (arrows). PB: peroneus brevis.

References

- Williams PL, Bannister LH, Berry MM, Dyson M, Dussek JE, Ferguson MWJ. Gray's anatomy. 38th ed. Edinburgh: Churchill Livingstone; 1995.
- Del Pinal F, Herrero F. Extensor digitorum brevis free flap: anatomic study and further clinical applications. *Plast Reconstr Surg* 2000;105:1347–56.
- <http://www.anatomyatlases.org/AnatomicVariants/MuscularSystem/Text/E/19Extensor.shtml>.
- Hill RV, Gerges L. Unusual accessory tendon connecting the hallu- cal extensors. *Anat Sci Int* 2008;12:83:298–300.
- Asomugha AL, Chukwuanukwu TO, Nwajagu GI, Ukoha U. An accessory flexor of the fifth toe. *Niger J Clin Pract* 2005;12:8:130–2.
- Jadhav SD, Gosavi SN, Zambare BR. Study of peroneus digiti min- imi quinti in Indian population: a cadaveric study. *Revista Argentina de Anatomía Clínica* 2013;5:67–72.
- Bibbo C, Arangio G, Patel DV. The accessory extensor tendon of the first metatarsophalangeal joint. *Foot Ankle Int* 2004;25:387–90.
- Christ B, Brand-Saberi B. Limb muscle development. *Int J Dev Biol* 2002;46:905–14.
- Moore KL, Persaud TVN. Before we are born: essentials of embry- ology and birth defects. 5th ed. Philadelphia: WB Saunders; 1998.
- Kaneff A, Andreev D. Über die organogenetische Entwicklung des M. extensor hallucis longus beim Menschen. *Anat Anz* 1983;154: 237–44.
- Baltensperger MM, Ganzoni M, Jirecek V, Meyer VE. The extensor digitorum brevis island flap: possible applications based on anatomy. *Plast Reconstr Surg* 1998;101:107–13.
- Bakhach J, Demiri E, Chahidi N, Baudet J. Extensor digitorum bre- vis muscle flap: New refinements. *Plast Reconstr Surg* 1998;102: 103–10.

Online available at:
www.anatomy.org.tr
doi:10.2399/ana.15.021
QR code:



deomed®

Correspondence to: Nurcan Erçikti, MD
Department of Anatomy, Gülhane Military Medical Academy,
Ankara, Turkey
Phone: +90 312 304 35 01
e-mail: nercikti@gata.edu.tr

Conflict of interest statement: No conflicts declared.

This is an open access article distributed under the terms of the Creative Commons Attribution-NonCommercial-NoDerivs 3.0 Unported (CC BY-NC-ND3.0) Licence (<http://creativecommons.org/licenses/by-nc-nd/3.0/>) which permits unrestricted noncommercial use, distribution, and reproduction in any medium, provided the original work is properly cited. *Please cite this article as:* Erçikti N, Apaydın N, Acer N. An additional tendon of the extensor digitorum brevis muscle of the foot: is there an accessory muscle? *Anatomy* 2015;9(3):189–191.