



Reconstruction of Lower Eyelid of Two Cats with Full Thickness Tissue Loss by Using Transposition Flap Technique*

O.O. ŞENEL, İ. ERGİN, B. KOÇ

Ankara University, Faculty of Veterinary Medicine, Department of Surgery, Ankara-TURKEY

Summary: The repair of eyelid full-thickness tissue defects could be solved rather simply by flaps derived from the frontal or temporal region, or rotated from the opposite lid or by free full-thickness skin grafts of eyelid. In this study, full thickness tissue loss of lower eyelid was described in two cats. In both cats, after en bloc resection of lesion, the full-thickness defect was reconstructed with a transposition flap from the temporal region. Histopathological examinations revealed squamous cell carcinoma. Transposition flap technique was found useful for reconstruction of wide full thickness eyelid defects resulting from squamous cell carcinoma excision. This technique yields satisfactory functional cosmetic results in cats.

Key Words: Cat, eyelid, reconstruction, squamous cell carcinoma, transposition flap

Alt Göz Kapağında Tam Kalınlıklı Doku Kaybı Olan İki Kedide Bölgenin Transpozisyon Flep Tekniği ile Onarımı

Özet: Göz kapağında tam kalınlıklı doku defektlerinin onarımı frontal veya temporal bölgeden veya karşı kapaktan döndürülerek getirilen fleplerle, ya da serbest deri greftleriyle yapılabilmektedir. Bu çalışmada, alt göz kapağında tam kalınlıklı doku kaybı olan iki kedide lezyon uzaklaştırıldıktan sonra bölgedeki defekt transpozisyon flep tekniği kullanılarak onarılmıştır. Histopatolojik incelemede alınan dokuların yassı hücreli karsinoma olduğu tespit edilmiştir. Kullanılan tekniğin, göz kapağında yassı hücreli karsinoma uzaklaştırıldıktan sonra meydana gelen geniş doku kayıplı yaraların onarımında etkili olduğu görülmüştür. Teknik, kedilerde fonksiyonel ve kozmetik açıdan değerlendirildiğinde oldukça tatmin edicidir.

Anahtar Kelimeler: Göz kapağı, kedi, onarım, transpozisyon flep, yassı hücreli karsinom

Introduction

Tumors and tumor-like lesions of the eyelids are less common in cats than in dogs but they are more likely to be malignant (8,1). In a review, involving 85 cats with eyelid neoplasm, squamous cell carcinoma (SCC) affected 65% of the cats, and in another group of 36 cats, it affected 36% (7). The prevalence of SCC is higher for white cats, especially for older cats. Local invasion of eyelid tissues by this tumor can be extensive, and metastasis occurs in advanced stages of the disease (4).

Full-thickness tissue loss in the eyelid is most commonly due to excision of neoplasm, but may

also be the result of trauma or congenital malformation. The repair of these defects has been surgical procedures. Where only skin and orbicularis muscle is involved, the problem is solved by flaps derived from the frontal or temporal region, or rotated from lip and the opposite lid or by free full-thickness skin grafts of eyelid or postauricular tissue (3,5,6). For treatment of SCC, wide surgical excision is often curative, and also grafting procedures are usually necessary to fill the lid defect (4).

In this case report, SCC was described in two cats in association with clinical and histopathological findings and transposition flap was performed after resection of the tumor.

Case Report

Two local-bred cats were presented to the clinic in different times. One of them was 17 years of age and female, and the other was 15 years of age and male. According to the anamnesis, the tumors

Geliş Tarihi/Submission Date : 12.03.2014
Kabul Tarihi/Accepted Date : 18.09.2014

* This case report has been presented as oral presentation at "73rd International SCIVAC Congress, Rimini, Italy" and supported by TÜBİTAK International Congress Support programme.

were growing slowly but progressively over a period of six to twelve months. The full-thickness eyelid defects were observed in the lower eyelid with ulceration and secondary infection in both cats. In the female cat, the lesion, extending from the lateral canthus to the medial canthus of the eye, was approximately 6 cm and obstructed the view (Figure 1A). In the male cat, the lesion was 3 cm, located in the medial canthus (Figure 1B).

For physical examination, regional lymph nodes were palpated for evidence of enlargement, but they were not involved. The tumors were irritating the conjunctiva and cornea by direct contact, visible metastasis was not observed in thorax by radiographically.

Surgical approach was decided in both cats. General anesthesia was induced with propofol (4 mg/kg, IV, Propofol 1% Fresenius, Fresenius Kabi, Germany) and maintained with isoflurane (Forane, Abbott, USA) in oxygen. En bloc resection of tumor of the lower eyelid from the medial canthus was performed. The third eyelid was protected from the dissection. The lid defect was reconstructed with a transposition skin flap derived from the temporal (lateral) region. The skin flap was sutured with simple interrupted sutures with 4/0 polypropylene (Figure 2A). The sutures were over the nictitating membrane dorsally, to the cutaneous edge of the surgical wound ventrally.

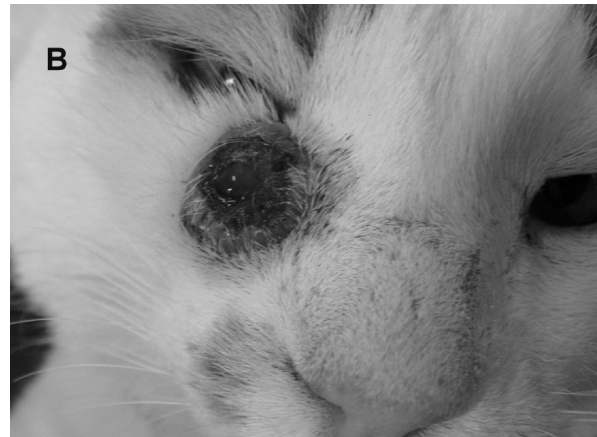
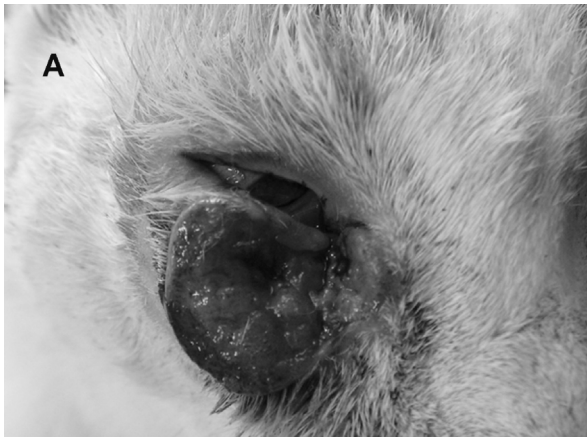

Figure 1. Lower eyelid squamous cell carcinoma **A)** 17 year old female cat, **B)** 15 year old male cat.

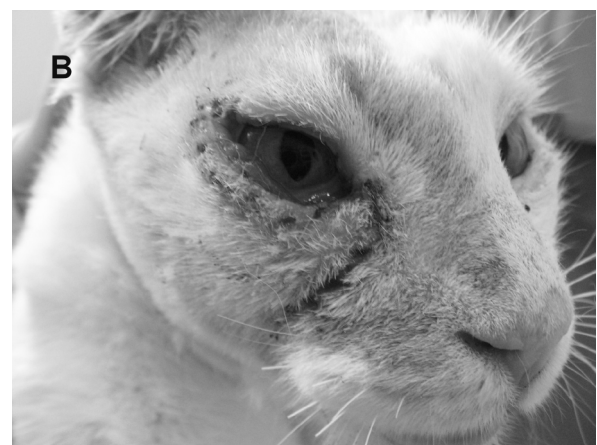
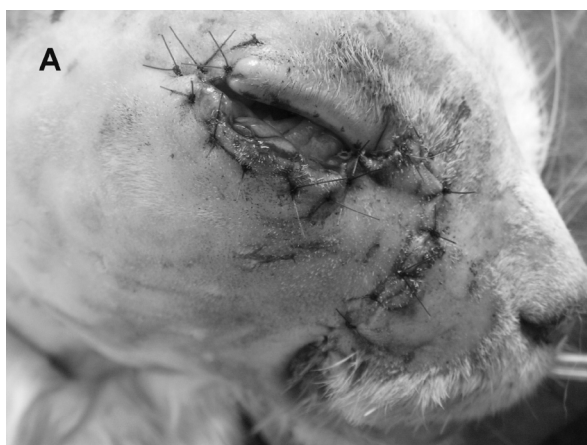
Figure 2. **A)** Reconstruction of defect with transposition full thickness flap technique in female cat. **B)** Appearance of the case, 2 weeks after the operation.

The cats were given amoxicillin-clavulanic acid (20 mg/kg, SID, PO, 6 days) and artificial tears (topically, 6 times a day, during 2 weeks) postoperatively. They were followed up every two days in the first week, every four days in the second and third weeks, and then every two months for one year. Contour of the lids, condition of the wounds and the eyes were examined at these controls for any case of infection or inflammation. The wound healing was completed in about 2 weeks (Figure 2B). There was no infection, no corneal ulcer, or any notable deformities.

Histopathological examination of the tumors revealed well-differentiated squamous epithelium with specific keratin pearls, surrounded by infiltration of lymphocytes, plasma cells and macrophages. The keratin tumor cells produce got trapped inside the tumor, forming pink, spherical in the centers (Figure 3).

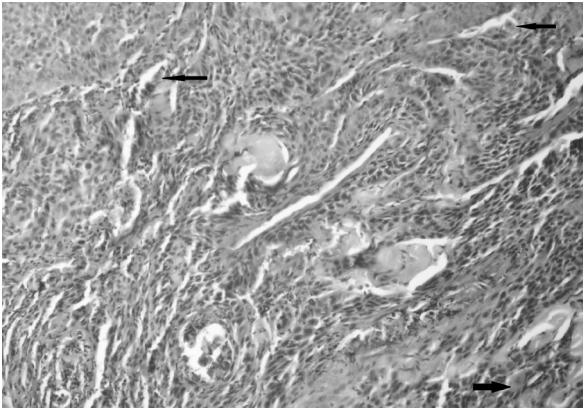


Figure 3. Histopathological findings of SCC (H&E). Whorl-shaped keratin pearls which are accumulations of keratin were seen typically (black arrows). Large nests with pink keratin in the centers.

Discussion and Conclusion

Squamous cell carcinoma appears as a slightly raised or depressed ulcerative lesion, often with a crusted surface, either on or adjacent to the eyelid margin in several animal species. Except for health and aesthetic problems, it caused a decrease in milk or meat yield in livestock, especially in cows and sheep. For these reasons, tumors must be removed completely from periocular region (4,3). In this report, tumors were irritating the cornea-conjunctival surface and creating aesthetic problems. Therefore, it was

decided that tumor was needed to be surgically removed.

The prognosis was suggested to correlate with the histopathologic degree of cellular differentiation (2). Histopathological examination of the two cases revealed high rate of cellular differentiation. However, there have been no recurrences during the subsequent 13 months. Lachrymal function was preserved and there were no corneal or conjunctival lesions.

Successful treatment of lower eyelid SCC can be achieved by 'en bloc' surgical removal. In addition, full-thickness tissue loss, if it is a small superficial central defect, may be closed directly. If it is a larger full-thickness lower eyelid defect, it may be repaired by flaps derived from the frontal, temporal or buccal region (5,9).

In this study, transposition flap technique was found very useful for reconstruction of wide full-thickness eyelid defects resulting from squamous cell carcinoma excision. Reconstruction of the lower eyelid using this technique yields satisfactory functional and cosmetic results in cats.

References

1. Aquino SM. Management of eyelid neoplasms in the dog and cat. *Clin Tech Small Anim Pract* 2007; 22(2): 46-54.
2. Bostock DE. The prognosis in cats bearing squamous cell carcinoma. *J Small Anim Pract* 1972; 13: 119.
3. Ceylan C, Ozyıldız Z, Yılmaz R, Biricik HS. Clinical and histopathological evaluation of bovine ocular and periocular neoplasms in 15 cases in Sanliurfa region. *Kafkas Univ Vet Fak Derg* 2012; 18(3): 469-74.
4. Glaze MB, Gelatt KN. Feline ophthalmology. Gelatt KN. ed. In: *Veterinary Ophthalmology*. Philadelphia: Lippincott Williams&Wilkins, 1999; pp. 997-1052.
5. Hunt GB. Use of the lip-to-lid flap for replacement of the lower eyelid in five cats. *Vet Surg* 2006; 35(3): 284-86.
6. Mcgregor IA. Eyelid and orbital reconstruction. Strauch B, Vasconez LO, Hall-Findlay EJ, Lee BT. ed. In: *Grabb's Encyclopedia of Flaps Head and Neck*. Philadelphia: Lippincott Williams&Wilkins, 2009; pp. 37-41.

7. McLaughlin SA, Whitley RD, Gilger BC, Wright JC, Lindley DM. Eyelid neoplasms in cats: a review of demographic data (1979-1989). *J Am Anim Hosp Assoc* 1983; 29: 63-7.
8. Newkirk KM, Rohrbach BW. A retrospective study of eyelid tumors from 43 cats. *Vet Pathol* 2009; 46: 916-27.
9. Schmidt K, Bertani C, Martano M, Morello E, Buracco P. Reconstruction of the lower eyelid by third eyelid lateral advancement and local transposition cutaneous flap after 'en bloc' resection of squamous cell carcinoma in 5 cats. *Vet Surg* 2005; 34 (1): 78-82.

Corresponding author:

İrem ERGİN DVM, PhD
Ankara University
Faculty of Veterinary Medicine
Department of Surgery
06110, Dışkapı-Ankara
0535 4676879
iremerg@gmail.com