



Examination of Anatomic and Morphometric Features of Kager's Triangle

Rabia SOLAK DÖNER^a, Papatya KELEŞ^b, Burak KARİP^c

^aDepartment of Anatomy, Faculty of Medicine, Istanbul Aydın University Istanbul, Türkiye

^{b,c}Department of Anatomy, Hamidiye Faculty of Medicine, University of Health Sciences, Istanbul, Türkiye

ARTICLE INFO

RESEARCH ARTICLE

Article history:

Received: 20 October 2022

Accepted: 7 November 2022

Available : 30 December 2022

^a<https://orcid.org/0000-0002-3498-3987>

^b<https://orcid.org/0000-0003-4096-8318>

^c<https://orcid.org/0000-0002-6757-4960>

*Correspondence: Rabia SOLAK DÖNER

Department of Anatomy, Faculty of Medicine,
Istanbul Aydın University Istanbul, Türkiye

e-mail: rabiasolak@aydin.edu.tr

Turkish Journal of Health Science and Life

2022, Vol.5, No.3, 207-2013

DOI: <https://10.56150/tjhsl.1191371>

ABSTRACT

Background/aim: In this study, it was aimed to determine the morphometric properties of the Kager's triangle, which is located in the posterior region of the ankle where interventional procedures are frequently performed and contains fat pad.

Materials and methods: For our study, bilateral lower extremity of 4 female and 4 male cadavers were dissected. Tibia length, fibula length, foot length, intermaleolar length, intercondylar length, gastrocnemius muscle's medial head and lateral head and tendon length, floor, anterior margin, posterior margin lengths and area of Kager's triangle were measured in the cadavers. Descriptive and statistical analysis of the morphometric measurements we made was performed.

Results: All 3 parts of the Kager's triangle, which are defined anatomically in the literature, have been observed. The base of the Kager's triangle is an average of 24.33 ± 2.05 mm in women and 31.44 ± 3.84 mm in men. The anterior border of Kager's triangle is 60.10 ± 6.56 mm in females and 67.19 ± 19.05 mm in males. The posterior border of Kager's triangle was found to be 55.61 ± 6.38 mm in women and 72.52 ± 17.56 mm in men. The area of Kager's triangle was found to be 6.74 ± 1.15 cm² on average in females and 9.06 ± 1.85 cm² in males.

Conclusion: The data obtained will be a guide for the injections to be applied to the region or surgical interventions to be performed in the region, especially for the treatment of pathologies such as Achilles tendinopathy in this region. It is aimed that this study will contribute to the literature on the anatomy of the relevant region.

Keywords: Anatomy, calcaneal tendon, Kager's fat pad, Kager's triangle, pre-achilles fat pad, retrocalcaneal bursa.

1. INTRODUCTION

Calcaneal tendon, which plays a major role in the movement of the ankle joint, is formed by the combination of the tendons of the gastrocnemius and soleus muscles, located on the back of the leg. This tendon plays a crucial role in energy transfer, energy storage and energy release during foot and ankle movement. Calcaneal tendon can be subjected to loads that increase up to 12 times a person's weight while running. Therefore, the importance of the structures that support it is increasing (1). Kager's triangle is one of the crucial support structures in this

region.

The triangular area, which was defined and named by Dr Hans Kager, has been called the Kager's triangle since 1977 (2). The ankle joint is located at the anteroinferior corner of the triangle (3). Kager's triangle, which has sharp borders and is radiolucent, is surrounded by calcaneal tendon posteriorly, tendon of the flexor hallucis longus muscle anteriorly and calcaneus inferiorly. Kager's fat pad, also known as the pre-achilles fat pad, covers the Kager's triangle, and the adipose tissue can sometimes extend to the soleus (4).

Studies reveal a close physical interaction between Kager's fat pad and surrounding structures during ankle movement. This suggests that Kager's fat pad can stabilize and maintain the mechanical function of the ankle joint. Kager's triangle, located in the anterior part of the calcaneal tendon and posterior part of the flexor hallucis longus, also facilitates the movement of the calcaneal tendon, during ankle plantar flexion and provides shock absorption for the tendon (3). Calcaneal tendon, can withstand a pulling force of approximately 1 ton. Although it is known to be so strong, it has been reported as the most frequently injured tendon in the literature. In pathologies occurring in the region, the boundaries of the Kager's triangle are disrupted (3). In treatments applied to this area, this fat pad atrophies. When we look at the studies in the literature, it has been seen that atrophy and fibrosis of the Kager fat pad can develop in the images obtained by magnetic resonance (MR) technique after steroid injection to this region for Achilles tendinopathy. Fat pads tendons; lubricates, insulates, protects and provides structural support (5). Atrophy of the foot fat pad also disrupts the foot biomechanics and causes abnormal gait and pain (6). In addition, it has been observed that the distal end of Kager's fat pad, the third part, in front of the retrocalcaneal bursa, is displaced with the retrocalcaneal bursa during ankle movement in healthy individuals. However, this displacement was not seen in individuals with hindfoot disorder. This 'variable piston' mechanism maintains foot biomechanics by minimizing pressure changes in the body (7).

Kager's fat pad also protects and supports blood vessels and facilitates the release of synovial fluid into the calcaneal tendon (3).

Many abnormal conditions of the ankle can include Kager's fat pad. It is necessary to pay attention to the borders of this triangle and the angles formed by these borders. Distortion in these borders and angles may indicate an abnormality (8).

The aim of this study is to fully reveal the anatomical and morphometric features of the region and to fully

define the anatomical localization and borders of the triangle with all its dimensions. With the data obtained, our aim is to be a guide for surgeons in injections to be applied to the region for the treatment of pathologies such as Achilles tendinopathy, or surgical interventions to be performed in this region, and to contribute to the literature that related to anatomy of this region.

2. MATERIALS AND METHODS

For the anatomical and morphometric examination of Kager's triangle, bilateral lower extremities were studied in 6 fixed cadavers in Department of Anatomy, Faculty of Medicine, University of Health Sciences and in 2 fixed cadavers in Department of Anatomy, Faculty of Medicine, Istanbul Aydın University. The ethics committee approval was obtained from the University of Health Sciences. In our study, the dissection of 8 cadavers, 4 females and 4 males, was performed with the equipment of our department. Measurements were made with a precision digital caliper and data were recorded in millimeters (mm).

For the base of the Kager's triangle, the distance between the point where the calcaneal tendon attaches to the calcaneus and the point where the flexor hallucis longus passes through the groove for tendon of flexor hallucis longus was measured vertically. For the anterior edge of the Kager's triangle, the distance between the intersection of the calcaneal tendon and the flexor hallucis longus and the point where the flexor hallucis longus passes through groove for tendon of flexor hallucis longus was measured vertically. For the posterior edge of the Kager's triangle, the distance between the intersection of the calcaneal tendon and the flexor hallucis longus and the point where the calcaneal tendon attaches to the tuber calcanei was measured vertically. The area of the Kager's triangle was calculated with the Heron formula, which was used to calculate the area of the triangle with known side lengths (Figure 1).

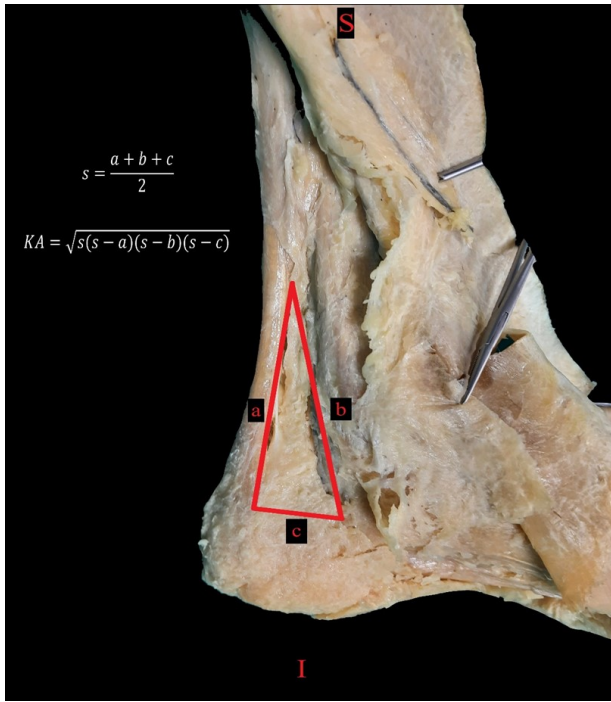


Figure 1: Calculating the sides of the Kager triangle and the area of the Kager triangle

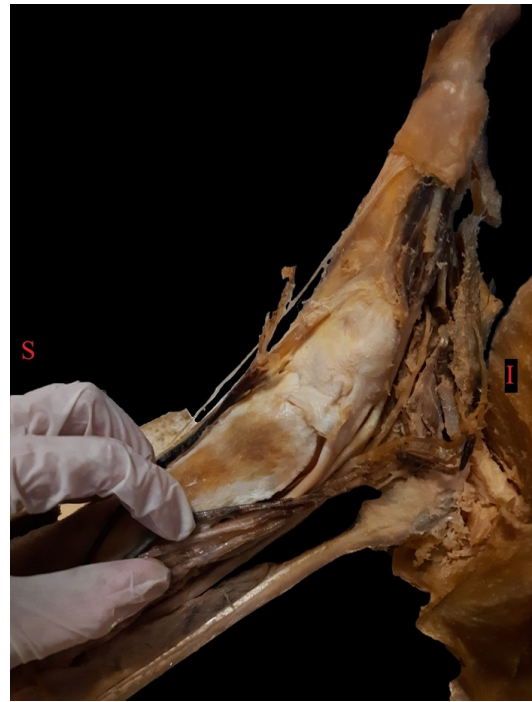

Figure 2: Removal of Kager fat pad

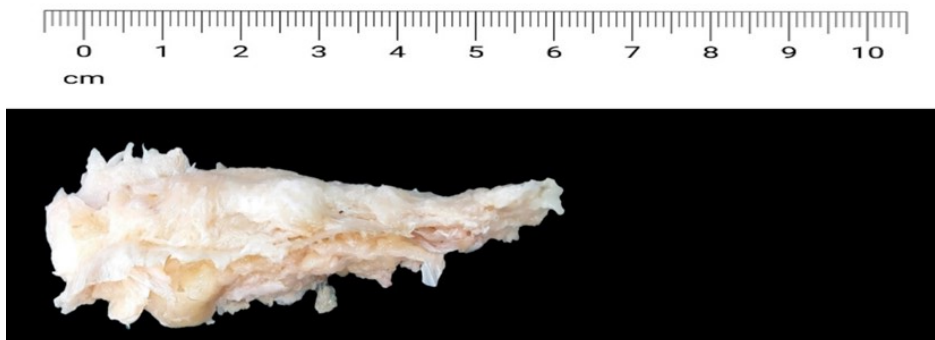


Figure 3: Kager fat pad

3. RESULTS AND DISCUSSION

According to the location of the fat pad in the Kager's triangle, it was observed as 3 sections as found in the literature. The first part is the part just in front of the

calcaneal tendon, the second part is the part behind the flexor hallucis longus muscle extending obliquely from lateral to medial a little lower, and the third part is the part in front of the retrocalcaneal bursa, which

Table 1: Minimum, maximum mean and standard deviation values of the morphometric data obtained as a result of the measurements

Parameters	Number of Extremities	Min (mm)	Max (mm)	Mean (mm)	Standard Deviation
KUT	15	20.66	36.22	28.12	4.76
KUOK	15	40.62	90.88	63.88	14.60
KUAK	15	49.17	96.34	64.63	15.74
Parameter	Number of Extremities	Min (cm ²)	Max (cm ²)	Mean (cm ²)	Standard Deviation
KA	15	5.48	12.69	7.98	1.93

KUT: Kager triangle base, KUOK: Kager triangle anterior margin length, KUAK: Kager triangle posterior margin length, KA: Kager triangle area

is above the lowest calcaneus as followed (Figure 2 and Figure 3).

The Kager fat pad was observed in front of the

calcaneal tendon and adhered to the sheath of the calcaneal tendon.

In our study, the base of the Kager's triangle was

Table 2: Analysis of the Kager triangle area by gender and side

KA				
Parameters	N	Median (Q3-Q1)	Mean (cm ²) ± Standard Deviation	P
Woman	7	6.68 (5.89-7.28)	6.74±1.15	0.013
Man	8	9.17 (7.60-9.86)	9.06±1.85	
Right side	8	8.13 (6.11-9.23)	7.85±1.70	0.784
Left Side	7	7.28 (6.54-9.23)	8.13±2.28	

Table 3: Analysis of the anterior edge, posterior edge and base of the Kager triangle by gender and side

KUOK				
Parameters	N	Median (Q3-Q1)	Mean (mm) ± Standard Deviation	P
Woman	7	69.16 (56.45-61.04)	60.10±6.56	0.536
Man	8	58.62 (48.37-84.11)	67.19±19.05	
Right side	8	57.66 (54.12-79.17)	63.83±14.25	0.694
Left Side	73	59.94 (58.17-78.38)	63.95±16.15	
KUAK				
Parameters	N	Median (Q3-Q1)	Mean (mm) ± Standard Deviation	p
Woman	7	53.06 (51.42-61.98)	55.61±6.38	0.094
Man	8	71.67 (54.71-88.74)	72.52±17.56	
Right side	8	59.65 (52.20-74.52)	62.97±13.74	0.867
Left Side	7	61.98 (51.42-89.33)	66.52±18.72	
KUT				
Parameters	N	Median (Q3-Q1)	Mean (mm) ± Standard Deviation	P
Woman	7	24.16 (23.05-26.13)	24.33±2.05	0.006
Man	8	32.50 (29.23-33.48)	31.44±3.84	
Right side	8	26.10 (23.73-33.13)	27.51±4.99	0.779
Left Side	7	28.52 (24.16-32.32)	28.82±4.76	

KUT: Kager triangle base. **KUOK:** Kager triangle anterior margin length. **KUAK:** Kager triangle posterior margin length p<0.05 was considered significant.

found to be 24.33 ± 2.05 mm in females and 31.44 ± 3.84 mm in males. The anterior margin of Kager's triangle is 60.10 ± 6.56 mm in females, 67.19 ± 19.05 mm in males, and the posterior edge of Kager's triangle is 55.61 ± 6.38 mm in females and 72.52 ± 17.56 mm in males. The area of the Kager's triangle was calculated by Heron's formula, which was used to calculate the area of the triangle with known sides. While this value was 6.74 ± 1.15 cm² in women on average, it was 9.06 ± 1.85 cm² in men. The minimum, maximum, mean and standard deviation values of the morphometric data obtained as a result of the measurements are shown in Table 1. Although there was a statistically significant difference between men and women for the base and area of the Kager's triangle, there was no statistically significant difference between men and women for the anterior and posterior sides of the Kager's triangle.

Analysis of the Kager's triangle area by gender and side is shown in Table 2, and the analysis of the anterior edge, posterior edge and base of the Kager's triangle by gender and side is shown in Table 3.

In this study, the anatomical and morphometric features of the Kager's triangle are detailed. Although Kager's fat pad is said to act predominantly as a space filler (7), there are also studies claiming a role in the force-generating capacity and prevention of tendon deformity (9). It has been assumed that the Kager fat pad helps to minimize pressure changes in

the retrocalcaneal bursa (3,10). In a study, they stated that when the extreme point of range of motion is reached in passive ankle plantar flexion and dorsiflexion, there is a significant increase in pressure both in the anterior part of the bursa and in the middle part of the fat pad (10). The area of the Kager fat pad decreases in patients with retrocalcaneal problems and in advanced ages (3). Kager's triangle appears radiolucent on radiography, but may be impaired by abnormalities such as the presence of accessory muscles, tendon ruptures, neoplasms, and inflammatory conditions (8). In addition, in pathologies such as Achilles tendinopathy occurring in the region, corticosteroid injections are preferred because of the minimal invasiveness of the steroid injection and the rapid relief of the symptoms of the disease (11). However, one of the side effects of these steroid injections is atrophy of adipose tissue (12,13). Steroid injections deeper than the peritendinous area, especially applications without imaging techniques, are injected into the Kager fat pad, and this steroid injection may have significant negative consequences due to both chemical factors and inadequate injection techniques (6). Fat pad atrophy is a serious problem in the foot as it can cause significant effects on gait due to disruption of biomechanics. Extreme ranges of motion (full plantar flexion or full dorsiflexion) should be avoided, as this may be detrimental to the Achilles or the surrounding

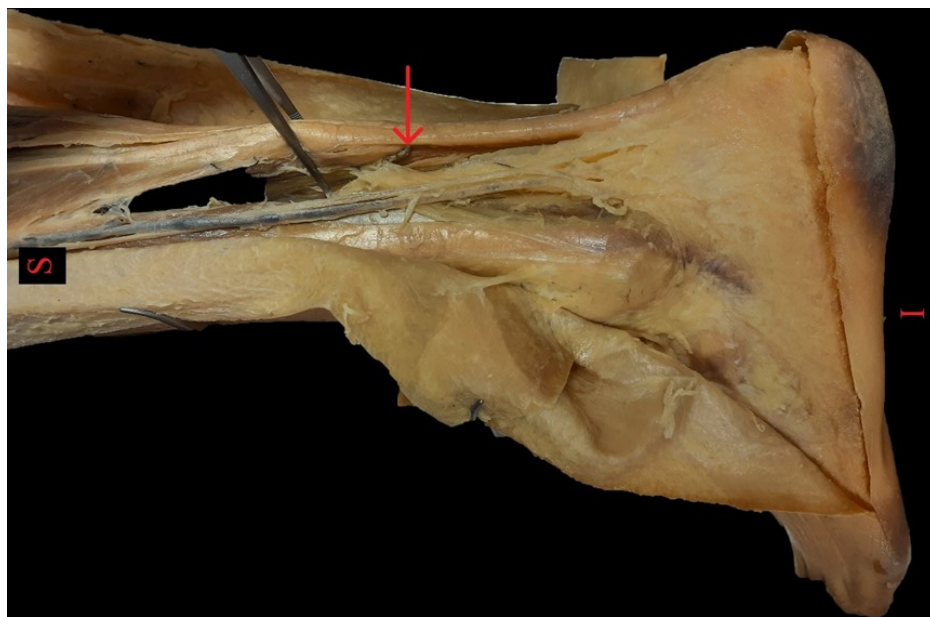


Figure 4: Vascular structures between Kager fat pad and tendon calcanei

Kager fat pad (10).

Malegelada et al. investigated the potential role of Kager fat pad pressure changes in Achilles tendinopathy in maximum ankle motion in 6 fresh frozen male cadavers and measured the anterior and posterior margin lengths of the Kager's triangle. These values were found to be 10 cm and 7 cm, respectively (10). In our study, the anterior margin of Kager's triangle was found to be 60.10 ± 6.56 mm in women and 67.19 ± 19.05 mm in men. The posterior border of Kager's triangle was found to be 55.61 ± 6.38 mm in women and 72.52 ± 17.56 in men. We think that the source of the difference with the other study is the gender of the cadavers and embalming.

In our study, the area of the Kager's triangle was calculated with the Heron formula used to calculate the area of the triangle with known sides. This value was found to be 6.74 ± 1.15 cm² in women on average and 9.06 ± 1.85 cm² in men. In the literature, 2 studies were found in which the area of the Kager's triangle was examined.

Jeon et al. radiologically evaluated the area of the Kager's triangle, the temperature of the Kager's triangle and the retrocalcaneal bursa on 20 female students aged 20-21 years, according to the height of the shoe heel. It was observed that the temperature of the Kager fat pad decreased as heel height and wearing time increased. The mean and standard deviation of the Kager's triangle area were found to be 10.62 ± 0.50 cm² in the subjects wearing sports shoes and 9.74 ± 0.29 cm² in the subjects wearing high heels. There was a decrease of approximately 0.9 cm²-1.2 cm² in the area, and a decrease in the temperature of the region by approximately 1.6°C-0.5°C, compared to those wearing sports shoes, in high-heeled shoes. The reason for this is that as the heel height increases, the calcaneal tendon contracts due to the plantar flexion of the foot and the muscle fibers become shorter and thicker. As this affects blood circulation (Figure 4), it causes a decrease in the temperature in that area. As a result of the examination of the general radiographic images, it was determined that the Kager region shrank in the

subjects wearing high heels, and the shape of the Achilles tendon and Kager's triangle changed (14).

In our study, the area of the Kager's triangle was calculated with the Heron formula used to calculate the area of the triangle with known sides. This value was found to be an average of 6.74 cm² for women and 9.06 cm² for men. The difference with the results of the study by Jeon et al. is due to the fact that our study was conducted on embalmed cadavers, and the ankles of the cadavers were fixed in planta flexion due to the effect of gravity. Plantar flexion also reduces the area of the Kager fat pad (14).

The pre-death habits of the bodies donated as cadavers are unknown. Therefore, more conclusions can be reached by comparing Kager's triangle with radiological data and age; Therefore, we think that it can generate data for rehabilitation and surgical procedures in clinics such as physical therapy and orthopedics.

4. CONCLUSION

Although it is stated that the fat pad in the Kager triangle is only for the purpose of filling the space, it supports the calcaneal tendon from the front and prevents it from bending. It increases the lubricity of the tendon and facilitates movement. Atrophy of this structure can disrupt the biomechanics of the foot and cause pain. For this reason, the boundaries and area of the Kager triangle should be taken into account in exercises that force normal joint movements in the ankle, in injection procedures and in surgical operations. This study was conducted with a limited number of cadavers. Enriching the study of Kager's triangle with radiological images and functional examinations will provide more precise information.

Acknowledgements: This study is produced from a master's thesis.

Financial Support: This research received no grant from any funding agency/sector.

Conflict of Interest: The authors declared that there is no conflict of interest.

Ethical Statement: This study is approved by the University Of Health Sciences Hamidiye Scientific Research Ethics Committee.

REFERENCES

- Lin Y jing, Duan X jun, Yang L. V-Y Tendon Plasty for Reconstruction of Chronic Achilles Tendon Rupture: A Medium-term and Long-term Follow-up. *Orthop Surg.* 2019;11(1):109-16.
- Wiegerinck JI, Somford MP, Hoornenborg D, Niek Van Dijk C. Orthopaedic forum Eponyms of the Kager Triangle. 2012;67:1-6.
- Theobald P, Bydder G, Dent C, Nokes L, Pugh N, Benjamin M. The functional anatomy of Kager's fat pad in relation to retrocalcaneal problems and other hindfoot disorders. *J Anat.* 2006;208(1):91-7.
- Apaydın N, Ünlü S, Bozkurt M, Doral MN. Aşil tendonu ' nun fonksiyonel anatomisi ve biyomekanik özellikleri Functional anatomy and biomechanical aspects of the Achilles tendon. *TOTBİD Derg.* 2011;10(1):61-8.
- Ward ER, Andersson G, Backman LJ, Gaida JE. Fat pads adjacent to tendinopathy: More than a coincidence? *Br J Sports Med.* 2016;50(24):1491-2.
- Taneja AK, Santos DCB. Steroid-induced Kager's fat pad atrophy. *Skeletal Radiol.* 2014;43(8):1161-4.
- Canoso JJ, Liu N, Traill MR, Runge VM. Physiology of the retrocalcaneal bursa. *Ann Rheum Dis.* 1988;47(11):910-2.
- Ly JQ, Bui-Mansfield LT. Anatomy of and Abnormalities Associated with Kager's Fat Pad. *Am J Roentgenol.* 2004;182(1):147-54.
- Kinugasa R, Taniguchi K, Yamamura N, Fujimiya M, Katayose M, Takagi S, et al. A Multi-modality Approach Towards Elucidation of the Mechanism for Human Achilles Tendon Bending during Passive Ankle Rotation. *Sci Rep* [Internet]. 2018;8(1):1-14. Available from: <http://dx.doi.org/10.1038/s41598-018-22661-7>
- Malagelada F, Stephen J, Dalmau-Pastor M, Masci L, Yeh M, Vega J, et al. Pressure changes in the Kager fat pad at the extremes of ankle motion suggest a potential role in Achilles tendinopathy. *Knee Surgery, Sport Traumatol Arthrosc* [Internet]. 2020;28(1):148-54. Available from: <https://doi.org/10.1007/s00167-019-05585-1>
- Humphrey J, Chan O, Crisp T, Padhiar N, Morrissey D, Twycross-Lewis R, et al. The short-term effects of high volume image guided injections in resistant non-insertional Achilles tendinopathy. *J Sci Med Sport* [Internet]. 2010;13(3):295-8. Available from: <http://dx.doi.org/10.1016/j.jsams.2009.09.007>
- Basadonna P-T, Rucco V, Gasparini D, Onorato A. Plantar Fat Pad Atrophy After Corticosteroid Injection For An Interdigital Neuroma: A Case Report: 1. *Am J Phys Med Rehabil* [Internet]. 1999;78(3). Available from: https://journals.lww.com/ajpmr/Fulltext/1999/05000/PLANTAR_FAT_PAD_ATROPHY_AFTER_CORTICOSTEROID.21.aspx
- Beyzadeoglu T, Bekler H, Gokce A. Skin and subcutaneous fat atrophy after corticosteroid injection for medial epicondylitis [Internet]. Vol. 34, *Orthopedics.* 2011 [cited 2021 Nov 21]. p. 570. Available from: https://www.researchgate.net/publication/51532144_Skin_and_Subcutaneous_Fat_Atrophy_After_Corticosteroid_Injection_for_Medial_Epicondylitis
- Jeon B, Yeo J, Shin J. 신발 굽 높이에 따른 Kager씨 삼각의 면적과 후종족부의 표면온도 측정. Measurement of Kager's Triangle Area and Retrocalcaneal Surface Temperature by shoes heel height. *J Korean Soc Radiol.* 2012;6(6):521-9.