

The Antioxidant Effects of Sesamol on Bleomycin-Induced Oral Submucous Fibrosis

Sevilay Erimsah¹ , Ayhan Cetinkaya² , Ummugul Uyeturk³ , Ugur Uyeturk⁴ , Yusufhan Yazir⁵ 

¹Department of Histology and Embryology, Faculty of Medicine, Istanbul Nisantasi University, Istanbul, Turkiye

²Department of Physiology, Faculty of Medicine, Abant Izzet Baysal University, Bolu, Turkiye

³Department of Medical Oncology, Faculty of Medicine, Abant Izzet Baysal University, Bolu, Turkiye

⁴Department of Urology, Faculty of Medicine, Abant Izzet Baysal University, Bolu, Turkiye

⁵Department of Histology and Embryology, Faculty of Medicine, Kocaeli University, Kocaeli, Turkiye

ORCID ID: S.E. 0000-0001-5400-0012; A.C. 0000-0002-8212-7149; U.U. 0000-0002-6839-2632; U.U. 0000-0002-4313-8478; Y.Y. 0000-0002-8472-0261

Cite this article as: Erimsah S, Cetinkaya A, Uyeturk U, Uyeturk U, Yazir Y. The antioxidant effects of sesamol on bleomycin-induced oral submucous fibrosis. *Experimed* 2022; 12(3): 238-42.

ABSTRACT

Objective: Oral submucous fibrosis (OSF) is a disease characterized by abnormal collagen deposition that causes inflammation and malignancy in oral mucosal tissue. Fibroblasts and myofibroblasts, are the cells that show significant activation in the development of OSF. Bleomycin (BL) is a chemotherapeutic agent commonly used in cancer treatment that also causes inflammatory changes in the oral mucosa, initiating fibrosis in the oral submucosal tissue. Sesamol (SE) has antioxidative and anti-inflammatory properties which are abundant in sesame seeds and sesame oil, and SE has a beneficial effect on the mucosal layer. This experimental study aimed to investigate SE's effects on BL-induced OSF.

Materials and Methods: The study obtained 18 healthy adult male albino rats aged 3-4 months and weighing 200-250g from Bolu Abant Izzet Baysal University's Experimental Animal Application and Research Center. The rats were divided randomly into control, BL, and BL + SE groups ($n = 6$ in each group). A model of OSF was established in the rats by administering 0.5 mg/mL of BL and 50 mg/kg of SE to the BL+SE group each day. The hematoxylin and eosin stain and Masson's trichrome stain were used to assess histopathological changes in the oral mucosa.

Results: The results revealed SE to have beneficial effects on BL-induced OSF through its antioxidant and anti-inflammatory properties. Histopathological evaluations and biochemical analysis of oral submucosal tissue samples also revealed SE to provide statistically significant protection against fibrosis in the oral mucosa ($p < 0.01$).

Conclusion: This study has demonstrated oral submucous fibrosis that develops due to BL as well as SE to have an antioxidant effect on OSF regarding BL-induced reactive oxygen species (ROS) activation and collagen synthesis.

Keywords: Oral submucous fibrosis, bleomycin, sesamol, antioxidant

INTRODUCTION

Oral submucosal fibrosis (OSF) is a disease characterized by inflammatory collagen deposition that affects human oral functionality (1). OSF is thought to be a form of collagen metabolism disorder and reduces quality of life (2). Fibroblasts and myofibroblasts are active cells that have an important role in the development of OSF (3), with the

pathogenesis of OSF having been studied in detail in recent years. Subepithelial fibrosis and hyalinization cause most of the clinical characteristic features of this condition, and while many drugs and different therapies are used to treat OSF, effective treatment is still a problem (4, 5).

Bleomycin (BL) is a chemotherapeutic agent commonly used in cancer treatment and has limited side effects

Corresponding Author: Sevilay Erimsah **E-mail:** sevilayerimsah@yahoo.com

Submitted: 27.10.2022 **Revision Requested:** 06.12.2022 **Last Revision Received:** 13.12.2022 **Accepted:** 17.12.2022 **Published Online:** 28.12.2022



Content of this journal is licensed under a Creative Commons Attribution-NonCommercial 4.0 International License.

other than pulmonary fibrosis. BL is used in studies to create an animal model of pulmonary fibrosis, scleroderma, and submucous fibrosis (6-8). In addition, BL causes inflammatory changes in tissue that result in fibrosis. Oxidative stress is also considered a cause of fibrosis through inflammatory responses and increased fibroblast activation. Oral submucous tissue is affected by chemotherapeutic agents due to rapid proliferation (5, 9). This study used BL to make an animal model for understanding the characteristics of oral submucous fibrosis.

Sesame (*Sesamum indicum* L.) has been used in Eastern countries for a long time as an anti-aging and nutritional supplement. Sesame seed oil contains sesamol, sesamin, and sesamol (SE) (10), with SE (3,4-methylenedioxyphenol) having antioxidative and anti-inflammatory effects on mucosal tissue (11, 12). SE is known to have good antioxidant activity that scavenges the hydroxyl radical due to the benzodioxol group it contains (13). A number of studies have reported SE as being a direct free radical scavenging antioxidant (14-16). SE has a protective effect on the mucosal layer in gastric ulcers caused by nonsteroidal anti-inflammatory drugs (17). SE also has antibacterial and positive antioxidant properties that reduce lipid peroxidation and free radical damage in oral tissues (12).

Studies examining quercetin, chamomile, dihydroartemisinin, leflunomide, and resveratrol for preventing fibrosis due to BL have found these substances to reduce fibrosis with their anti-inflammatory and antioxidant effects (18-21). However, the positive effect of SE on oral submucous tissue damage association with bleomycin is not yet known. The purpose of this study was to investigate SE's antioxidant effect on BL-induced oral submucous fibrosis in rats.

MATERIALS AND METHODS

The experimental study was carried out at Bolu Abant Izzet Baysal University, Experimental Animal Application and Research Center. The study used 18 healthy male Wistar albino rats aged 3-4 months and weighing 200-250g in polypropylene cages and kept them in an environment at an ambient temperature of $22\pm 2^{\circ}\text{C}$ on a 12-h light-dark cycle at a humidity level of 50-60%. Tap water was used with standard pellet feed until the day of the experiment. Rats were divided randomly into the control, BL, and BL+SE groups, ($n = 6$ in each). The control group was applied 2.5 mg/kg of saline on the first day, while the BL and BL+SE groups were applied 0.5 mg/mL of BL on the first day. For 2 h before the BL administration, saline was given to the BL group while SE (50 mg/kg/day) was given to the BL+SE group daily over a period of 10 days using an oral gavage (22). Lastly, the rats were anesthetized with ketamine (50 mg/kg), xylazine (10 mg/kg) and the blood samples were taken for biochemical parameters then rats were sacrificed by over dose anesthetics. The experimental procedures were approved by The Animal Research Ethics Committee of Bolu Abant Izzet Baysal University (Decision No. 2018/39).

For the histopathologic analysis, oral mucosal tissues from the inner surface of the lips were fixed in 10% formalin and

embedded in paraffin. Thin sections of oral tissue were taken for hematoxylin and eosin (H&E) and Masson's trichrome staining. The stained sections were assessed with a light microscope and graded histopathologically in line with the criteria from Pindborg and Sirsat's study (23): Grade 1 shows early hyalinization in the juxtaepithelial region, plump young fibroblasts, enlarged blood vessels and presence of lymphocytes (mostly mononuclear), eosinophils, and a small number of inflammatory cells in plasma cells; Grade 2 shows moderate hyalinization, less prominent fibroblasts, increased fibrocytes, narrowed vessels, and inflammatory cells; and Grade 3 shows high collagen deposition and absence of fibroblasts in the mucosal region, narrowed vessels, and inflammatory cells. A normal mucosal structure was graded as Grade 0. Histological scoring of the oral mucosa was performed by a blinded histopathologist.

For biochemical analysis, the oral mucosal tissue samples were separated into glass tubes and subsequently labeled, then the PBS-washed samples were kept at -80°C until the biochemical analysis. Next, each tissue sample was thawed and homogenized before the assay. The resulting homogenized tissues were centrifuged at 5000 g and tested for malondialdehyde (MDA) and glutathione peroxidase (GPx) concentrations as an indicator of lipid peroxidation levels. The MDA and GPx measurements were made using tissue-specific commercial kits according to protocol (Cusabio, Wuhan, China).

Statistical Analyses

The results were expressed as the mean \pm standard error of mean (SEM). The two-tailed Student's t-test was used to compare the significance of the difference between the two groups, and the one-way analysis of variance (ANOVA) test was used with Tukey's multiple comparison test to compare the data obtained from the groups. SPSS 21 was used the analysis program, with a $p < 0.05$ being considered statistically significant.

RESULTS

H&E and Masson Staining

In the histopathological examination, the epithelial layer from the control group with the normal epithelial rete ridges pattern was seen to be normal with no presence of congested or obliterated vascular changes or increased fibrosis (Figures 1A, 1D). In the BL group, the epithelial layer was thinner and the epithelial rete ridges of the oral mucosa were shorter. Also, a few inflammatory cells were found, as well as narrowing/shrinking of some vessels in the lamina propria with muscles that were atrophic in appearance. An increase of hyalinized collagen, atrophic muscle fibers, and vascular changes were also observed in the lamina propria (Figures 1B1, 1B2, 1E). In BL+SE treatment group that was applied sesamol, epithelial thinning was reduced, but inflammatory cells were still observed. A slight thin epithelial layer, mild atrophic muscle fibers, and a few vascular changes were observed in the buccal mucosa of the BL+SE group. In addition, less collagen deposition was observed in the submucosal tissue compared to the BL group (Figures 1C, 1F). The histopathologic grading

scores for the BL and BL+SE groups were assessed to be higher than in the control group ($p < 0.01$), with the BL group scores also being higher compared to the BL+SE group (Figures 1B1, 1B2, 1C, 1F). In addition, statistically significant differences were observed in all groups when compared amongst themselves ($p < 0.01$; Table 1).

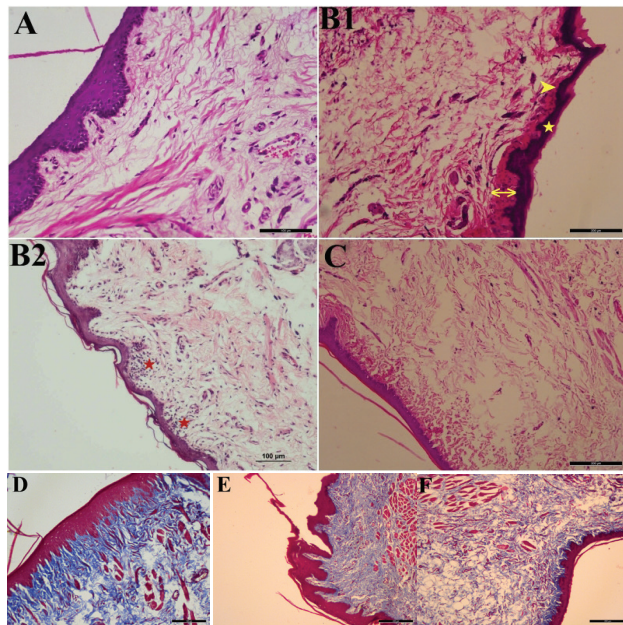


Figure 1. The oral submucosal tissues (H&E & Masson's trichrome stains). **A, D:** Control group. **B1, B2, E:** The BL group, showing a thinner epithelial layer (★), shorter epithelial rete ridges (▶), juxtaepithelial hyalinization, collagen deposition (↔), and increased inflammatory cells (★) and muscle atrophy. **C, F:** The BL+ SE group.

Table 1. Statistical analysis of the histopathologic grading scores and GPx and MDA levels of all groups.

Groups	Histopathologic Score	GPx	MDA
Control	0.264 ± 0.111	2.150 ± 0.472	0.751 ± 0.056
BL	2.564 ± 0.400*	0.393 ± 0.221*	1.523 ± 0.425*
BL+SE	1.285 ± 0.506*°	1.061 ± 0.355*°	1.043 ± 0.110*°

* $p < 0.01$ compared to the control group
° $p < 0.01$ compared to the BL group

Biochemical Analysis

Lipid peroxidation in the BL-treated rats' mucosal tissue were quantified by evaluating their MDA levels. The MDA levels of both the BL and BL+SE groups were found to be significantly

higher than the control group, which indicates increased oxidative stress in the oral mucosa ($p < 0.01$). However, when comparing the BL group to the BL+SE group, a significant difference was seen between them, with the MDA levels being found significantly lower in the SE treatment group (BL+SE; $p < 0.01$).

GPx catalyzes hydrogen peroxide and hydroperoxide reduction to form non-toxic products, and this was also measured to be higher in the control group than in the BL and BL+SE groups ($p < 0.01$). Also, GPx was found to be significantly lower in the BL group when compared to the BL+SE group ($p < 0.01$). The GPx levels from the oral submucosal tissue samples showed SE to have provided statistically significant protection against fibrosis ($p < 0.01$; Table 1; Figure 2).

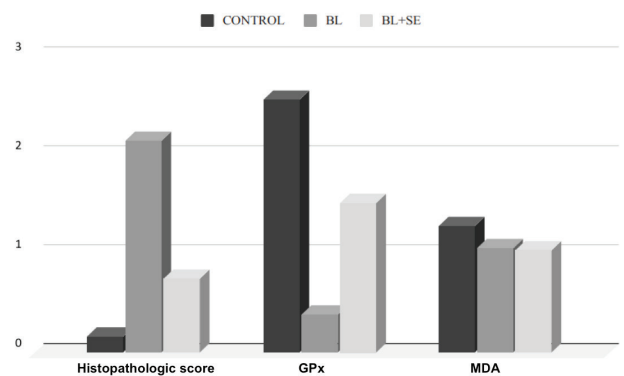


Figure 2. Histopathologic score of BL group were found to be significantly higher than the control group and BL+SE group. The MDA and GPx levels of BL, BL+SE and the control groups; the graphic indicates increased oxidative stress in the oral mucosa and also, decreased GPx level in the BL-treated group compared to other groups ($P < 0.01$). BL, Bleomycin; BL+SE, Bleomycin+Sesamol, GPx: Glutation peroxidase; MDA: Malondialdehyde.

DISCUSSION

The present study has provided data regarding SE's protective effect against BL-induced submucosal damage in rats. BL is one of the drugs used in the chemotherapy treatment of many types of tumors. In addition to complications such as immuno-suppression and hematopoietic toxicity due to BL, BL chemotherapy often causes pulmonary fibrosis (24). Therefore, BL has been widely used in developing animal models of pulmonary fibrosis (25). Repetitive administration of BL injections also induces pleural submucosal fibrosis (9). The current study created oral submucosal fibrosis to appear in BL-treated rats, similar to the human OSF pathology. This model allowed the study to examine SE's antioxidant effects on oral submucosal fibrosis. The treated rats were observed to have atrophic epithelial layers, hyalinization just below the epithelial layer, concentrations of collagen fibrils, and increased inflammatory cell counts. The increased collagen in the oral mucosa is the most distinguishing feature of OSF (26). Lamina

propria enlargement with connective tissue was also observed, similar to OSF. The rats in whose mucosal tissue the study wanted to create fibrosis were also observed to have atrophic epithelial layers, juxtaepithelial hyalinization, deposition of collagen fibrils, and some inflammatory cell infiltration (27).

This study reduced the development of fibrosis with the SE treatment, which was quantified by the histopathologic changes in the submucosal layer. The histopathologic evaluations showed the fibroblasts to have become active in the lamina propria of the oral mucosa of the BL-treated rats due to the deposition of a large amount of collagen fibers. In addition, the atrophic epithelial cells, epithelial hyalinization, and inflammatory cell infiltration in the BL-treated groups resembled OSF (26, 28). However, less atrophic epithelial cells and inflammatory cells in the lamina propria were observed in this study.

SE attenuated OSF in the BL-treated submucosa. SE was also found to be effective at reducing mucosal lipid peroxidation and hydroxyl radical levels. In addition, SE significantly maintained the reduced mucosal glutathione levels in the submucosal tissue of the BL-treated rats. Therefore, SE may be able to protect the submucosa against BL-induced injury by inhibiting lipid peroxidation (29). In the current study, SE played an excellent role in protecting the oral mucosal tissue from oxidative damage, with the histopathological results supporting with the biochemical findings.

Therefore, this study indicates SE to be able to reduce mucosal fibrosis and to ameliorate OSF with its antioxidant effects on BL-induced OSF rats.

CONCLUSION

The results showed BL to cause an increase in fibrosis in the oral submucosal tissue and SE to have potent antioxidative and anti-inflammatory properties on BL-induced apoptosis and ROS accumulation. This study has also shown SE to have an antioxidant effect on oral submucosal fibrosis and to inhibit BL-induced ROS activation and collagen synthesis. Due to the results obtained from the study on rats, SE may be an alternative approach to clinical antioxidant treatments for OSF patients.

Note: This study was presented orally at the 2nd International Health Sciences and Life Congress on April 24-27, 2019 in Istanbul.

Ethics Committee Approval: The experimental procedures were approved by The Animal Research Ethics Committee of Bolu Abant İzzet Baysal University (Decision No. 2018/39).

Peer-review: Externally peer-reviewed.

Author Contributions: Conception/Design of Study - S.E., U.U.; Data Acquisition - S.E.; Data Analysis/Interpretation - S.E.; Drafting Manuscript - Ü.U., U.U.; Critical Revision of Manuscript - S.E.; Final Approval and Accountability - A.C., Y.Y., S.E.

Conflicts of Interest: The authors declare no conflict of interest.

Financial Disclosure: The authors declare that this study has received no financial support.

REFERENCES

1. World Health Organization; International Agency for Research on Cancer. IARC monograph on the evaluation of carcinogenic risks to humans, betel-quid and areca-nut chewing and some areca-nut-derived nitrosamines. Vol. 85. Lyon, France: IARC; 2004.
2. Arakeri G, Brennan PA. Oral submucous fibrosis: An overview of the aetiology, pathogenesis, classification, and principles of management. *Br J Oral Maxillofac Surg* 2013; 51: 587-93. [\[CrossRef\]](#)
3. Angadi PV, Kale AD, Hallikerimath S. Evaluation of myofibroblasts in oral submucous fibrosis: correlation with disease severity. *J Oral Pathol Med* 2011; 40: 208-13. [\[CrossRef\]](#)
4. Kerr AR, Warnakulasuriya S, Mighell AJ, T Dietrich, M Nasser, J Rimal, et al. A systematic review of medical interventions for oral submucous fibrosis and future research opportunities. *Oral Dis* 2011; 17: 42-57. [\[CrossRef\]](#)
5. Jiang XW, Zhang Y, Yang SK, Zhang H, Lu K, Sun GL. Efficacy of salvianolic acid B combined with triamcinolone acetonide in the treatment of oral submucous fibrosis. *Oral Surg Oral Med Oral Pathol Oral Radiol* 2013; 115: 339-44. [\[CrossRef\]](#)
6. Chua F, Gauldie J, Laurent GJ. Pulmonary fibrosis: Searching for model answers. *Am J Respir Cell Mol Biol* 2005; 33: 9-13. [\[CrossRef\]](#)
7. Yamamoto T, Takagawa S, Katayama I, Yamazaki K, Hamazaki Y, Shinkai H, et al. Animal model of sclerotic skin. I: Local injections of bleomycin induce sclerotic skin mimicking scleroderma. *J Invest Dermatol* 1999; 112: 456-62. [\[CrossRef\]](#)
- 8-9. Zhang SS, Gong ZJ, Xiong W, Wang X, Min Q, Luo CD, et al. A rat model of oral submucous fibrosis induced by bleomycin. *Oral Surg Oral Med Oral Pathol Oral Radiol* 2016; 122(2): 216-23. [\[CrossRef\]](#)
- 9-10. Kabel AM, Omar MS, Elmaaboud MAA. Amelioration of bleomycin-induced lung fibrosis in rats by valproic acid and butyrate: Role of nuclear factor kappa-B, proinflammatory cytokines and oxidative stress. *Int Immunopharmacol* 2016; 39: 335-42. [\[CrossRef\]](#)
10. Jan KC, Ho CT, Hwang LS. Bioavailability and tissue distribution of sesamol in rat. *J Agric Food Chem* 2008; 56(16): 7032-7. [\[CrossRef\]](#)
11. Hsu DZ, Chen KT, Li YH, Chuang YC, Liu MY. Sesamol delays mortality and attenuates hepatic injury after cecal ligation and puncture in rats: role of oxidative stress. *Shock*. 2006; 25(5): 528-32. [\[CrossRef\]](#)
12. Hsu DZ, Chen YW, Chu PY, Periasamy S, Liu MY. Protective effect of 3,4-methylenedioxyphenol (sesamol) on stress-related mucosal disease in rats. *Biomed Res Int* 2013; 2013: 481827.
13. Kumagai Y, Lin LY, Schmitz DA, Cho AK. Hydroxyl radical mediated demethylation of (methylenedioxy) phenyl compounds. *Chem Res Toxicol* 1991; 4: 330-4. [\[CrossRef\]](#)
14. Kanimozhi P, Prasad NR. Antioxidant potential of sesamol and its role on radiation-induced DNA damage in whole-body irradiated Swiss albino mice. *Environ Toxicol Pharmacol* 2009; 28: 192-7. [\[CrossRef\]](#)
15. Prasad NR, Menon VP, Vasudev V, Pugalendi KV. Radioprotective effect of sesamol on gamma-radiation induced DNA damage, lipid peroxidation and antioxidants levels in cultured human lymphocytes. *Toxicology* 2005; 209: 225-35. [\[CrossRef\]](#)
16. Wu MS, Aquino LBB, Barbaza MYU, Hsieh CL, Castro-Cruz KA, Yang LL, et al. Anti-inflammatory and anticancer properties of bioactive compounds from *Sesamum indicum* L.-A Review. *Molecules* 2019; 24(24): 4426. [\[CrossRef\]](#)

17. Hsu D-Z, Chu P-Y, Li Y-H, Liu M-Y. Sesamol attenuates diclofenac-induced acute gastric mucosal injury via its cyclooxygenase-independent antioxidative effect in rats. *Shock* 2008; 30(4): 456-62. [\[CrossRef\]](#)
18. Zargar HR, Hemmati AA, Ghafourian M, Arzi A, Rezaie A, Javad-Moosavi SA. Long-term treatment with royal jelly improves bleomycin-induced pulmonary fibrosis in rats. *Can J Physiol Pharmacol* 2017; 95(1): 23-31. [\[CrossRef\]](#)
19. Javadi I, Emami S. The antioxidative effect of chamomile, anthocyanoside and their combination on bleomycin-induced pulmonary fibrosis in rat. *Med Arch* 2015; 69(4): 229-31. [\[CrossRef\]](#)
20. Yang D, Yuan W, Lv C, Li N, Liu T, Wang L, et al. Dihydroartemisinin suppresses inflammation and fibrosis in bleomycine-induced pulmonary fibrosis in rats. *Int J Clin Exp Pathol* 2015; 8(2): 1270-81.
21. Akgedik R, Akgedik S, Karamanli H, Uysal S, Bozkurt B, Ozol D, et al. Effect of resveratrol on treatment of bleomycin-induced pulmonary fibrosis in rats. *Inflammation* 2012; 35(5): 1732-41. [\[CrossRef\]](#)
22. Jan KC, Ho CT, Hwang LS. Elimination and metabolism of sesamol, a bioactive compound in sesame oil, in rats. *Mol Nutr Food Res* 2009; 53(1): 36-43. [\[CrossRef\]](#)
23. Shruthi P, Ajay KC, Mamta S, Mangal S, Ravi M. Correlation of histopathological diagnosis with habits and clinical findings in oral submucous fibrosis. *Head Neck Oncol* 2009; 1-10. [\[CrossRef\]](#)
24. Kawai K, Akaza H. Bleomycin-induced pulmonary toxicity in chemotherapy for testicular cancer. *Expert Opin Drug Saf* 2003; 2(6): 587-96. [\[CrossRef\]](#)
25. Lee WJ, Lee SM, Won CH, Chang SE, Lee MW, Choi JH, et al. Efficacy of intralesional bleomycin for the treatment of plantar hard corns. *Int J Dermatol* 2014; 53(12): 572-7. [\[CrossRef\]](#)
26. Utsunomiya H, Tilakaratne WM, Oshiro K, Satoshi Maruyama, Makoto Suzuki, Hiroko Ida-Yonemochi, et al. Extracellular matrix remodeling in oral submucous fibrosis: its stage-specific modes revealed by immunohistochemistry and in situ hybridization. *J Oral Pathol Med* 2005; 34: 498-507. [\[CrossRef\]](#)
27. Dai JP, Chen XX, Zhu DX, Wan QY, Chen C, Wang GF, et al. Panax notoginseng saponins inhibit areca nut extract induced oral submucous fibrosis in vitro. *J Oral Pathol Med* 2014; 43(6): 464-70. [\[CrossRef\]](#)
28. Jiang L, Deng Y, Li W, Lu Y. Arctigenin suppresses fibroblast activity and extracellular matrix deposition in hypertrophic scarring by reducing inflammation and oxidative stress. *Mol Med Rep* 2020; 22(6): 4783-91. [\[CrossRef\]](#)
29. Andargie M, Vinas M, Rathgeb A, Möller E, Karlovsky P. Lignans of Sesame (*Sesamum indicum* L.): A Comprehensive Review. *Molecules* 2021; 26(4): 883. [\[CrossRef\]](#)