

## SEVERE HYPODONTIA: FOUR CASE REPORTS AND REVIEW OF THE LITERATURE

## ŞİDDETLİ HİPODONTİ: DÖRT VAKA RAPORU ve LİTERATÜRÜN ARAŞTIRILMASI

Arş. Gr. Dt. M. Akif SÜMBÜLLÜ\*

Arş. Gr. Dt. Özkan MİLOĞLU\*

### ABSTRACT

Missing teeth can be a local condition or part of a generalized condition. As an example of the latter, oligodontia (partial absence of teeth) very often associated with ectodermal dysplasia. Missing teeth can range from a single to anodontia (complete absence of teeth). Third molars are most frequently missing teeth and are followed in order by mandibular second premolars, maxillary lateral incisors, and maxillary second premolars. Both environmental and genetic factors can cause failure of tooth development but in the majority of cases, hypodontia has genetic bases. An isolated hypodontia is inherited as an autosomal dominant. In this report, our aim is to demonstrate the severe hypodontia that exists in four cases. In order to prevent aesthetic and functional problems in dentition, the early diagnosis of hypodontia should be performed at the right time.

**Keywords:** Severe hypodontia; Tooth development; Radiograph; Dental abnormalities

### ÖZET

*Diş kaybı, vücudun genelini etkileyen bir durumun parçası veya lokal bir durum olabilir. Vücudun genelini etkileyen bir durum olarak oligodonti (dişlerin kısmi kaybı), ektodermal displazi ile birlikte görülebilir. Diş kaybı; tek bir diş kaybı, birkaç dişin kaybı veya anodonti (tüm dişlerin kaybı) şeklinde olabilir. 3. molarlar eksikliği en sık görülen durum olup, onu sırasıyla mandibular 2. molarlar, maksiller lateral kesiciler ve maksiler 2. premolar dişler takip eder. Hem çevresel hem de genetik faktörler diş gelişiminde bozukluğun oluşmasına sebep olabilir. Fakat vakaların çoğunda diş eksikliği genetik kökenlidir. İzole hipodonti, otozomal dominant geçişli kalıtsal bir durumdur.*

*Bu yazıda şiddetli hipodontinin (oligodonti) mevcut olduğu 4 olgu sunulmaktadır. Hipodontinin erken tanısı olası estetik ve fonksiyonel problemlerin önlenmesi açısından önemlidir.*

**Anahtar Kelimeler:** Şiddetli hipodonti; Diş gelişimi; Radyografi; Diş anomalisi

### INTRODUCTION

Tooth development is a complex process, in which Reciprocal and sequential interactions between epithelial and mesenchymal cells regulate cell activities like proliferation, condensation, adhesion, migration, differentiation and secretion.<sup>1</sup> These lead to the formation of a functional tooth organ. Tooth agenesis are the most common type of craniofacial malformations. Agenesis of at least one tooth is the most common anomaly of dental development. Tooth agenesis may range from the absence of one or a few teeth to the failure of all teeth to develop. Many of the genes who have a role in tooth development also have important functions in the development of other organs.<sup>2</sup>

### CASE REPORTS

Because of complaints of toothaches, aesthetic and functional problems, four patients (two female, two male) applied to the department of Oral Diagnosis and Radiology Clinic at the Faculty of Dentistry at Atatürk University. In their clinical and radiographic examination, we determined more missing teeth. In their history, a systemic disease or syndrome was not determined. Severe hypodontia was found in these four patients. Of which two are girl (Case 1, 15 years old and Case 2, 13 years old), and two are boys (Case 3, 19 years old and Case 4, 11 years old).

In the case 1, except for the third molars, 19 permanent tooth are absent. The missing tooth

\* Atatürk Üniversitesi Oral Diagnoz ve Radyoloji Anabilim Dalı

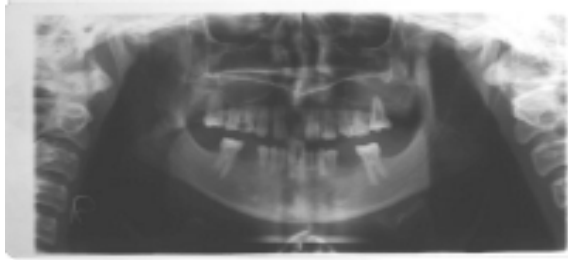
numbers are 12,13,14,15,17,22,24,25,27,31,32,33,35,37,41,42,43,45,47 (fig. 1).

In the case 2, except for the third molars again, 14 permanent tooth are absent. The missing tooth numbers are 12,15,17,22,25,27,31,34,37,41,42,43,45,47 (fig. 2).

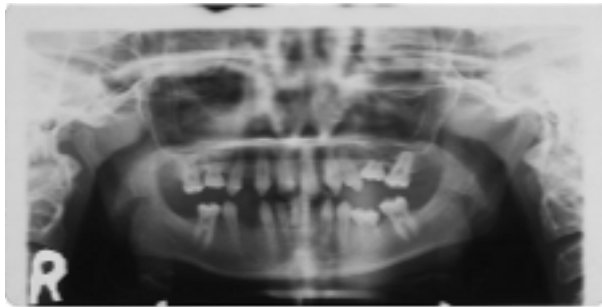
In the case 3., except again for the third molars, 11 permanent tooth are absent. The missing tooth numbers are 12,13,14,15,17,22,27,32,35,37,47 (fig. 3).

In the case 4, except for the third molars, 12 permanent tooth are absent. The missing tooth numbers are 12,14,15,22,24,25,31,32,36,41,42,44 (fig. 4).

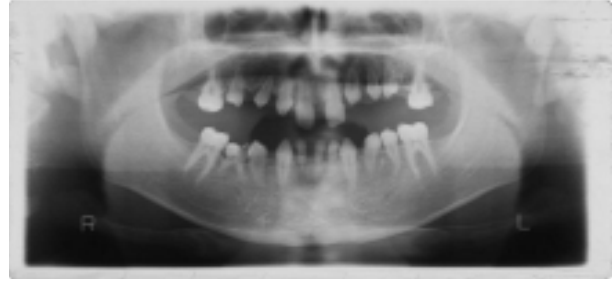The teeth that were present had malposition along with polidistema, and were carious, and had aesthetic and functional problems in each of the cases.



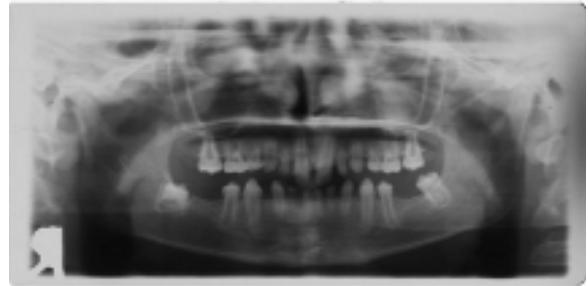**Figure 1** Panoramic radiography of Case 1, 19 permanent teeth are absent.



**Figure 2** Panoramic radiography of Case 2, 14 permanent teeth are absent.



**Figure 3** Panoramic radiography of Case 3, 11 permanent teeth are absent.



**Figure 4** Panoramic radiography of Case 4, 12 permanent teeth are absent.

## DISCUSSION

A tooth may be considered to be developmentally missing when it cannot be discerned clinically or radiographically and no history exists of its extraction.<sup>3</sup> Hypodontia/oligodontia that may result in significant psychological, dental, aesthetic and functional problems is classified as isolated or non-syndromic, where as hypodontia/oligodontia and syndromic hypodontia/oligodontia or hypodontia/oligodontia are associated with syndromes. Dhanrajani<sup>4</sup> classified hypodontia according to the severe of the condition. The term "mild-to-moderate hypodontia" is used to denote agenesis of two to five teeth, while the absence of six or more teeth, excluding the third molars, indicates "severe hypodontia". Oligodontia is the absence of multiple teeth, usually associated with systemic disorders.

In the cases, lack of one or a few permanent teeth excluding the third molars without any systemic disorders was found. Thus, congenital lack of one or more permanent teeth without any systemic disorders or syndrome was suggested isolated or nonsyndromic hypodontia.

Missing teeth are common trait in modern populations and it is often encountered by dental practitioners.<sup>5</sup> Missing teeth are recognized by identifying and counting the existing teeth. However, it must be kept in mind that the development of teeth may vary markedly among patients. Eruptions of some teeth may be developmentally delayed by a number of years after the established time and others may show evidence of development as late as a year after the contralateral tooth.<sup>6</sup>

The panoramic radiography together with clinical examination of the hypodontia is recommended for the detection or confirmation of dental development and performing the diagnosis.<sup>7</sup>

In a survey conducted by Muller et al, found that girls had a higher rate of congenitally missing permanent teeth than boys.<sup>8</sup> Numerous studies have appeared on the prevalence of hypodontia in different countries, showing some variation in populations, on continents and among races. Family studies have shown the frequency of hypodontia and peg-shaped lateral incisor(s) in parents and sibs of the probands to be significantly higher than in the general population. The prevalence of permanent tooth agenesis ranges between 1.6% and 9.6%, and the prevalence of deciduous tooth agenesis is lower, ranging between 0.5 % and 0.9 %.<sup>9</sup>

Missing teeth may be the result of numerous independent pathologic mechanisms that can affect the orderly formation of the dental lamina, failure of a tooth germ to develop at the optimal time, multiagent chemotherapy, radiation therapy, fractures, surgical procedures on the jaws, extraction of the preceding primary teeth, lack of necessary space imposed by a malformed jaw, and a genetically determined disproportion tooth mass and jaw size.

Although tooth agenesis is occasionally caused by environmental factors, in the majority of cases hypodontia has a genetic basis. In familial hypodontia, the type of inheritance in the majority of families seems to be autosomal dominant with incomplete penetration and variable expressivity. An autosomal recessive model of inheritance is also possible. Mutations in transcription factors MSX1 and PAX9 have been identified in families with an autosomal dominant oligodontia. Oligodontia, like hypodontia is seen as an isolated trait or as a part of a syndrome. Isolated oligodontia is inherited in an autosomal dominant form with reduced penetration.<sup>10</sup>

Hypodontia is associated with incomplete development of almost all teeth, malformation of crowns, lack of root development, enamel hypoplasia and failure of eruption.<sup>11</sup> Examples of these are delayed formation and eruption of teeth, reduction in tooth size and form, malposition of teeth (ectopic maxillary canines and ectopic eruption of other teeth), infraposition of primary molars, teeth with short roots, taurodontism, rotation of premolars and/or maxillary lateral incisors, enamel hypoplasia, hypocalcification and dentinogenesis imperfecta.<sup>12</sup>

In case studies the remaining teeth had malposition, poldiestema and malformation. No definite etiologic relationship has been found between hypodontia and systemic diseases or endocrine disturbances. In this anomaly, the most affected teeth are the third molars, followed by lateral maxillary incisors or second mandibular premolars.

Dental manifestations are seen in several syndromes together with malformations of other organs. Some of the best known of these syndromes are isolated cleft lip/palate, Pierre Robin sequence, Van der Woude syndrome, MSX1 mutation, hypohidrotic ectodermal dysplasia (EDA or HED), Ectrodactyly-ectodermal dysplasia-clefting syndrome (EEC), Cleft lip palate ectodermal dysplasia syndrome (CLPED1), incontinentia pigmenti (IP, Bloch-Sulzberger Syndrome), Hypohidrotic ectodermal dysplasia and immune deficiency (HED-ID), Oral facial digital syndrome type I (OFD1), Witkop tooth-nail syndrome, Fried syndrome, Böök syndrome (PHC), Hair- nail- skin- teeth dysplasias, Rieger syndrome, Holoprosen cephal, Down's syndrome (trisomi 21), Wolf- Hirschhorn syndrome (deletion 4p), Kabuki syndrome, Diastrophic dysplasia (DTD), Hemifacial microsomia and Recessive incisor hypodontia (RIH).<sup>13</sup>

In conclusion, missing teeth together with abnormal occlusions or altered facial appearance may cause psychological distress some patients. Thus, the early diagnosis of these patients becomes more important.

## REFERENCES

1. Jernvall J, Thesleff I. Reiterative signalling and patterning during mammalian tooth morphogenesis. *Mech Dev* 2000; 92: 19-29.
2. Jumlongras D, Bei M, Stimson JM, Wang WF, DePalma SR, Seidman CE, et al. A nonsense mutation in *MSX1* causes Witkop Syndrome. *Am J Hum Genet* 2001; 9: 743-746.
3. Schalk-Van Der Weide Y, Bosman F. Tooth size in relatives of individuals with oligodontia. *Arch Oral Biol* 1996; 41: 469-472.
4. Dhanrajani PJ. Hypodontia: etiology, clinical features and management. *Quintessence Int* 2002; 33: 294-302.
5. Jorgenson RJ. Clinician's view of hypodontia. *JADA* 1980; 101: 283-286.
6. Pirinen S, Thesleff I. Development of the dentition. In: Thilander B, Rönning O (eds). *Introduction to Orthodontics*. Stockholm, 1995: 41-43.
7. Kırzioğlu Z, Köşeler ŞT, Ertürk MSÖ, Karayılmaz H. Clinical features of hypodontia and associated dental anomalies: a retrospective study. *Oral Diseases* 2005; 11: 399-404.
8. Muller TP, Hill IN, Petreson AC, Blayney JR. A survey of congenitally missing permanent teeth. *J Am Dent Assoc* 1970; 81: 101-107.
9. Zarrinnia K, Bassiouny MA. Combined aplasia of maxillary first molars and lateral incisors: a case report and management. *J Clin Pediatr Dent* 2003; 27: 127-132.
10. Vastardis H, Karimbux N, Guthua SW, Seidman JG, Seidman CE. A human *MSX 1* homeodomain missense mutation causes selective tooth agenesis. *Nat Genet* 1996; 13: 417-421.
11. Schalk-van der Weide Y. Oligodontia. A clinical, radiographic and genetic evaluation. Thesis. Utrecht, University of Utrecht, 1992.
12. Ahmad W, Brancolini V, ul Faiyaz MF, Lam H, ul Haque S, Haider M et al. A locus for autosomal recessive hypodontia with associated dental anomalies maps to chromosome 16q12.1. *Am J Hum Genet* 1998; 62: 987-991.
13. Pirinen S, Kentala A, Nieminen P, Varilo T, Thesleff I, Arte S. Recessively inherited lower incisor hypodontia. *J Med Genet* 2001; 38: 551-556.

**Corresponding author:** M. Akif SÜMBÜLLÜ ,  
DDS PhD

Address: Department of Oral Diagnosis and Oral  
Radiology,

Faculty of Dentistry, Atatürk University,  
Erzurum, Turkey

Business telephone number: 0090.442.2311765

Fax number: 0090.442.2360945

E-mail address: [masumbullu@yahoo.com](mailto:masumbullu@yahoo.com)

**Yazışma Adresi**