

## THE RELATION OF THE OCCLUSAL PLANE AND RETROMOLAR PAD\*

Prof. Dr. Zeynep YEŞİL DUYMUŞ\*\*

Prof. Dr. M. Üstün GÜLDAĞ\*\*

Prof. Dr. Nuran DİNÇKAL YANIKOĞLU\*\*

### ÖZET

Tam protez yapımında, oklüzal düzlemin doğru pozisyonlandırılması protezin uygun olarak fonksiyon görmesi için esastır. Dişlerin uygun oklüzal düzleme göre dizilmesi avantaj sağlar.

Bu çalışmada, retromolar papil ve oklüzal düzlem ilişkisi değerlendirilmiştir. Bu amaçla, yaşları 18-28 arasında değişen 22 bayan, 28 erkek hastanın alt çenesinden irreversible hidrokoloid ölçü maddesi ile alınan ölçülere alçı dökülerek modeller elde edildi. Molar bölgede, oklüzal düzlemin yüksekliğinin izdüşümü ile retromolar papilin yüksekliği arasındaki fark ölçüldü.

Bu fark erkeklerde sağ taraf için ortalama 4.20 mm, sol taraf için 4.04 mm, bayanlarda sağ taraf için 3.88 mm, sol taraf için 3.70 mm olarak bulundu.

Sonuç olarak, 4 mm' lik ortalama retromolar papil yüksekliği oklüzal düzlemin tespitinde uygun referans olarak önerilebilir.

**Anahtar Kelimeler:** Retromolar papil, oklüzal plan.

### ABSTRACT

In the construction of complete dentures the accurate positioning of the occlusal plane is essential for appropriate denture function. The positioning of the teeth according to the proper occlusal plane provides a considerable advantage in fabricating prosthetic appliance. In this study the relation of the occlusal plane and retromolar pad were evaluated. For this purpose mandibular irreversible hydrocolloid impression (total of 50 patients, 22 female and 28 male, at the ages of between 18-28 years old) were made and poured with dental stone. The measurements were made to determine the distance between retromolar pad and the projection of the height of the occlusal plane in the molar area.

This study showed that the mean distance was 4.20 mm for the right side and 4.04 mm for the left side in male, 3.88 mm for the right side and 3.70 mm for the left side in female. The results of this study suggest that a mean vertical height of 4 mm at retromolar pad could be recommended as a suitable reference in determining of the occlusal plane.

**Key Words :** Retromolar pad, occlusal plane.

\* : Presented as a poster at the 24th Annual Conference of the European Prosthodontic Association, Groningen, Netherlands, 23-26 August 2000.

\*\* Atatürk University, School of Dentistry, Prosthodontics Department, Erzurum, Turkey

## INTRODUCTION

The occlusal plane is an imaginary surface which is anatomically related to the cranium and which theoretically touches the incisal edges of the incisors and the tips of the occluding surfaces of posterior teeth.<sup>1</sup> In the Glossary of Prosthodontic Terms, the occlusal plane is defined as the surface of wax occlusion rims contoured to guide the arrangement of denture teeth.<sup>2</sup>

There exists general agreement that in the fabrication of complete dentures the accurate positioning of the occlusal plane is essential for appropriate denture function.<sup>3</sup> The positioning of the teeth according to the proper occlusal plane provides a considerable advantage in fabricating prosthetic appliances and contributes to optimal appearance and function for patients with complete or partial loss of their teeth.<sup>4-6</sup>

Review of the literature, revealed a wide variety of landmarks and techniques advocated by various authorities.<sup>4,7-9</sup> Many dentists use a technique wherein the occlusal plane established on the maxillary occlusion rim so that the incisal plane is parallel with the interpupillary line and at a height that allows for the length of the natural tooth, plus the amount of tissue resorption that has occurred.<sup>10</sup>

The sagittal (antero-posterior) aspect of the artificial occlusion has been discussed in several studies.<sup>3,4,7</sup> Although it has been common practice to set this sagittal plane parallel to the ala-tragus line (Camper's line) for complete dentures.<sup>3,10-12</sup> This practice is used to orient the occlusal plane controversially.<sup>11-14</sup> This controversy is primarily due to disagreement on the definite points of reference for this line. Therefore, the modified method whereby the end of occlusal plane is determined according to the

position of the retromolar pad is proposed in some guidelines.<sup>3,10</sup> For both anatomical and mechanical reasons, Mack<sup>3</sup> preferred the use of the mandibular rather than the maxillary record rim as the clinical determinant for the artificial occlusion. İsmail and Bowman<sup>15</sup> suggest terminating the occlusal plane posteriorly at the middle or upper third of the retromolar pad.

In the Glossary of Prosthodontic Terms,<sup>2</sup> the retromolar pad is defined as a mass of tissue composed of nonkeratinized mucosa located posterior to the retromolar pad and overlying loose glandular connective tissue.

The aim of this study was to evaluate the relation between the occlusal plane and retromolar pad.

## MATERIALS AND METHODS

Our study was carried out on total of 50 patients, 22 female and 28 male, at the ages of between 18-28 years old.

In the choice of the cases: Study criteria was as following :

- a- All the teeth, except third molar teeth should be available in the mouth,
- b-They should show neutral occlusion.

Evaluation was made on the casts prepared with type IV dental stone (Bego Bremer Goldschlagerei Wilh, Herbst GmbH & co. Emil sommer, Bremen) from mandibular impression obtained by hydrocolloid impression material (Alginoplast;Heraeus Kulzer, Holland) (Fig1).

Casts were fixed to the surveyor (The JM Ney Company Connecticut, USA), and the occlusal plane was adjusted so that it is parallel to the base of the surveyor. The analyzing rod of the surveyor was adjusted to the top point of buccal-median tubercle of the lower first molar teeth. Its projection was marked in retromolar

region without changing this height, and the distance between retromolar pad and this point was measured and recorded (Fig 2). Measurements were repeated by two clinicians and the mean for each cast was obtained for statistical analysis.

Analysis of Covariance and independent sample t test were used for biometric evaluation, and standart deviations were determined.

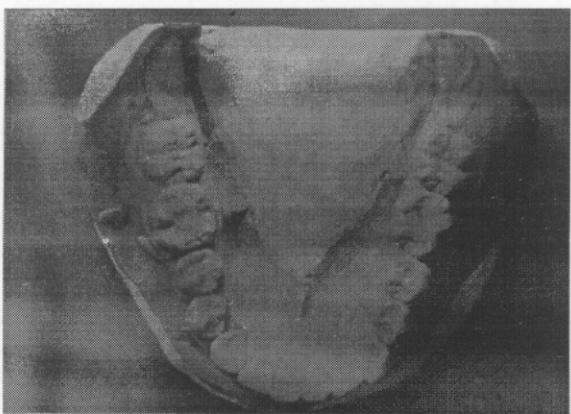


Figure 1. Occlusal view of the retromolar pad and mandibular teeth.




Figure 2. Measurement the distance between retromolar pad and tip of the bucco-median tubercle of the lower first molar teeth.

## RESULTS

The results of mean, standart deviation obtained in right and left side according to the sex are shown in Table 1.

Table 1 .Mean values of the distance between the occlusal plane and retromolar pad for the right and left side

Sex	Mean Distance (mm)	Range (mm)	SD
Right Side	Male 4.20	3.5-5.0	0.08
	Female 3.88	3.0-4.5	0.09
Left Side	Male 4.04	3.0-5.0	0.10
	Female 3.70	3.0-4.5	0.11

The mean distance was 4.20 mm for the right side and 4.04 mm for the left side in male, 3.88 mm for the right side and 3.70 mm for the left side in female. It was no statistically significant differences between right and left side.

According to the results of group comparison carried out for determination whether there was a distinction between the sexes in the right and left mandible. The age factor was not statistically significant ( $P>0.05$ ). It was statistically found that sex factor in right and left side became significant ( $P<0.01$ ).

## DISCUSSION

A cephalometric study compared to the occlusal plane in dentulous and edentulous subjects showed that the reliability of Camper's Line (Ala-tragus line) as a guideline to simulate the occlusal plane is questionable.<sup>13</sup> The plane that is used as a guide in the orientation of the chewing plane and that is accepted almost all around the world is "Camper plane".<sup>8</sup>

The cephalometric lateral radiographs were taken so as to compare the location of occlusal plane in dentulous patients. These radiographs were then compared with the complete dentures.<sup>15</sup>

Nissan et al.<sup>16</sup> suggested that cephalometric analysis alone cannot determine the location of the occlusal plane in edentulous patients. Intra-oral structures should also be considered.

According to D'Souza and Bhargava's<sup>13</sup> study the edentulous occlusal and maxillary plane angle was higher than the dentulous occlusal and maxillary plane angle. On the other hand, Niekerk et al,<sup>11</sup> stated that ala-tragus line has a close relationship with the occlusal plane and could be used as a landmark when the maxillary occlusion rim is trimmed to the occlusal plane.

In this study, the relation of the occlusal plane and retromolar pad were evaluated. The results of the study shows that the mean distance was 4.20 mm for the right side and 4.04 mm for the left side in male, 3.88 mm for the right side and 3.70 mm for the left side in female. The difference between men and women is statistically significant ( $P<0.05$ ).

Ogawa et al.<sup>17</sup> investigated the relationship between the inclination of the occlusal plane and jaw closing movement path in the sagittal plane. They found that the occlusal plane and the masticatory closing path were consistent in maintaining an almost perpendicular relationship regardless of the variation in the inclination of the occlusal plane. Because of the controversy in the ala-tragus line, it would therefore appear sensitive to use the retromolar pad as an indicator of the posterior extension of the occlusal plane.

Ogawa et al.<sup>17</sup> found out that it is a significant correlation between the inclination of

the occlusal plane and the direction of the closing path during mastication.

Celebic et al.<sup>18</sup> stated that the intra-oral method which orients the occlusal plane to terminate at the upper level of the retromolar pad can be advocated for wide clinical uses, as. It is a simple method and places the artificial occlusal plane very close to the position of the natural plane of occlusion.

The location of maxillar and mandibular teeth in complete dentures depends on the features of alveolar ridges. Teeth are usually arranged in such a way that the space between maxillar and mandibular ridges will be equally used. The most recently study dealing with the location of the occlusal plane is the one concerned with papillae in the side where Stenon Channel was opened in the cheek. In the study on 407 subjects having natural teeth, it was determined that Parotis Papilla was 3.8 mm higher than the occlusal plane. Doubtless, it should not be expected that this papilla, which is an anatomic occurrence, will be at the same level on either side.<sup>8</sup>

Whichever jaw the occlusal plane is away from, slide movements on the denture placed on that jaw will be more influential and the denture will be unstable. Because the maxillary dentures are more retention than the mandibular dentures, it is often the mandibular dentures that are influenced by such cases. Therefore, especially in the cases in which alveolar ridge atrophy is advanced, occlusal plane should be approach to the mandibular ridge in the molar area.<sup>8</sup> This may also result from an attempt to improve the mandibular denture's stability by lowering the occlusal plane, thus lowering the loading point of occlusal forces.<sup>19</sup>

Maxillary teeth should be appear extruded in the case in which occlusal plane is most approach to the mandibular ridge. This causes a great aesthetic problem. In contrast, especially mandibular teeth appear in the cases in which occlusal plane is most approach to the maxillary ridge, and the mandibular denture tends the slide forward.<sup>8</sup>

The correlation between the inclination of the occlusal plane and masticatory closing movement could serve as the functional background for the significance of the occlusal plane.<sup>20</sup> The contribution of the inclination of the occlusal plane to masticatory movement was greater than that of occlusal guidance throughout the closing phase except near the intercuspal range.<sup>21</sup>

## CONCLUSION

The results of this study showed that a mean vertical height of 4 mm at the retromolar pad could be accepted as a suitable reference to determine the occlusal plane.

## REFERENCES

- 1- Johnson DL, Stratton RJ. Fundamentals of removable prosthodontics. Chicago: Quintessence, 1980: 457-474.
- 2- Academy of prosthodontics. Glossary of prosthodontic terms. 6 th ed. J Prosthet Dent 1994; 71 (1): 44-121.
- 3- Mack PJ. A discussion of some factors of relevance to the occlusion of complete dentures. Aust Dent J 1989; 34 (2): 122-129.
- 4- Joffe E. Establishing the horizontal plane for positioning of the plane of occlusion. N Y State Dent J 1993;59 (1):29-31.

- 5- Güldağ Ü, Yanıkoğlu N, Ceylan G, Bayındır F. Oklüzal dikey boyutun değerlendirilmesi: Doğal dişli bireylerde sentrik oklüzyon durumundaki alt ve üst anterior dişlerin ölçümlerinden yararlanılması [Determining the occlusal vertical dimensions (use of maxillary and mandibular anterior teeth measurement in dentulous subjects)]. Atatürk Üniv Diş Hek Fak Derg 1997;7 (1):17-21.

- 6- Yeşil Z. Sürekli dişlerin mesio distal ve vestibulo lingual kuron boyutlarının karşılaştırılması (Comparison of mesio distal and vestibule lingual crown dimensions of permanent teeth). Atatürk Üniv Diş Hek Fak Derg 1995;5 (2):107-110.

- 7- Spratley MH. A simplified technique for determining the occlusal plane in full denture construction. J Oral Rehabil 1980; 7 (1): 31-33.

- 8- ÇalikkocaoğluS. Tam Protezler. 3. Baskı, İstanbul, 1988: 434,467-472.

- 9- Ogawa T, Koyano K, Suetsugu T. Correlation between inclination of occlusal plane and masticatory movement. J Dent, 1998 ;26(2):105-112

- 10- Hickey JC, Zarb GA. Boucher' s prosthodontic treatment for edentulous patients. St.Louis:The CV Mosby, 1980: 296-298.

- 11- Van Niekerk FW, Miller VJ, Bibby RE. The ala-tragus line in complete denture prosthodontics. J Prosthet Dent 1985; 53 (1): 67-69.

- 12- Kazanoglu A, Unger JW. Determining the occlusal plane with the Camper' s plane indicator. J Prosthet Dent 1982; 67 (4): 499-501.

- 13- D' Souza NL, Bhargava K. A cephalometric study comparing the occlusal plane in dentulous and edentulous subjects in relation to the maxillomandibular space. J Prosthet Dent 1975; 75 (2): 177-182.

- 14- Heartwell CM, Rahn AO. Syllabus of complete denture. Philadelphia: Lea and Febiger, 1980:243.

- 15- İsmail YH, Bowman JF. Position of the occlusal plane in natural and artificial teeth. J Prosthet Dent 1968; 20 (5): 407-411.

16- Nissan J, Barnea E, Zeltzer C, Cardash HS. Relationship between occlusal plane determinants and craniofacial structures. J Oral Rehabil 2003 ;30 (6):587-591.

17- Ogawa T, Koyano K, Suetsugu T. The relationship between inclination of the occlusal plane and jaw closing path. J Prosthet Dent 1996; 76 (6): 576-580.

18- Celebic A, Valentic-Peruzovic M, Kraljevic K, Brkic H. A study of the occlusal plane orientation by intra-oral method (retromolar pad). J Oral Rehabil 1995; 22 (3): 233-236.

19- Hayakawa I. Principles and practices of complete dentures. Quintessence publishing, Tokyo, 2001:70.

20- Ogawa T, Koyano K, Suetsugu T. Characteristics of masticatory movement in relation to inclination of occlusal plane. J Oral Rehabil 1997 ;24(9):652-657.

21- Ogawa T, Koyano K, Umemoto G. Inclination of the occlusal plane and occlusal guidance as contributing factors in mastication. J Dent 1998 ;26 (8):641-647.

**Yazışma Adresi:**

**Prof. Dr. Zeynep YEŞİL DUYMUŞ**

Atatürk Üniversitesi  
Diş Hekimliği Fakültesi  
Protetik Diş Tedavisi Anabilim Dalı,  
Erzurum, TÜRKİYE (TURKEY).  
Phone : 90 442 2311781  
Fax : 90 442 2360945  
e-mail : zyesilz@hotmail.com