

Tildrakizumab for the treatment of exfoliative cheilitis

Eksfoliyatif keilit tedavisinde tildrakizumab

Timothy L. Cowan^{1,2}, Anna Wilson^{1,2}, Nada Abu Alrub^{1,2}, Mani Makhija³, Dedee F. Murrell^{1,2}

¹Dept. of Dermatology, St George Hospital, Sydney, NSW, Australia, ²Faculty of Medicine, UNSW, Sydney, NSW, Australia, ³Kossard Dermatopathologists, Sydney, NSW, Australia

Dear editor,

A 24 year-old man was referred for chronic idiopathic cheilitis that was non-responsive to previous treatments. He had developed painful and dry lips with intermittent erosions and crusts since the age of 21 and this was significantly impacting his oral intake and interpersonal relations with his partner. He has a history of mild asthma, mild eczema and anxiety and no personal or family history of inflammatory bowel disease, autoimmune conditions or psychiatric conditions. He was taking vitamin B, Vitamin C and Zinc supplements and had no known medication allergies.

He had been extensively investigated with patch testing revealing a moderate reaction to gold sodium thiosulphate but no known contact or dietary allergen was identified. A punch biopsy revealed spongiosis with lymphocytic exocytosis and an acanthotic squamous epithelium (Fig. 1). His investigations returned negative serology for HSV 1, HSV 2, VZV, syphilis, hepatitis A/B/C, HIV serology, Quantiferon Gold, dsDNA, ANCA, ANA, ENA, BP 180/230, Desmoglein 1/3, Envoplakin and Collagen VII antibodies and normal levels of zinc, vitamin D,

iron studies, thyroid function, full blood count, renal function and liver function. He had negative coeliac serology and a normal colonoscopy and gastroscopy with no histopathological evidence of inflammatory bowel disease and normal body weight.

After several case conferences discussing differentials, he was diagnosed with idiopathic exfoliative cheilitis - a chronic inflammatory condition affecting the lips that has been associated with hypersensitivities and psychiatric conditions.^{1,2} He had trialled flucloxacillin, cephalexin, ciclosporin, itraconazole, acitretin, dapsone, colchicine, oral and topical tacrolimus, mycophenolate mofetil, topical mometasone and topical clobetasol with no significant lasting improvement (Table 1). In addition, he was offered hydroxychloroquine but declined this due to concern regarding possible adverse events. He did have transient improvement from 16 weeks of low-level laser therapy with a reduction in his pain score from Visual Analogue Score (VAS) 5/10 to 2/10; however he could not tolerate this due to a subsequent burning sensation over his lips.

Key words: biologic, interleukin-23, cheilitis, dermatology, tildrakizumab

Corresponding author: Dedee Murrell 17 Kensington Street, Kogarah NSW, Australia.

E-mail: d.murrell@unsw.edu.au

Received: 09 December 2022 **Accepted:** 21 January 2023

Conflicts of Interest: None

Funding: None

How to cite this article: Cowan TL, Wilson A, Abu Alrub N, Makhija M, Murrell DF. Tildrakizumab for the treatment of exfoliative cheilitis. *Mucosa* 2023;6:19-21.



This work is licensed under a Creative Commons Attribution-NonCommercial 4.0 International License.

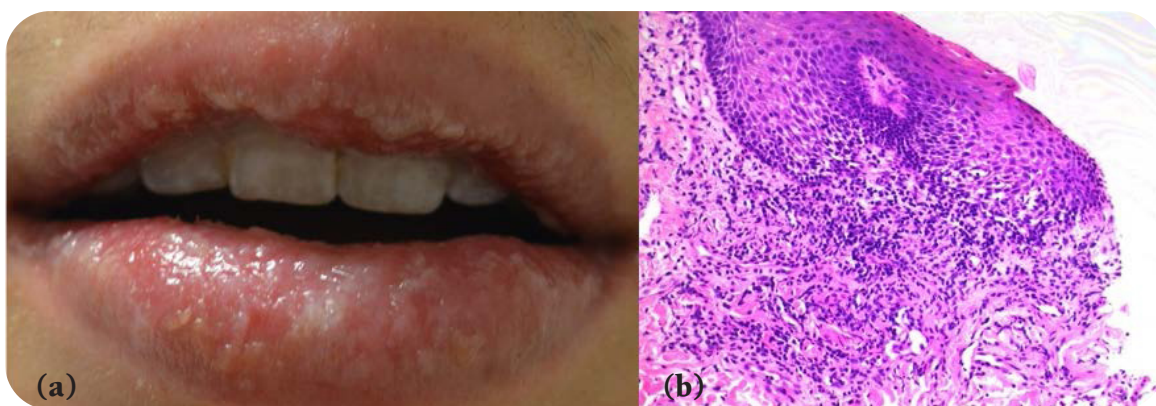


Fig. 1a. Exfoliative lips at the time of biopsy **1b.** Histopathology of punch biopsy sample revealing spongiosis with lymphocytic exocytosis and an acanthotic squamous epithelium

Table 1. List of previous oral systemic treatments in chronological order

Order	Treatment	Duration	Efficacy	Adverse Events	Reason for Cessation
1	Flucloxacillin	2 weeks	Nil	Nil	No efficacy
2	Cephalexin	3 weeks	Nil	Nil	No efficacy
3	Ciclosporin	2 months	Nil	Nil	No efficacy
4	Itraconazole	2 months	Nil	Nil	No efficacy
5	Acitretin	4 months	Nil	Nil	No efficacy
6	Dapsone	4 months	Nil	Worsened burning sensation and swelling of lips	Adverse event
7	Colchicine	2 months	Nil	Nil	No efficacy
8	Tacrolimus	12 months	Mild	Nil	Lack of complete efficacy, to trial mycophenolate mofetil
9	Mycophenolate mofetil	8 months	Moderate clinical improvement of pain, but ongoing clinical features of cheilitis	Nil	Lack of complete efficacy, to trial tildrakizumab

He was commenced on a compassionate-supply of 12-weekly tildrakizumab 100 mg after induction at 0 and 4 weeks. At 3 months, he reported mild overall improvement with a reduction in flares of his cheilitis. At 6 months, significant improvement in appearance, comfort and reduction in pain was reported with a reduction in flares and no side effects. At 9 months,

his cheilitis had continued to improve and stabilized by 12 months (Fig. 2). His DLQI reduced from 15 at baseline, to 7 at 6 months, 2 at 9 months and at 4 at 12 months.

This case of chronic, refractory cheilitis without any obvious contact allergen or clear trigger and with a benign medical history has shown a significant

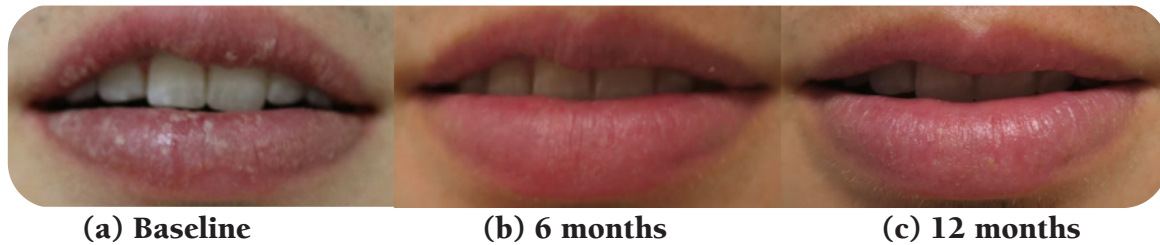

Fig. 2. Timeline of improvement since the commencement of tildrakizumab

response to treatment with tildrakizumab. Cases of atopic cheilitis have previously had effective treatment with topical tacrolimus, however this was ineffective in this case.^{2,3} Granulomatous cheilitis, associated with Crohn's Disease has been successfully treated with TNF-alpha inhibitors⁴, integrin $\alpha 4\beta 7$ inhibitor (vedolizumab)⁵ and an interleukin 12/23 inhibitor (ustekinumab)⁶. This is the first documented use of tildrakizumab or an interleukin-23 inhibitor for the successful treatment of idiopathic exfoliative cheilitis leading to a significant improvement in quality of life.

Informed consent: The author certifies that he has obtained all appropriate consent forms from the patient.

Peer-review: Externally peer-reviewed

Authorship contributions:

Conception and design, or analysis and interpretation of data: TC,AW, NA,MM, DM

Drafting the manuscript or revising the content: TC,AW, NA,MM, DM

Final approval of the version to be published: TC,AW, NA,MM, DM

References

1. Cai L, Wei J, Ma D, et al. Predisposition of hypersensitivity in patients with exfoliative cheilitis. *J Dent Sci* 2022;17:476-81.
2. Georgakopoulou E, Loumou P, Grigoraki A, Panagiotopoulos A. Isolated lip dermatitis (atopic cheilitis), successfully treated with topical tacrolimus 0.03%. *Med Oral Patol Oral Cir Bucal* 2021;26:e357-e60.
3. Liu J, Shi L, Wang X, et al. Tacrolimus 0.03% ointment treatment in exfoliative cheilitis: A randomised controlled clinical trial and monitoring blood concentration. *J Oral Pathol Med* 2021;50:251-9.
4. Barry O, Barry J, Langan S, Murphy M, Fitzgibbon J, Lyons JF. Treatment of granulomatous cheilitis with infliximab. *Arch Dermatol* 2005;141:1080-2.
5. Gueutier A, Leducq S, Joly A, Picon L, Vaillant L, Samimi M. Efficacy of vedolizumab in granulomatous cheilitis refractory to TNF α inhibitors. *Int J Dermatol* 2019;58:e236-e7.
6. Taxonera C, Alba C, Colmenares M, Olivares D, Rey E. Recurrent granulomatous cheilitis associated with Crohn's disease successfully treated with ustekinumab: case report and literature review. *Therap Adv Gastroenterol* 2020;27:13.