

Effects of 3-Benzoyl-7-Hydroxy Coumarin Compound on TNF- α and Caspase-3 Immunoreactivity in Kidneys of Rats Exposed to Aluminum

Ahmet TURK^{1,*}, Tuncay KULOĞLU², Busra ZENCİRCİ³, Ali GUREL⁴, Abdullah KARADAG⁵, Yusuf OZAY⁶, Serhat HANCER², M. Emre YUZER³, Kenan TURKAN⁷, Ahmet OZKAYA⁷

¹Adıyaman University Faculty of Medicine Department of Histology-Embryology, Adıyaman, Türkiye

²Firat University Faculty of Medicine Department of Histology-Embryology Elazığ, Türkiye

³Adıyaman University Faculty of Medicine Department of Anatomy Adıyaman, Türkiye

⁴Firat University Faculty of Medicine Department of Nephrology, Elazığ, Türkiye

⁵Adıyaman University Faculty of Medicine Department of Physiology Adıyaman, Türkiye

⁶Adıyaman University Faculty of Medicine Department of Medical Biology, Adıyaman, Türkiye

⁷Adıyaman University the Faculty of Arts and Sciences, Department of Chemistry, Adıyaman, Türkiye

ORCID ID: Ahmet TURK: <https://orcid.org/0000-0003-0903-3522>; Tuncay KULOĞLU: <https://orcid.org/0000-0001-9874-3838>; Busra

ZENCİRCİ: <https://orcid.org/0000-0002-6015-3047>; Ali GUREL: <https://orcid.org/0000-0001-8087-8814>; Abdullah KARADAG:

<https://orcid.org/0000-0003-3620-9589>; Yusuf OZAY: <https://orcid.org/0000-0003-3855-6197>; Serhat HANCER: <https://orcid.org/0000-0003-3237-3672>; M. Emre YUZER: <https://orcid.org/0000-0002-0115-9473>; Kenan TURKAN: <https://orcid.org/0000-0002-7379-8995>; Ahmet

OZKAYA: <https://orcid.org/0000-0002-0173-3084>

Received: 14.12.2022

Accepted: 08.06.2023

Published online: 13.06.2023

Issue published: 30.06.2023

Abstract: This study aimed to investigate the effects of 3-benzoyl-7-hydroxy coumarin compound on apoptotic markers in the kidney tissues of rats treated with Aluminum (Alu). 28 Wistar albino male rats were divided into four groups (n = 7) as: Control Group: 1 ml/kg 0.9% NaCl was administered by oral gavage every other day during the experiment. Aluminium (Alu) Group: Alu was prepared in water and given intraperitoneally (i.p) for 30 days at an excess of 8.3 mg/kg/day. Treatment Group: 10 mg/kg 3-Benzoyl-7-Hydroxy Coumarin was administered to rats by oral gavage every other day for 30 days. Alu + Treatment Group: 8.3 mg/kg Alu was prepared in water and administered i.p for 30 days every other day, and then 10 mg/kg 3-Benzoyl-7-Hydroxy Coumarin was administered to rats by oral gavage every other day for 30 days. At the end of the 30-day experiment, the kidney tissue of the animals was removed under anesthesia and stored under appropriate conditions. In according to our data, Alu administration caused increased Caspase-3 TNF- α and MDA levels in the kidney tissue and 3-benzoyl-7-hydroxy coumarin was found to reverse these changes significantly.

Keywords: Oxidative stress, Apoptosis, Proinflammatory cytokine, Immunohistochemistry.

Alüminyuma Maruz Kalan Sıçanların Böbreklerinde 3-Benzoil-7-Hidroksi Kumarin Bileşiğinin TNF- α ve Kaspaz-3 İmmün Reaktivitesi Üzerine Etkileri

Öz: Bu çalışmada, Alüminyum (Alu) ile tedavi edilen sıçanların böbrek dokularında 3-benzoil-7-hidroksi kumarin bileşiğinin apoptotik belirteçler üzerindeki etkilerini araştırmayı amaçladık. Deney için 28 adet Wistar albino erkek ratlar 4 gruba (n=7) ayrıldı; Kontrol Grubu: Deney süresince sıçanlara gün aşırı 1 ml/kg %0.9 NaCl oral gavaj yolu ile verildi. Alüminyum (Alu) Grubu: Suda çözünmüş, Alu bileşiği intraperitoneal (i.p.) yol ile 30 gün boyunca 8.3 mg/kg/gün aşırı uygulandı. Tedavi Grubu: Sıçanlara gün aşırı 10 mg/kg 3-Benzoyl-7-Hydroxy kumarin oral gavaj yolu ile 30 gün süreyle uygulandı. Alu + Tedavi Grubu: 8.3 mg/kg Alu su içinde hazırlandı ve i.p. deney süresi boyunca gün aşırı 10 mg/kg 3-Benzoyl-7-Hydroxy kumarin oral gavaj ile uygulandı. 30 günlük deney sonunda anestezi altında hayvanların böbrek dokusu alınarak uygun koşullarda saklandı. Elde edilen verilere göre Alu uygulaması böbrek dokusunda Kaspaz-3, TNF- α ve MDA düzeylerinin artmasına neden olmuş ve 3-benzoil-7-hidroksi kumarin bileşiğinin bu değişiklikleri önemli ölçüde tersine çevirdiği görüldü.

Anahtar kelimeler: Oksidatif stres, Apoptoz, Proinflammatory sitokin, İmmünohistokimya.

1. Introduction

Alu is the most plentiful compound on earth and is commonly used in daily life but has serious side effects on health (Williams, 1999). In daily life, it is almost unfeasible to abstain exposure to Alu as it is used as a filler in water purification, medicines and vitamins, food additives, packaging materials, antiperspirants deodorants or plastics (Abdel Moneim et al., 2013). In the long-term, low doses of Alu cause oxidative damage in tissues by increasing reactive oxygen radicals (ROS) in many tissues (Rondeau et al., 2000). *In vivo* and *in vitro* studies have showed that Alu causes ROS generation,

mitochondrial dysfunction, cell death, and genetic damage (Yousef et al., 2019). Moreover, excessive exposure to Alu has toxic effects on the immune, respiratory, and nervous systems in addition to the ones on the liver (Sun et al., 2015).

Lentini et al. mentioned that most of the Alu accumulated in the human body comes from contaminated food and water and through the skin. In addition, they stated that while the majority of Alu is excreted by the kidneys, long-term exposure may cause nephrotoxicity or even kidney failure. (Lentini et al., 2017). Researchers found that Alu-induced oxidative

stress leads to apoptosis in rats. Al-Kahtani et al., 2020). Oxidative stress causes damage to many tissues and organs including the heart, liver, kidney, and brain (Palma et al., 2014; Othman et al., 2020). In ongoing scientific studies, the effects of antioxidants on the prevention of this damage caused by oxidative stress are being investigated.

Coumarins have a polyphenolic structure and are in the structure of "2H-1-benzopyran-2-one". These structures are found extensively in plants and they are also synthesized under laboratory conditions (Venugopala et al., 2013). The chemical structures of coumarins have dense π -conjugated bond systems. In particular, the attachment of different kinds of functional groups at different positions to the main skeleton of the molecule provides important functionalities to the molecule. Additionally, it contributes to the change in the photophysical, chemical, and spectroscopic properties of coumarins and to the development of different application areas (Kurt & Topsoy, 2017; Kurt et al., 2019). The 3-benzoyl-7-hydroxycoumarin molecule is in the structure of hydroxycoumarins. Hydroxycoumarins are phenolic and are effective in scavenging free radicals. These structures, which have antioxidant properties, also have metal chelator properties (Lien et al., 1999). It is reported that coumarins, either natural or synthesized under laboratory conditions, have many biochemical effects such as antioxidant, antiviral, antifungal, antibacterial, and antitumor (Patonay et al., 1984; Nofal et al., 2000; Emmanuel-Giota et al., 2001). Caspase-3 is an apoptotic cell marker and its activation changes in oxidative stress and lipid peroxidation. Tumor necrosis factor alpha (TNF- α), a proinflammatory cytokine, also causes necrosis or apoptosis in acute inflammation (Nicholson, 1999; Idriss & Naismith, 2000; Güleş & Ülker, 2008). In the literature, the effectiveness of coumarins such as fraxin, esculetin, and agosyllin against oxidative stress has been studied but the 3-benzoyl-7-hydroxy coumarin molecule has not (Venugopala et al., 2013). We aimed to investigate the potential protective effects of the 3-benzoyl-7-hydroxycoumarin compound on Alu-induced kidney damage.

2. Material and Methods

This study was performed after obtaining approval from the local ethical committee (Adiyaman University Animal Experiments Local Ethics Committee, protocol no:(2022/066).

Two-three months old 28 Wistar Albino male rats, in weight between 200-250 g were used. During the experimental period (30 days), rats were housed at 22 \pm 20°C room temperature, in rooms with 12 hours of light and 12 hours of dark, with food and water ad-libitum.

4 equal groups were planned as shown below:

Control Group: 1 ml/kg 0.9% NaCl was administered by oral gavage every other day during the experiment.

Alu Group: Alu was prepared in water and given by intraperitoneal (i.p) for 30 days (15 applications in total) at an excess of 8.3 mg/kg/day (Özkaya and Türkan, 2021).

Treatment Group: 10 mg/kg 3-Benzoyl-7-Hydroxy

Coumarin was administered by oral gavage every other day for 30 days (15 applications in total).

Alu+Treatment Group: 8.3 mg/kg Alu was prepared in water and administered i.p. for 30 days (15 applications in total) every other day. Also 10 mg/kg 3-Benzoyl-7-Hydroxy Coumarin was administered to rats by oral gavage every other day for 30 days (15 applications in total).

2.1. Benzoyl-7-Hydroxy Coumarin Molecule Synthesis

For the synthesis of 3-benzoyl-7-hydroxycoumarin molecule, ethyl benzoyl acetate (3.844 g), 2,4-dihydroxybenzaldehyde (2.762 g), 50 mL acetone, and three drops of piperidine were refluxed on a magnetic stirrer for 2 hours. The mixture was transferred into excess methanol to precipitate the 3-benzoyl-7-hydroxy coumarin molecule. This molecule was purified by crystallization in ethanol (Kurt et al., 2018).

2.2. Removal of tissues

At the end of the 30-day experimental period, experimental animals were anesthetized by i.p administration of 10% ketamine (Alfamine; Alfasan IBV, Woerden, The Netherlands) and 2% xylazine (Alfazine; Alfasan IBV, Woerden, The Netherlands) (Eser et al., 2021). Next, the kidneys were removed. Some pieces of the kidney tissues were placed at -80 °C for biochemical analysis. The remaining kidney tissues were stored in 10 % formaldehyde for immunohistochemical examination.

2.3. Malondialdehyde (MDA) Analyses

0.42 gr Tris-Base + 1.43 gr Tris-HCl + 3 gr KCl and 0.5 ml Tween 20 were prepared in 250 ml distilled water. This prepared buffer was used in the homogenate of the samples. MDA levels were measured according to the method Placer et al. (1966) stated: 15% trichloroacetic acid, 0.375% thiobarbutyric acid, and 0.25 N HCl (1:1:1, w/v) were added onto 500 μ L homogenate.

The mixture was heated in a water bath at 100°C for 30 minutes. After the mixture was cooled to room temperature, it was centrifuged at 15.000 g for 15 minutes. The obtained supernatant samples were transferred to the microplate wells and MDA levels were determined at 532 nm. MDA levels were expressed as (nmol/g wet tissue weight) (Placer et al., 1966).

2.4. Immunohistochemistry Analyses

After fixation (formaldehyde) procedure, kidney samples were passed through a graded alcohol series, cleared with xylene and embedded in paraffin. Next 5- μ m thick tissue sections were taken from the paraffin blocks and immunohistochemical stained. Caspase-3 and TNF- α expression were evaluated within kidney tissue sections. For this purpose, sections transferred to Poly-L-Lysine slides were rehydrated, then boiled in a microwave oven (750 W) seven times for 5 min each in citrate buffer solution, pH 6 for retrieving antigen. Sections were allowed to cool at room temperature for 20 min, washed three times for 5 min each with phosphate-buffered saline (PBS) (P4417; Sigma Chemical Co.), then treated for 5 min with hydrogen peroxide block solution (TA-125-HP; Lab Vision Corp. USA) to block endogenous peroxidase activity. Sections then were washed three times for 5 min

each with PBS and were treated with Ultra V Block (TA-125-UB; Lab Vision Corp.) for 5 min to prevent background staining. Next, sections were incubated with primary antibodies [(Caspase-3 (Rabbit monoclonal IgG, Abcam, ab184787, London, UK) and TNF- α primary antibodies (Rabbit polyclonal IgG, abcam ab220210, London, UK)] for immunostaining (60 min). Following this process, sections were incubated with secondary antibody (biotinylated goat anti-mouse/rabbit Ig G, TP-125-BN; Lab Vision Corp.) for 30 min, streptavidin peroxidase (TS-125-HR; LabVision Corp.) for 30 min. 3-Amino-9-ethylcarbazole (AEC) substrate + AEC chromogen (AEC substrate, TA-015 and HAS, AEC Chromogen, TA-002-HAC; Lab Vision Corp.) solution was dripped on the sections and washed with PBS. Next, tissue sections were counterstained with Mayer's haematoxylin and mounted with Large Volume Vision Mount (TA-125-UG; Lab Vision Corp). Stained sections were inspected and photographed using a Leica DM500 microscope (Leica DFC295). (Gürel et al., 2022).

2.4.1. Microscopic Evaluation of Staining Intensity

A histoscore performed as mentioned in Ucer et al.'s previous study (Ucer & Kocaman, 2022). The histoscores were calculated as histoscore = distribution \times intensity (Gürel et al., 2022).

2.5. Statistical Analysis

GraphPad® Prism 8.01 software was used for statistical analysis. One-way ANOVA, Tukey and Kruskal-Wallis tests were performed. The statistical significance (P-value) level was taken as 0.050 in all tests.

3. Results

3.1. Malondialdehyde (MDA) Levels

MDA levels of the control and treatment groups were found to be similar in kidney tissue ($p=0.5883$). MDA levels were significantly increased in the Alu group compared with the Control and Treatment groups ($p<0.0001$). There was a significant decrease in the Alu + Treatment group according to the Alu group ($p<0.0001$) (Fig. 1).

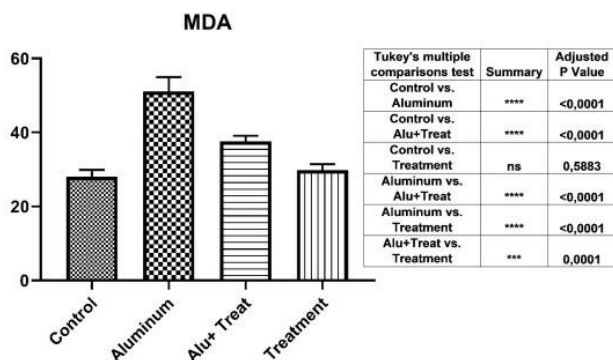


Figure 1. Analysis of MDA levels measured by spectrophotometric method in kidney tissue. The differences between the groups are given in the table.

3.2. Immunoreactivity of Caspase-3

Immunoreactivity of Caspase-3 was observed under light microscopy (black arrow) in the kidney tissue (Fig. 2).

Compared to the Control group, there was no statistically significant difference in the Treatment group ($p=0.9973$) while a statistically significant increase in caspase-3 immunoreactivity was observed in the Alu group ($p<0.0001$). The Alu + Treatment group displayed a statistically significant decrease in Caspase-3 immunoreactivity compared to the Alu group. The Alu + Treatment group displayed a statistically significant decrease in Caspase-3 immunoreactivity compared to the Alu group ($p<0.0001$) (Fig. 3)

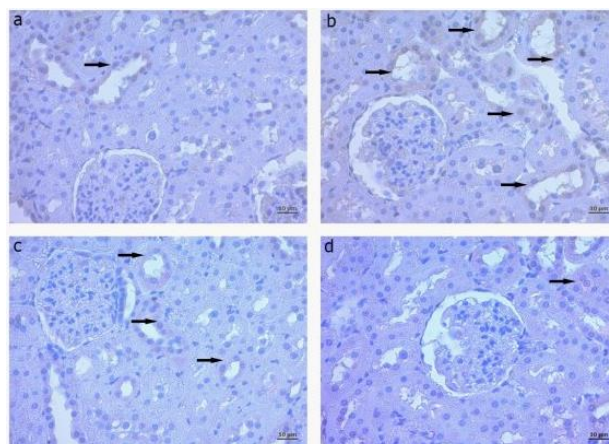


Figure 2. Immunohistochemical staining for caspase-3 (black arrow) in kidney tissue. caspase-3 immunoreactivity was similar in a- Control group d- Treatment groups. b- Increased caspase-3 immunoreactivity of the Alu group. c- Decreased caspase-3 immunoreactivity of Alu+ Treatment group. Scala bar: 10 μ m

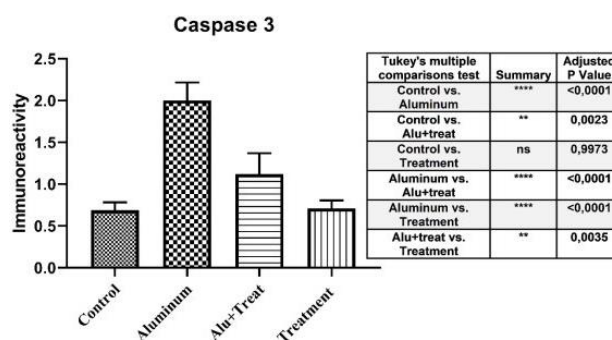


Figure 3. Immunoreactivity of caspase-3 levels in kidney tissues. The differences between the groups are given in the table.

3.3. Immunoreactivity of TNF- α

Immunoreactivity of TNF- α was observed under light microscopy (black arrow) in the kidney tissue (Fig. 4). In comparison to the Control group, there was no statistically significant difference in the Treatment group ($p=0.9328$) whereas TNF- α immunoreactivity increased significantly in the Alu group ($p<0.0001$). Statistically significant decreases in TNF- immunoreactivity were observed in the Alu + Treatment group compared to the Alu group ($p<0.0001$) (Fig. 4c, Fig. 5).

4. Discussion

From past to the present, therapeutic agents that can depress the onset and progression of nephrotoxicity have always been needed and studies on this subject have increasingly continued. Our study was designed to specify the potential effect of 3-Substituted Coumarin on Alu toxicity, apoptosis, and oxidative stress.

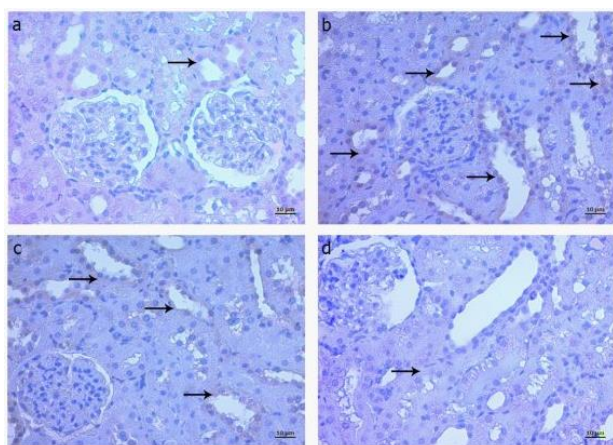


Figure 4. Immunohistochemical staining for TNF- α (black arrow) in the kidney tissue. TNF- α immunoreactivity was similar in a- Control group d- treatment groups. b- Increased TNF- α immunoreactivity of Alu group. c- Decreased TNF- α immunoreactivity of Alu+ Treatment group. Scala bar: 10 μ m

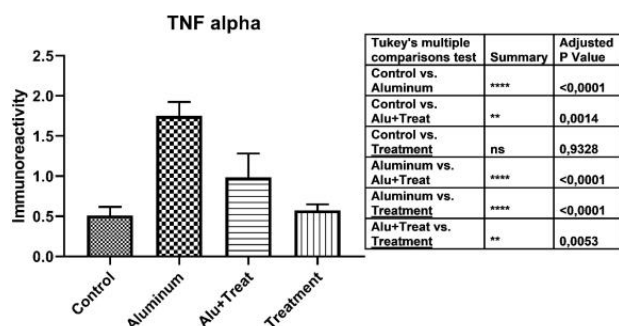


Figure 5. Immunoreactivity of TNF- α levels in kidney tissues. The differences between the groups are given in the table.

Renal redox status deteriorates by the toxic activity of Alu (Al-Qhtani & Farran, 2017; El-Demerdash et al., 2020). Toxic effects cause oxidation of lipids, proteins and nucleic acids, DNA damage and apoptosis of cells (Liu et al., 2016; Hasona & Ahmed, 2017). Apoptosis can occur in mammalian cells in two main ways: intrinsic (mitochondrial) and extrinsic (death receptors). These pathways are important for maintaining homeostasis by regulating cell death (McIlwain et al., 2013).

The induction of Caspase-3 increases the controlled destruction of cellular components (Baud & Karin, 2001). Another marker TNF- α , a cell signaling protein, is critical to cell differentiation, proliferation, inflammation, immunity, necrosis, and apoptosis (Turner et al., 2014). We observed that MDA, Caspase-3, and TNF- α levels increased in the Alu group compared to the control. It was seen that MDA levels increased while antioxidant enzyme levels decreased in the Alu group and it was reported that the antioxidant *Rhamnus aternus* L. extract protects the tissue by increasing antioxidant enzyme levels (Tichati et al., 2022). Othman et al. (2020) determined that lipid peroxidation and nitric oxide and TNF- α levels increased while glutathione decreased in rats' liver and kidney tissues treated with Alu. However, they reported that melatonin, which is an antioxidant given as a treatment, improves these levels (Othman et al., 2020). In a study conducted in PC12 cells, it was observed that aluminum exposure decreased cell viability, decreased antioxidant enzyme activity, and increased the rate of apoptosis (Yu et al., 2022). It was

stated in another study that Al induced osteoblast apoptosis in culture by inhibiting the expression of apoptotic Bcl-2 protein, increasing the expression of pro-apoptotic Bax, Bak, and Bim proteins, releasing Sitokrom C into the cytoplasm, and activating caspases 3, caspases 9, and the Fas/Fas ligand signaling pathway (Xu et al., 2018). In the study by Kaya et al. (2022), the level of Caspase-3 increased in rats renal tissue of the Alu group whereas NAC, which was given as a treatment, suppressed free radicals and reduced the level of Caspase-3 (Kaya et al., 2022). In another study, it was stated that high doses of Alu in the medium increase the proinflammatory cytokines such as TNF- α (Campbell, 2004).

The previous studies stated that the principal reason for pathological Alu toxicity is oxidative stress and apoptosis and our findings conform to the previous literature (Xu et al., 2017). In our study, the group given 3-Benzoyl-7-Hydroxy Coumarin with antioxidant character as a treatment against Alu damage significantly decreased MDA, Caspase-3, and TNF- α levels compared to the group administered Alu. This is supported by studies that antioxidant substances or enzymes of antioxidant character take significant protective roles especially in the kidney (Ichikawa et al., 1994). Additionally, since the kidneys have highly active oxidative metabolism resulting in the production of reactive oxygen species (ROS), mainly due to their transport functions, the pro-oxidant effects of Alu, an active metal, can be reduced by supplementing with antioxidants (Exley,2004). In a study, it was seen that coumarin was strong chemopreventive and increased antioxidant enzyme levels by suppressing nephrotoxicity. In a study, it was seen that gambling is a strong chemopreventive and it increases antioxidant enzyme levels by suppressing nephrotoxicity (Khan et al., 2004). In the study of Atmaca et al. (2011), it was reported that there was an increase in MDA besides a decrease in Catalase (CAT), Super oxide dismutase (SOD) levels in rats treated with carbon tetra chloride (CCL4) but a decrease in MDA levels and an increase in antioxidant enzyme levels in the group treated coumarin with CCL4 (Atmaca et al., 2011). Marshall (Marshall, 2005) and Khan et al. (2004) stated that coumarin suppressed tissue damage by preventing free radical-mediated oxidative stress in rats, reducing nephrotoxicity caused by potassium bromate and ferric nitrilotriacetate (Khan et al., 2004; Marshall, 2005). In addition, Chang et al. (1996) reported that coumarin inhibited lipid peroxidation and reduced superoxide and hydroxyl radicals (Chang et al., 1996).

As a result, in our study, it was determined that Alu caused damage to the kidney tissue and increased MDA, Caspase-3, and TNF- α levels. Additionally, it was observed that 3-benzoyl-7-hydroxy coumarin treatment had protective effects in the tissue by suppressing apoptosis. We believe that 3-benzoyl-7-hydroxy coumarin may have an ameliorative effect against oxidative stress induced by Alu.

When the findings obtained in this study are evaluated in general, it is determined that high doses of Alu can increase the risk profile of kidney damage by creating changes in the expression levels of various

proteins and disrupting the oxidant-antioxidant balance. 3-benzoyl-7-hydroxy coumarin, a newly synthesized compound, can affect kidney functions and suppress apoptotic changes at high levels, especially due to kidney damage. It can also protect cells against impaired apoptotic signals by causing a decrease in Caspase-3 and TNF- α expression. Alu, which is known to cause toxic changes in the body, can also trigger serious pathologies such as dialysis dementia, osteomalacia with fractures, hypochromic microcytic anemia, and parathyroid dysfunction. Therefore, for individuals with kidney disease, it is very important for the well-being of the patient to protect the body from Alu accumulation or damage.

Therefore, we believe that the 3-benzoyl-7-hydroxy coumarin compound may be a supplemental agent in treatments against nephrotoxicity and may be beneficial for the medical science with further studies.

Acknowledgement: Special thanks to Prof. Dr. Murat KOCA (Department of Pharmaceutical Chemistry, Faculty of Pharmacy, Adiyaman University) and Prof. Dr Adnan Kurt (Department of Chemistry, Faculty of Arts and Sciences, Adiyaman University) for their contribution to this study.

Ethics committee approval: This study was conducted in accordance with the ethical standards of animal experiments. The legal research ethics committee approval permissions for the study were obtained from the Experimental Animals Ethics Committee of Adiyaman University (No: 2022/066/13).

Conflict of interest: The authors declare that there is no conflict of interest.

Author Contributions: Conception - A.T., A.O.; Design - A.T., T.K.; Supervision: A.T.; Fund - T.K., S.H., B.Z.; Materials - A.O., K.T., A.G.; Data Collection or Processing: A.T., A.O.; Analysis Interpretation: A.T., A.O., B.Z.; Literature Review - A.T., B.Z., A.G.; Writing - A.T., A.O.; Critical Review - B.Z., M.E.Y., Y.O., A.K.

References

- Abdel Moneim, A.E., Othman, M.S., Mohmoud, S.M., & El-Deib, K.M. (2013). Pomegranate peel attenuates aluminum-induced toxicity mechanisms and methods. *Hepatorenal Toxicity*, 23(8), 624-633. <https://doi.org/10.3109/15376516.2013.823634>
- Al-Kahtani, M., Abdel-Daim, M.M., Sayed, A.A., El-Kott, A., & Morsy, K. (2020). Curcumin phytosome modulates aluminum-induced hepatotoxicity via regulation of antioxidant, Bcl-2, and caspase-3 in rats. *Environmental Science and Pollution Research*, 27(17), 21977-21985. <https://doi.org/10.1007/s11356-020-08636-0>
- Al-Qhtani, S. A., & Farran, S. K. (2017). The protective and therapeutic effect of resveratrol in improving renal and hepatic failure induced by aluminum chloride in experimental animals. *Journal of American Science*, 13(10), 26. <https://doi.org/10.7537/marsjas131017.03>
- Atmaca, M., Bilgin, H.M., Obay, B.D., Diken, H., Kelle, M., & Kale, E. (2011). The hepatoprotective effect of coumarin and coumarin derivatives on carbon tetrachloride-induced hepatic injury by antioxidative activities in rats. *Journal of Physiology and Biochemistry*, 67(4), 569-576. <https://doi.org/10.1007/s13105-011-0103-5>
- Baud, V., & Karin, M. (2001). Signal transduction by tumor necrosis factor and its relatives. *Trends in Cell Biology*, 11(9), 372-377. [https://doi.org/10.1016/s0962-8924\(01\)02064-5](https://doi.org/10.1016/s0962-8924(01)02064-5)
- Campbell, A. (2004). Inflammation, neurodegenerative diseases, and environmental exposures. *Annals of the New York Academy of Sciences*, 1035(1), 117-132. <https://doi.org/10.1196/annals.1332.008>
- Chang, W.S., Lin, C.C., Chuang, S.C., & Chiang, H.C. (1996). Superoxide anion scavenging effect of coumarins. *The American journal of Chinese medicine*, 24(1), 11-17. <https://doi.org/10.1142/s0192415x96000037>
- El-Demerdash, F.M., Baghdadi, H.H., Ghanem, N.F., & Mhanna, A.B.A. (2020). Nephroprotective role of bromelain against oxidative injury induced by aluminium in rats. *Environmental toxicology and pharmacology*, 80, 103509. <https://doi.org/10.1016/j.etap.2020.103509>
- Emmanuel-Giota, A.A., Fylaktakidou, K.C., Litinas, K.E., Nicolaidis, D.N., & Hadjipavlou-Litina, D.J. (2001). Synthesis and biological evaluation of several 3-(coumarin-4-yl) tetrahydroisoxazole and 3-(coumarin-4-yl) dihydropyrazole derivatives. *Journal of Heterocyclic Chemistry*, 38(3), 717-722. <https://doi.org/10.1002/jhet.5570380329>
- Eser, N., Yoldas, A., Turk, A., Kalaycı Yigin, A., Yalcin, A., & Cicek, M. (2021). Ameliorative effects of garlic oil on FNDC5 and irisin sensitivity in liver of streptozotocin-induced diabetic rats. *Journal of Pharmacy and Pharmacology*, 73(6), 824-834. <https://doi.org/10.1093/jpp/rgab023>
- Exley, C. (2004). The pro-oxidant activity of aluminum. *Free Radical Biology and Medicine*, 36(3), 380-387. <https://doi.org/10.1016/j.freeradbiomed.2003.11.017>
- Güleş, Ö., & Ülker, E. (2008). Apoptozun belirlenmesinde kullanılan yöntemler. *Yüzüncü Yıl Üniversitesi Veteriner Fakültesi Dergisi*, 19(2), 73-78. ISSN 1017-8422; e-ISSN: 1308-3651
- Gürel, A., Türk, A., Aydın, H., Genç, F., & Yalçın, A. (2022). Cinnamon's effect on apoptosis, inflammation and trpm2 channels in methotrexate induced renal damage. *International Journal of Advanced Research in Medicine*, 4(2), 06-10. <https://doi.org/10.22271/27069567.2022.v4.i2a.387>
- Hasona, N.A., & Ahmed, M.Q. (2017). Antioxidant and ameliorative effects of Zingiber officinale against aluminum chloride toxicity. *International Journal of Chinese Medicine* 1(4), 124-131.
- Ichikawa, I., Kiyama, S., & Yoshioka, T. (1994). Renal antioxidant enzymes: their regulation and function. *Kidney International*, 45(1), 1-9. <https://doi.org/10.1038/ki.1994.1>
- Idriss, H. T., & Naismith, J.H. (2000). TNF α and the TNF receptor superfamily: Structure-function relationship (s). *Microscopy Research and Technique*, 50(3), 184-195. [https://doi.org/10.1002/1097-0029\(20000801\)50:3<184::AID-JEMT2>3.0.CO;2-H](https://doi.org/10.1002/1097-0029(20000801)50:3<184::AID-JEMT2>3.0.CO;2-H)
- Kaya, S., Yalçın, T., Boydak, M., & Dönmez, H.H. (2022). Protective Effect of N-Acetylcysteine Against Aluminum-Induced Kidney Tissue Damage in Rats. *Biological Trace Element Research*, 1-10. <https://doi.org/10.1007/s12011-022-03276-6>
- Khan, N., Sharma, S., & Sultana, S. (2004). Amelioration of ferric nitrilotriacetate (Fe-NTA) induced renal oxidative stress and tumor promotion response by coumarin (1, 2-benzopyrone) in Wistar rats. *Cancer Letters*, 210(1), 17-26. <https://doi.org/10.1016/j.canlet.2004.01.011>
- Kurt, A., Ayhan, A. F., & Koca, M. (2018). Kumarin Türevli Kopolimerlerin Sentezi ve Karakterizasyonu. *Sakarya University Journal of Science*, 22(3), 880-887. <https://doi.org/10.16984/saufenbilder.322354>
- Kurt, A., Gündüz, B., & Koca, M. (2019). A detailed study on the optical properties of 3-benzoyl-7-hydroxy coumarin compound in different solvents and concentrations. *Macedonian Journal of Chemistry and Chemical Engineering*, 38(2), 227-236. <https://doi.org/10.20450/mjcc.2019.1403>
- Kurt, A., & Topsoy, O. (2017). Preparation of novel coumarin cyclic polymer/montmorillonite based nanocomposites. *Russian Journal of Applied Chemistry*, 90(12), 2019-2027. <https://doi.org/10.1134/S1070427217120199>
- Lentini, P., Zanolli, L., Granata, A., Signorelli, S.S., Castellino, P., & Dell'Aquila, R. (2017). Kidney and heavy metals-The role of environmental exposure. *Molecular Medicine Reports*, 15(5), 3413-3419. <https://doi.org/10.3892/mmr.2017.6389>
- Lien, E. J., Ren, S., Bui, H.H., & Wang, R. (1999). Quantitative structure-activity relationship analysis of phenolic antioxidants. *Free Radical Biology and Medicine*, 26(3-4), 285-294. [https://doi.org/10.1016/S0891-5849\(98\)00190-7](https://doi.org/10.1016/S0891-5849(98)00190-7)
- Liu, J., Wang, Q., Sun, X., Yang, X., Zhuang, C., Xu, F.,.....& Li, Y. (2016). The toxicity of aluminum chloride on kidney of rats. *Biological Trace Element Research*, 173(2), 339-344. <https://doi.org/10.1007/s12011-016-0648-9>
- Marshall, F.F. (2005). Attenuation of potassium bromate-induced nephrotoxicity by coumarin (1, 2-benzopyrone) in Wistar rats: chemoprevention against free radical-mediated renal oxidative stress and tumor promotion response. *The Journal of Urology*, 174(6), 2145-2145. <https://doi.org/10.1179/135100004225003860>
- McIlwain, D. R., Berger, T., & Mak, T. W. (2013). Caspase functions in cell death and disease. *Cold Spring Harbor perspectives in Biology*, 5(4), a008656. <https://doi.org/10.1101/cshperspect.a008656>

- Nicholson, D.W. (1999). Caspase structure, proteolytic substrates, and function during apoptotic cell death. *Cell Death Differ*, 6(11), 1028-1042. <https://doi.org/10.1038/sj.cdd.4400598>
- Nofal, Z., El-Zahar, M., & Abd El-Karim, S. (2000). Novel coumarin derivatives with expected biological activity. *Molecules*, 5(2), 99-113. <https://doi.org/10.3390/50200099>
- Othman, M.S., Fareid, M.A., Abdel Hameed, R.S., & Abdel Moneim, A.E. (2020). The protective effects of melatonin on aluminum-induced hepatotoxicity and nephrotoxicity in rats. *Oxidative Medicine and Cellular Longevity* 2020, 7375136, <https://doi.org/10.1155/2020/7375136>
- Ozkaya, A., & Türkan, K. (2021). Protective Effects of 3-benzoyl-7-hydroxy Coumarin on Liver of Adult Rat Exposed to Aluminium Chloride. *Acta Chimica Slovenica*, 68(1), 222-228.
- Palma, H.E., Wolkmer, P., Gallio, M., Corrêa, M.M., Schmatz, R., Thomé, G.R., & Mazzanti, C.M. (2014). Oxidative stress parameters in blood, liver, and kidney of diabetic rats treated with curcumin and/or insulin. *Molecular and Cellular Biochemistry*, 386(1-2), 199-210. <https://doi.org/10.1007/s11010-013-1858-5>
- Patonay, T., Litkei, G., Bognár, R., & Miszti, C. (1984). Synthesis, antibacterial and antifungal activity of 4-hydroxycoumarin derivatives, analogues of novobiocin. *Pharmazie*, 39(2), 84-91.
- Placer, Z.A., Cushman, LL., & Johnson, B.C. (1966). Estimation of product of lipid peroxidation (malonyl dialdehyde) in biochemical systems. *Analytical Biochemistry*, 16(2), 359-364. [https://doi.org/10.1016/0003-2697\(66\)90167-9](https://doi.org/10.1016/0003-2697(66)90167-9)
- Rondeau, V., Commenges, D., Jacqmin-Gadda, H., & Dartigues, J.-F. (2000). Relation between aluminum concentrations in drinking water and Alzheimer's disease: an 8-year follow-up study. *American Journal of Epidemiology*, 152(1), 59-66. <https://doi.org/10.1093/aje/152.1.59>
- Sun, X., Cao, Z., Zhang, Q., Liu, S., Xu, F., Che, J.,..... & Liang, W. (2015). Aluminum trichloride impairs bone and downregulates Wnt/ β -catenin signaling pathway in young growing rats. *Food and Chemical Toxicology*, 86, 154-162. <https://doi.org/10.1016/j.fct.2015.10.005>
- Tichati, L., Benzaid, C., Trea, F., Mahmoud, R., & Kheireddine, O. (2022). Ameliorating effects of *Rhamnus alaternus* L. aqueous extract on aluminum chloride-induced nephrotoxicity via attenuation of oxidative stress in male Wistar rats. *Comparative Clinical Pathology*, 1-12. <https://doi.org/10.1007/s00580-022-03405-6>
- Turner, M.D., Nedjai, B., Hurst, T., & Pennington, D.J. (2014). Cytokines and chemokines: At the crossroads of cell signalling and inflammatory disease. *Biochimica et Biophysica Acta (BBA)-Molecular Cell Research*, 1843(11), 2563-2582. <https://doi.org/10.1016/j.bbamcr.2014.05.014>
- Ucer, O., & Kocaman, N. (2022). New candidates in the differential diagnosis of malignant mesothelioma from benign mesothelial hyperplasia and adenocarcinoma; DARS2 and suprabasin. *Tissue and Cell*, 79, 101920. <https://doi.org/10.1016/j.tice.2022.101920>
- Venugopala, K.N., Rashmi, V., & Odhav, B. (2013). Review on natural coumarin lead compounds for their pharmacological activity. *BioMed Research International* 2013, 963248. <https://doi.org/10.1155/2013/963248>
- Williams, R. J. (1999). What is wrong with aluminium? The J.D. Birchall Memorial Lecture. *Journal of Inorganic Biochemistry*, 76(2), 81-88. [https://doi.org/10.1016/s0162-0134\(99\)00118-x](https://doi.org/10.1016/s0162-0134(99)00118-x)
- Xu, F., Liu, Y., Zhao, H., Yu, K., Song, M., Zhu, Y., & Li, Y. (2017). Aluminum chloride caused liver dysfunction and mitochondrial energy metabolism disorder in rat. *Journal of inorganic biochemistry*, 174, 55-62. <https://doi.org/10.1016/j.jinorgbio.2017.04.016>
- Yousef, M. I., Mutar, T. F., & Kamel, M. A. E.-N. (2019). Hepato-renal toxicity of oral sub-chronic exposure to aluminum oxide and/or zinc oxide nanoparticles in rats. *Toxicology Reports*, 6, 336-346. <https://doi.org/10.1016/j.toxrep.2019.04.003>
- Xu, F., Ren, L., Song, M., Shao, B., Han, Y., Cao, Z., & Li, Y. (2018). Fas- and mitochondria-mediated signaling pathway involved in osteoblast apoptosis induced by AlCl₃. *Biological trace element research*, 184, 173-85. <https://doi.org/10.1007/s12011-017-1176-y>
- Yu, Q., Zhu, K., Ding, Y., Han, R., Cheng, D. (2022). Comparative study of aluminum (Al) speciation on apoptosis-promoting process in PC12 cells: Correlations between morphological characteristics and mitochondrial kinetic disorder. *Journal of Inorganic Biochemistry*, 232, 111835. <https://doi.org/10.1016/j.jinorgbio.2022.111835>