

To cite this article: Okkesim A, Adışen MZ, Mısırlıoğlu M, Tekin U. Diagnosis and treatment of keratocystic odontogenic tumor mimicking a dentigerous cyst in panoramic radiography. Turk J Clin Lab 2017; 8(1): 28-31.

## ■ Case Report

# Diagnosis and treatment of keratocystic odontogenic tumor mimicking a dentigerous cyst in panoramic radiography

## *Panoramik radyografide dentigeröz kiste benzeyen keratokistik odontojenik tümörün teşhis ve tedavisi*

Alime OKKESİM<sup>1a</sup>, Mehmet Zahit ADIŞEN<sup>1</sup>, Melda MISIRLIOĞLU<sup>1</sup>, Umut TEKİN<sup>2</sup>

<sup>1</sup>Kırıkkale University, Faculty of Dentistry, Department of Oral and Maxillofacial Radiology, Kırıkkale,

<sup>2</sup>Kırıkkale University, Faculty of Dentistry, Department of Oral and Maxillofacial Surgery, Kırıkkale, TURKEY

### ABSTRACT

Keratocystic odontogenic tumor (KCOT) is a cystic lesion of odontogenic origin, which is classified as a developmental tumor derived from the dental lamina. KCOT may occur in any part of both maxillaries, most commonly in the angle and the ramus region of the mandible. It has an aggressive behavior and high recurrence rate. Radiographically, lesions may appear as round or ovoid in shape, often with a scalloped, multilocular appearance that may involve an impacted tooth. In this case report, a unilocular radiolucent large lesion with relatively well-circumscribed margins involving the left mandibular impacted third molar was detected incidentally on panoramic radiographic examination. Cone beam computed tomography (CBCT) was used for advanced imaging. The radiographic appearance of the lesion resembled a dentigerous cyst. Patient was consulted to Oral and Maxillofacial Surgery Department for possible treatment options. Initially an intraoral surgical operation with marsupialization was made under local anesthesia. After four months, the dimension of the lesion was reduced, previous marsupialization followed by surgical enucleation. The histopathological report revealed a parakeratinized epitel surrounding the lesion that means a KCOT.

**Key words:** Keratocyst, dentigerous cyst, cone-beam computed tomography.

### ÖZ

Keratistik odontojenik tümör (KKOT) odontojenik kaynaklı, dental laminadan gelişen ve tümör olarak sınıflandırılan kistik bir lezyondur. KKOT orofasiyal bölgede maxilla ve mandibulada, sıklıkla da mandibulanın ramus ve angulus bölgelerinde görülür. Agresif davranış gösteren ve nüksetme oranı yüksek benign bir neoplazmdir. Radyografik olarak lezyonlar yuvarlak veya oval şekilli, bazen de tarak şeklinde multiloküler görüntü sergiler ve gömülü bir diş ile ilişkili olabilir. Bu vaka raporunda, sol alt gömülü üçüncü molar diş ile ilişkili, iyi sınırlı ve geniş uniloküler radyolüsent bir lezyon rutin panoramik radyografik incelemede tesadüfen tespit edildi. İleri görüntüleme amacıyla bölgeden konik ışınli bilgisayarlı tomografi (KİBT) görüntüleri alındı. Lezyonun radyografik özelliklerine göre dentigeröz kist ön tanısı kondu. Hasta olası tedavi seçenekleri için Ağız Diş ve Çene Cerrahisi Anabilim Dalı'na konsülte edildi. Tedavide ilk olarak lokal anestezi altında marsupializasyon işlemi gerçekleştirildi. İlk operasyondan 4 ay sonra lezyon boyutları küçüldüğünde, cerrahi olarak enükleasyon yapıldı. Histopatolojik incelemede lezyonun parakeratinize epitel ile çevrili olmasından dolayı kesin teşhis olarak KKOT olduğu rapor edildi.

**Anahtar kelimeler:** Keratokist, dentigeröz kist, konik ışınli bilgisayarlı tomografi.

Corresponding Author: Alime OKKESİM, Kırıkkale Üniversitesi Diş Hekimliği Fakültesi, Oral ve Maksillofasiyal Radyoloji Departmanı, Kırıkkale, TURKEY

Phone: : +90 318 2244927-2243618

e-mail: dt.alimeeraslan@gmail.com

Received 17.03.2016, accepted 07.04.2016

Doi: 10.18663/tjcl.298239

## Introduction

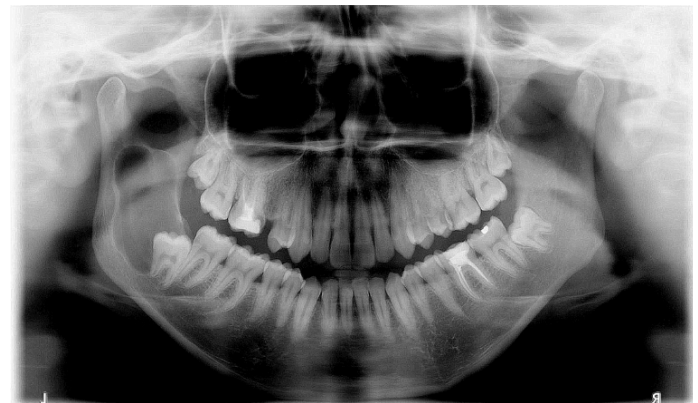
The odontogenic keratocyst is a cystic lesion of odontogenic origin, derived from the dental lamina [1]. The World Health Organization (WHO) recent classification of head and neck tumors reclassified the keratocyst as a benign neoplasm recommending the term keratocystic odontogenic tumor (KCOT) [2]. The incidence of keratocysts varied from 3%-12% (mean 7%) of all odontogenic cysts [3]. KCOT may occur in any part of both maxillaries, most commonly in the angle and the ramus region of the mandible [4]. It has an aggressive behavior and high recurrence rate. Clinical features includes swelling and/or pain. Even though some asymptomatic cases have also been reported [5].

Radiographic evaluation is important in the diagnosis to detect the size of the lesion and define its anatomical relationships. It is also useful in assessing the borders to ascertain the aggressiveness of the lesion. These lesions may appear as round or ovoid in shape, often with a scalloped, multilocular appearance that may involve an impacted tooth. Multiple keratocysts are typically associated with basal cell nevus syndrome (Gorlin Syndrome) [4]. The treatment options remains controversial and includes enucleation, marsupialization, chemical curettage with Carnoy's solution, and resection [5].

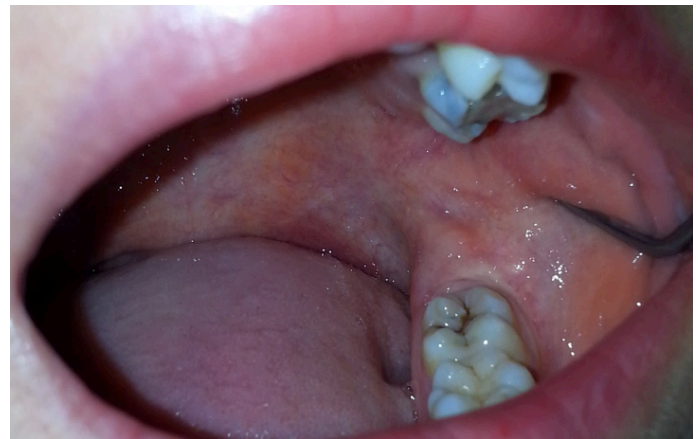In this case report, incidental diagnosis and treatment of a large KCOT involving the left mandibular impacted left third molar tooth was presented.

## Case Report

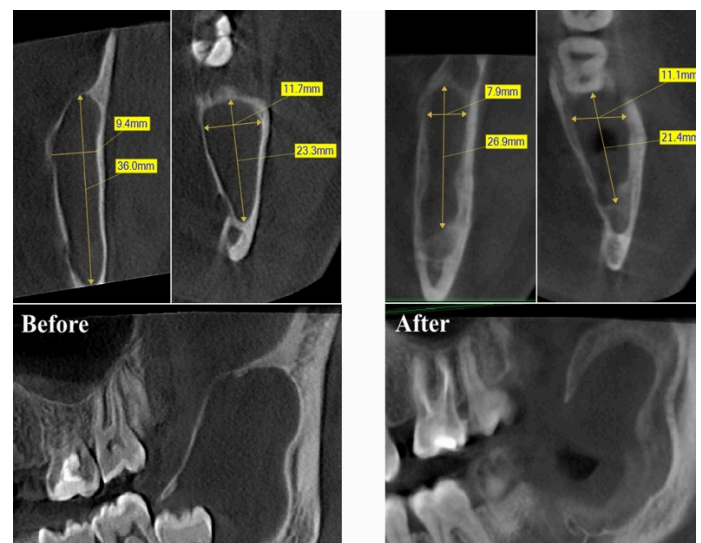
A 23-year old female patient referred to our Maxillofacial Radiology Department with toothache. On routine panoramic radiographic examination, a large unilocular radiolucent lesion with relatively well-circumscribed margins involving the left mandibular impacted third molar tooth was detected incidentally (Figure 1). On clinical examination, there was no extraoral and intraoral findings including swelling or pus drainage related to lesion (Figure 2), additionally no root resorption and teeth replacement were observed. All teeth were vital related the lesion area. For advanced imaging of the area; PaxUni 3D was used to capture Cone-beam computed tomography (CBCT) images at the following settings: 50-90 kVp, 4-10 mA, and 10 seconds exposure time, and a 50×50 mm field of view (FOV) size. Due to the radiographic appearance and clinical findings of the lesion; a preliminary diagnosis of dentigerous cyst was thought. The patient was consulted to Maxillofacial Surgery Department for possible treatment options. Before surgical operation, signed informed consent form was taken from patient. An initial surgical intervention performed with marsupialization followed by decompression. The aim of this approach is to protect the bone and other vital structures, as well as to reduce pathologic fracture risk. During this procedure specimen was taken for histopathologic examination. First histopathologic report suggested a dentigerous cyst. However, four months after the first surgery, when the dimension of the lesion was reduced (Figures 3,4), the cyst was totally excised and secondary histopathological report revealed a parakeratinized epithelial lining surrounding the lesion that means a KCOT.



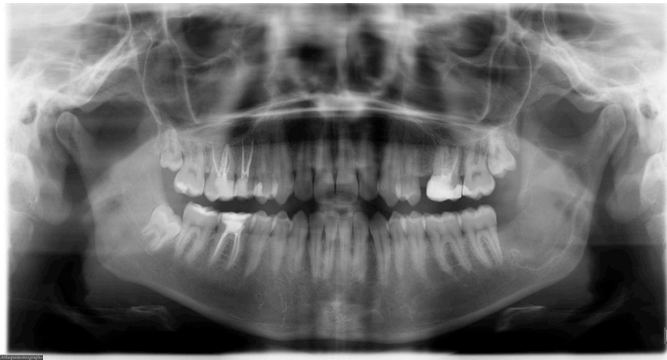**Figure 1.** Preoperative panoramic radiograph showing a large unilocular radiolucent lesion with relatively well-circumscribed margins.



**Figure 2.** Preoperative intraoral picture of the lesion area. There was no intraoral findings including swelling or pus drainage.



**Figure 3.** Showing the reduction of lesion dimensions four months after marsupialization followed by decompression. Preoperative and postoperative CBCT scans.



**Figure 4.** Panoramic radiograph of the patient four months after marsupialization.

## Discussion

KCOT, formerly known as the odontogenic keratocyst, is a benign developmental odontogenic tumor with many unique clinical and histological features [4]. KCOT has wide age range, but mainly seen in the 2nd and 4th decades of life [6]. The lesions are more common in males [7]. Above 70 percent of cases involve the mandible, especially in the molar, angle and ramus regions. Other locations such as the anterior portion of the maxilla, the maxillary sinus and the maxillary third molar area have also been reported [3]. Approximately 20-40% of KCOTs are associated with impacted teeth. On the other hand, this feature is also identical for dentigerous cysts. The main difference between keratocysts and other jaw cysts is insidious growth of the KCOT into the medullary bone, causing no clinical symptoms [8]. Additionally KCOT has an aggressive behavior and higher recurrence rate than other type of jaw cysts [3].

Clinically symptoms may be present, especially with larger lesions [8]. Occasional pain, swelling, and drainage which is suggestive of a secondary infection of the cyst [4]. KCOTs are usually detected incidentally during routine radiographic examinations. Radiographically lesions are identified as unilocular radiolucencies with well-demarcated thin corticated margins. Larger lesions may become multilocular with scalloped borders. Root resorption is relatively uncommon [6].

Although panoramic and periapical radiography plays a fundamental role, as they are the most frequently employed dental radiographic methods, spatial information in all 3 dimensions was critical in establishing a diagnosis [5]. The serial images provided by a computed tomography (CT) scan make it possible to identify the relationship between the lesion and the surrounding anatomical structures. CT has lower space resolution but is more sensitive in revealing bone shape than plain radiographs which can display trabecular bone pattern clearly. Magnetic resonance (MR) images provides good contrast

between different tissues and more detailed information than CT images, especially for the soft tissues. However, MRI is inferior to CT in demonstrating early bone changes, therefore, CT scan may be considered in some cases when bone changes was suspected [9]. Recently, CBCT with high-level spatial resolution has been used for diagnostic imaging of the oral and maxillofacial regions and various anatomical structures. Owing to its lower radiation exposure, low cost and higher speed relative to conventional CT and MRI has made CBCT a valuable tool for diagnosis of various bone lesions [10].

Histopathologically, diagnostic findings involve a uniform cyst lining, hyperchromatic and palisaded basal cells, wavy parakeratin production and a flat interface between the epithelium and connective tissue wall [8,11]. Importantly, these classic histopathologic features are often lost if the cyst is inflamed, which can guide to an incorrect diagnosis [8].

Treatment approaches in different cases have varied from marsupialization and enucleation, which may be combined with adjuvant therapy, such as cryotherapy and Carnoy's solution, to marginal or radical resection [7,12]. Many authors agree that simple enucleation is sufficient, provided that patients are closely followed up both clinical and radiologically for several years. On the other hand, many authors recommend the application of Carnoy's solution, a tissue fixative to bony cavity following enucleation and curettage [3].

The present study concentrated on clinical imaging and histological diagnosis, as well as on the therapy of the KCOT. We support the notion that marsupialization is significant in preserving bone and other vital structures, as well as reducing of pathologic fracture risk in large cystic lesions.

## Declaration of conflicting interests

The authors declared no conflicts of interest with respect to the authorship and/or publication of this article.

## Funding

The authors received no financial support for the research and/or authorship of this article.

## References

1. Singh M, Gupta KC. Surgical treatment of odontogenic keratocyst by enucleation. *Contemp Clin Dent* 2010; 1: 263-7.
2. Padaki P, Laverick S, Bounds G. Conservative management of a large keratocystic odontogenic tumour. *J Surg Case Rep* 2014; 2014. pii: rju091. doi: 10.1093/jscr/rju091.
3. Janardhan A, Prakash P, Prabhakar R. Odontogenic keratocyst associated with impacted maxillary third molar. *Oral Surg* 2013; 6: 50.



4. Chaudhary D, Bhargava M, Aggarwal S, Gill S. Keratocystic odontogenic tumor-A case report with review of literature. *Indian J Stomatol* 2012; 3: 66-9.
5. Deepankar M, Akansha M, Shalu R, Rohit M. Cone-beam computed tomographic illustration of an unusual position of keratocystic odontogenic tumor mimicking a dentigerous cyst: A case report. *J Indian Acad Oral Med Radiol* 2014; 26: 187.
6. K. Priya, P. Karthikeyan, V. Nirmal Coumare. Odontogenic keratocyst: A case series of five patients. *Indian J Otolaryngol Head Neck Surg* 2014; 66: 17-21.
7. de Lima JL, Dias-Ribeiro E, Honfi ES, de Araújo TN, de Góes KKH, do Socorro Aragão M. Odontogenic Keratocyst of mandible. *Indian J Otolaryngol Head Neck Surg* 2006; 58: 373-6.
8. Bland PS, Shiloah J, Rosebush MS. Odontogenic Keratocyst: A case report and review of an old lesion with new classification. *J Tenn Dent Assoc* 2012; 92: 33-6.
9. Zhu L, Yang J, Zheng YW. Radiological and clinical features of peripheral keratocystic odontogenic tumor. *Int J Clin Exp Med* 2014; 7: 300-6.
10. Adisen MZ, Selmi Y, Misirlioglu M, Atil F. Evaluation of volumetric measurements on CBCT images using stafne bone cavities as an example. *Med Oral Patol Oral Cir Bucal* 2015; 20: e580-e6.
11. Mojsa I, Stypulkowska J, Kaczmarzyk T, Okon K, Zaleska M. Treatment of a patient with large keratocystic odontogenic tumour in the mandible: case report with literature review. *Oral Surg* 2012; 5: 1-6.
12. Chirapathomsakul D, Sastravaha P, Jansisyanont P. A review of odontogenic keratocyst and the behaviour of recurrences. *Oral Surg Oral Med Oral Pathol Oral Radiol Endod* 2006; 101: 5.