



# Evaluation of Penetrating Keratoplasty Results: Initial Experiences

## Penetran Keratoplasti Sonuçlarının Değerlendirilmesi: İlk Deneyimler

Mehmet Sirac Demir<sup>1</sup>, Ersin Muhafız<sup>2</sup>, Yusuf Evcimen<sup>3</sup>

<sup>1</sup>Lokman Hekim Hospital, Ophthalmology Department, Van; <sup>2</sup>Kafkas University Faculty of Medicine, Ophthalmology Department, Kars;

<sup>3</sup>Urartu Eye Center, Van, Türkiye

### ABSTRACT

**Aim:** It is aimed to examine the indication distributions and clinical results of penetrating keratoplasties (PKP) performed with the first experience of surgeons in a center where PKP was started for the first time.

**Material and Method:** In this retrospective study, 64 eyes of 63 patients who underwent PKP at Van Training and Research Hospital between 2017 and 2020 were evaluated. Demographic characteristics, PKP indications, and additional pathologies of the patients were obtained from the files of the patients and their records in the Van Training and Research Hospital eye bank. In addition, preoperative, postoperative first, third, and sixth-month visual acuities of the patients were evaluated, and postoperative complications were examined. The surgeries were performed by three different surgeons (EM, MSD, YE) who had just started performing PKP.

**Results:** Penetrating keratoplasty indications are respectively pseudophakic bullous keratopathy (32.8%), keratoconus (17.1%), corneal scar due to previous herpes keratitis (14%), corneal dystrophy (10.9%), aphakic bullous keratopathy (9.3%), traumatic scar (9.3%), graft with rejection reaction (4.6%), and a corneal abscess that did not regress with medical treatment (1.5%). Postoperative complications were glaucoma (9.3%), rejection reaction (7.8%), cataract (6.2%), suture loosening (4.6%), keratitis (3.1%), traumatic perforation (1.5%) and endophthalmitis (1.5%). There was a statistically significant increase in visual acuity in the first, third, and sixth months compared to the preoperative value (for all;  $p < 0.01$ ). However, there was no significant increase in visual acuity in the sixth postoperative month compared to the third month ( $p > 0.05$ ).

**Conclusion:** The most common indication for PKP was pseudophakic bullous keratopathy. In this patient series, which consisted of the first experiences of surgeons, the postoperative complication rate was 34.3%. Despite this, a significant improvement in visual acuity and graft survival was achieved in 95.3% of patients in early postoperative follow-ups.

**Key words:** penetrating keratoplasty; indications; complications

### ÖZET

**Amaç:** İlk defa penetran keratoplasti (PKP) yapılmaya başlanan bir merkezde cerrahların ilk deneyimleri ile yapılan PKP'lerin endikasyon dağılımlarının incelenmesi, klinik sonuçlarının sunulması amaçlanmıştır.

**Materyal ve Metot:** Bu retrospektif çalışmada Van Eğitim ve Araştırma Hastanesinde 2017-2020 yılları arasında PKP yapılan 63 hastanın 64 gözü değerlendirildi. Hastaların dosyaları ve Van Eğitim Araştırma Hastanesi göz bankasındaki kayıtlarından hastaların demografik özellikleri, PKP endikasyonları, ek patolojileri ile ilgili verileri elde edildi. Hastaların preoperatif, postoperatif birinci, üçüncü ve altıncı aydaki görme keskinlikleri değerlendirildi ve postoperatif komplikasyonları incelendi. Ameliyatlar yeni PKP yapmaya başlayan üç farklı cerrah tarafından (EM, MSD, YE) gerçekleştirildi.

**Bulgular:** PKP endikasyonları sırasıyla psödo-fakik büllöz keratopati (%32,8), keratokonus (%17,1), geçirilmiş herpes keratitine bağlı kornea skarı (%14), kornea distrofisi (%10,9), afakik büllöz keratopati (%9,3), travmatik skar (%9,3), red reaksiyonu gelişmiş grefon (%4,6) ve medikal tedavi ile gerilemeyen kornea apsesi (%1,5) idi. Postoperatif komplikasyonlar sırasıyla glokom (%9,3), red reaksiyonu (%7,8), katarakt (%6,2), sütür gevşemesi (%4,6), keratit (%3,1) travmatik perforasyon (%1,5) ve endoftalmi (%1,5) idi. Ameliyat öncesi değere göre birinci, üçüncü ve altıncı ayda görme keskinliğinde istatistiksel olarak anlamlı bir artış olduğu görüldü (hepsi için;  $p < 0,01$ ). Postoperatif altıncı ayda üçüncü aya göre görme keskinliğinde anlamlı bir artış olmadı ( $p > 0,05$ ).

**Sonuç:** En sık PKP endikasyonunun psödo-fakik büllöz keratopati olduğu tespit edildi. Cerrahların ilk deneyimlerinden oluşan bu hasta serisinde postoperatif komplikasyon oranı %34,3 idi. Buna rağmen erken postoperatif takiplerde hastaların görme keskinliğinde anlamlı bir artış ve %95,3'ünde greft sağkalımı elde edilmiştir.

**Anahtar kelimeler:** penetran keratoplasti; endikasyonlar; komplikasyonlar

**İletişim/Contact:** Mehmet Sirac Demir, Lokman Hekim Hospital, Ophthalmology Department, 65170 Van - Türkiye • **Tel:** 0538 826 88 95 • **E-mail:** siracdemir@yandex.com • **Geliş/Received:** 26.08.2021 • **Kabul/Accepted:** 14.11.2022

**ORCID:** Mehmet Sirac Demir, 0000-0002-6024-7932 • Ersin Muhafız, 0000-0002-8281-8767 • Yusuf Evcimen, 0000-0002-9934-2881

## Introduction

Corneal diseases are the leading causes of vision loss, especially in developing countries<sup>1</sup>. Keratoplasty is a surgical method applied to ensure the transparency of the cornea or to correct its geometry. Various pathologies cause corneal deformity or irreversible clouding, making keratoplasty indispensable for visual rehabilitation. In our country and in the world, keratoplasty is performed with optical (nephelion or scarring of the cornea), therapeutic (corneal infection or inflammation resistant to medical treatment), tectonic (corneal perforation) and cosmetic (conditions where the corneal image deteriorates and vision increase is not expected) indications<sup>2,3</sup>. The fact that the cornea is an avascular tissue and the immunological privileges it provides eliminates the tissue compatibility requirement for other organ transplants in corneal transplants and allows higher success rates<sup>4</sup>. These advantages make corneal transplants the most common tissue transplant. Tissue rejection, loosening of the sutures and related suture reaction, high astigmatism, glaucoma, uveitis and synechia may occur after PKP<sup>5</sup>. These complications require careful follow-up of the patients and may overshadow the surgical success.

Although surgical techniques that enable lamellar keratoplasty have been developed today, the need for penetrating keratoplasty (PKP) still continues<sup>2</sup>. The frequency of lamellar and PKP surgeries may vary according to the socioeconomic status of the countries. In addition, the frequency and complication rates of surgeries may change over the years<sup>3</sup>. In fact, surgical indications, frequency of surgery, complication rates and, accordingly, success rates may differ in different clinics in the same country, depending on their technological infrastructure and surgical experience, which may change over the years<sup>2,6-10</sup>. Therefore, it is important to report surgical results in different clinics or regions. In this study, it was aimed to examine the first experiences of surgeons in a center where PKP was started for the first time, and to examine the indications in patients who underwent PKP, to present the clinical results and to compare them with the literature data.

## Material and Method

In this retrospective study, 64 eyes of 63 patients who underwent PKP surgery in Van Training and Research Hospital between 2017 and 2020 were evaluated.

Approval was obtained from the Van Training and Research Hospital Ethics Committee for the study, and the study was conducted in accordance with the Helsinki Declaration standards. Data on age and gender distribution, PKP indications, and additional pathologies were obtained from the files of the patients and their records in the Van Training and Research Hospital eye bank. The initial diagnosis of patients who underwent more than one PKP in our clinic was taken into account. If the first PKP in our clinic was performed due to graft failure, the diagnosis was evaluated as graft failure. The best corrected visual acuities of the patients preoperatively, postoperatively at first, third and sixth months were evaluated and postoperative complications were examined. The donor tissues used in the surgeries were obtained from the Van Training and Research Hospital eye bank and the Ankara eye bank corneal transplantation coordination center. Donor corneas obtained within six hours after death were stored in corneal storage solution (Optisol, Chiron Ophthalmics, Irvine, CA) at +4°C until transplantation.

Before the surgery, detailed histories of the patients were taken and the best corrected visual acuity, anterior segment examination, and retina and optic nerve examination were performed in possible patients, and keratoplasty indications were determined. B-mode ultrasonography was performed when it was not possible to examine the retina biomicroscopically. Written informed consent was obtained from all patients before surgery. Before starting the surgery, the graft was prepared by cutting the donor cornea with a vacuum punch (Katena Products Inc., Denville, NJ, USA) with a diameter of 0.25–0.50 mm larger than the recipient bed. After determining the appropriate diameter by marking the corneal center of the patient, the recipient bed was prepared by cutting with a vacuum trephine (Katena Products Inc., Denville, NJ, USA) and cleaning the remaining tissues with scissors. After the graft was fixed to the recipient bed with four main fixation sutures, it was sutured with continuous or 12 single 10/0 nylon sutures. After trepanization of the recipient cornea, patients with anterior or posterior synechiae underwent synechiotomy, patients with cataracts underwent extracapsular cataract extraction and intraocular lens placement, and patients who have vitreous in anterior chamber underwent anterior vitrectomy. In the evaluation of corneal graft transparency, the findings in the last examination of the patient were taken as basis. At the end of the operation, subconjunctival

moxifloxacin and dexamethasone injections were performed. The surgeries were performed by three surgeons (EM, MSD, YE) who were just beginning to perform PKP.

In the postoperative period, topical 1% prednisolone acetate (Pred Forte, Allergan, Irvine, CA) was started eight times a day and then the dose was reduced. During follow-up, topical 1% prednisolone acetate was switched with 0.5% loteprednol etabonate (Lotemax, Bausch&Lomb). Topical 0.5% moxifloxacin (Vigamox, Alcon) was given for one week or until the epithelial defect healed. All patients were routinely fitted with therapeutic contact lenses in the postoperative period and preservative free topical artificial tear treatment was started. After the epithelium healed, the therapeutic contact lens was removed and the patient was followed up with artificial tear drops. Therapeutic contact lenses continued to be used in patients with delayed closure of the epithelial defect. The frequency of topical steroid application was decreased and the frequency of preservative free topical artificial tear treatment was increased, and the patient was followed closely. If the epithelial defect did not shrink, topical autologous serum was started. The amniotic membrane was covered in patients whose epithelial defect persisted despite these treatments. Preoperative prophylactic systemic acyclovir treatment was started for individuals with corneal opacity due to previous herpetic keratitis and this treatment was continued in the postoperative period. The suture removal procedure of the patients without suture complications was postponed after the sixth month.

In the controls performed on the first day, first week, first, third and sixth months postoperatively, the status of the graft, any signs of complications were evaluated by biomicroscopic examination, and intraocular pressure measurements were made. The best corrected visual acuity was obtained with eyeglasses correction. Correction with contact lens was not performed because refraction stabilization was expected after suture removal for correction with contact lens. Visual acuity determined by pinhole was accepted as the best corrected visual acuity in patients whose refraction values could not be measured. Complications that occurred were recorded in detail. Intraocular pressure measurements were made using applanation tonometry or pneumotonometry. Patients with irregular follow-up and missing information on the follow-up card were not included in the study.

Statistical analyzes were performed after the data were entered into the SPSS program. Quantitative data were presented as the mean standard deviation. Postoperative changes were evaluated using repeated-measures analysis of variance. Qualitative data were presented as a percentage. The relationship between the parameters was evaluated with Pearson correlation analysis. A p value less than 0.05 was considered statistically significant.

## Results

Within the scope of the study, 64 eyes of 27 female (42.2%) and 36 male (56.3%) patients were evaluated. The mean age of the patients was  $61.25 \pm 20.34$  (min-max: 15–92) years. Penetrating keratoplasty indications, in descending order, were pseudophakic bullous keratopathy in 21 (32.8%) eyes, keratoconus in 11 (17.1%) eyes, corneal scarring due to previous herpes keratitis in nine (14%) eyes, corneal dystrophy in seven (10.9%) eyes, aphakic bullous keratopathy in six (9.3%) eyes, traumatic scar in six (9.3%) eyes, graft with rejection reaction in three (4.6%) eyes, and cornea abscess that did not regress with medical treatment in one (1.5%) eye. Five of the patients with corneal dystrophy had macular dystrophy and two had granular dystrophy. In terms of additional pathologies, four (6.2%) patients had amblyopia, two (3.1%) degenerative myopia, two (3.1%) optic atrophy, one (1.5%) retinitis pigmentosa, one (1.5%) macular hole and one (1.5%) had senile macular degeneration (Table 1).

In addition, during surgery, in four (6.2%) patients cataract extraction and intraocular lens implantation, four (6.2%) synechiotomy, three (4.6%) pupiloplasty, one (1.5%) scleral fixation, one (1.5%) 1.5% anterior vitrectomy and one (1.5%) silicone removal were performed. Postoperative complications were observed in 22 (34.3%) patients during the six-month follow-up period which were glaucoma in six patients (9.3%), rejection reaction in five patients (7.8%), cataract in four patients (6.2%), suture loosening in three patients (4.6%), keratitis in two patients (3.1%) traumatic perforation in one patient (1.5%) and endophthalmitis in one patient (1.5%) (Table 2). The intraocular pressure of the patients who developed glaucoma was controlled with topical anti-glaucomatous agents and surgery was not needed. While two of the rejection reactions could be controlled with medical treatment, surgery was performed again in

**Table 1.** Surgical indications of patients before surgery and the frequency of additional pathologies

Surgical indications	Eye (%)	Additional pathologies	Eye (%)
Pseudophakic bullous keratopathy	21 (32.8)	Amblyopia	4 (6.2)
Keratoconus	11 (17.1)	Degenerative myopia	2 (3.1)
Herpes keratitis scar	9 (14)	Optic atrophy	2 (3.1)
Corneal dystrophy	7 (10.9)	Retinitis pigmentosa	1 (1.5)
Aphakic bullous keratopathy	6 (9.3)	Macular hole	1 (1.5)
Traumatic scar	6 (9.3)	Senile macular degeneration	1 (1.5)
Graft with rejection	3 (4.6)		
Corneal abscess	1 (1.5)		
Total	64 (100)		11 (17)

**Table 2.** Frequency of additional surgeries and postoperative complications during penetrating keratoplasty

Additional surgery	Eye (%)	Postoperative complications	Eye (%)
Cataract extraction and intraocular lens implantation	4 (6.2)	Glaucoma	6 (9.3)
Synechiotomy	4 (6.2)	Rejection reaction	5 (7.8)
Pupilloplasty	3 (4.6)	Cataract	4 (6.2)
Anterior vitrectomy	1 (1.5)	Suture loosening	3 (4.6)
Scleral fixation	1 (1.5)	Keratitis	2 (3.1)
Silicon removal	1 (1.5)	Endophthalmitis	1 (1.5)
		Traumatic perforation	1 (1.5)
Total	11 (17.1)		22 (34.3)

three of them. Indications for PKP in patients with rejection reaction that could be controlled with medical treatment were traumatic scar and pseudophakic bullous keratopathy. In those who developed permanent rejection reaction, the indications were herpetic keratitis scar in two and bullous keratopathy in one. Suture revision was performed in patients with suture loosening, and re-suture was required in patients with traumatic perforation. One of the three patients who developed cataracts underwent phacoemulsification and intraocular lens implantation. Keratitis was controlled with topical drugs and graft failure did not develop in these patients. The patient who developed endophthalmitis required vitrectomy and was referred to the upper center. Topical cyclosporine treatment was applied to seven patients in the postoperative period. These were patients with severe dry eye or patients at risk of rejection due to reasons such as corneal vascularization.

Mean visual acuity before surgery was  $2.52 \pm 0.69$  (min-max: 1.30–3.10) logMAR. Postoperative visual acuity according to logMAR was  $1.10 \pm 0.52$  at first month,

$0.77 \pm 0.59$  at third month and  $0.77 \pm 0.94$  at sixth month (Fig. 1). There was a statistically significant increase in visual acuity at the first, third and sixth months compared to the preoperative value (for all;  $p < 0.01$ ). When visual acuity was evaluated after surgery, it was found that visual acuity was significantly higher at the third and sixth months compared to the first month (for both;  $p < 0.01$ ). However, there was no statistically significant increase in visual acuity after the third postoperative month ( $p > 0.05$ ) (Fig. 1).

## Discussion

Although the indications and frequencies of PKP may change over the years depending on the development of new surgical techniques, PKP is still a frequently applied surgical method today<sup>11</sup>. Penetrating keratoplasty indications may also vary according to the socioeconomic status and the location of the countries<sup>12,13</sup>. In our study, the three most common PKP indications were pseudophakic bullous keratopathy, keratoconus and herpes keratitis scar, respectively. In their study with 151 patients, Çubuk et al.<sup>2</sup> reported that the

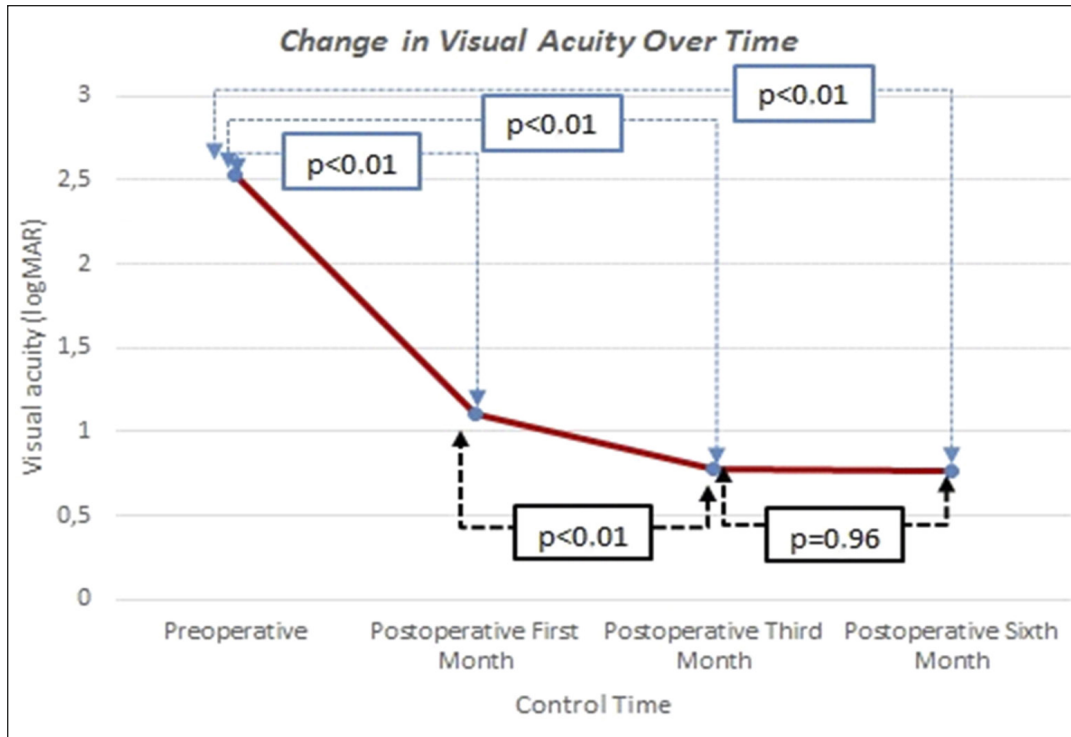


Figure 1. Change in visual acuity over time.

most common indications for PKP were graft failure, followed by pseudophakic bullous keratopathy and traumatic corneal scar. The reason why graft failure was not among the most common causes in our study may be that PKP surgery was just started in our center and therefore there were no long-term results. In a large series study conducted with 665 patients in 2009, Burcu Nurözler et al.<sup>10</sup> reported that the most common indications for PKP were keratoconus (33.2%), corneal leukoma (14.9%), and pseudophakic bullous keratopathy (13.0%). The fact that 32.8% of the indications in our study was pseudophakic bullous keratopathy may have resulted from the accumulated patients followed up in our center with this diagnosis, since keratoplasty was started for the first time in our center. In addition, there is approximately 10 years between our study and the study of Burcu Nurözler et al. We think that the rate of keratoconus in our study (17.1%) was lower than this study, since the progress of keratoconus to surgery could be prevented or delayed with the contact lenses developed in these 10 years and the widespread cross-linking applications<sup>14</sup>.

It is also important to compare the results of keratoplasty performed in the eastern Anatolia region in

the literature with our results, since the most common indication for keratoplasty may differ even between different regions in the same country<sup>15,16</sup>. In this context, in a study conducted by Öndaş et al.<sup>6</sup> at Erzurum Atatürk University, it was determined that the most common cause of keratoplasty was pseudophakic bullous keratopathy, as in our study, but corneal leukoma and scars followed it. Unlike our study, the reason why keratoconus was not among the most common indications in Öndaş et al.'s study is that they only evaluated patients over 65 years of age. In different studies in the literature, it has been reported that keratoconus is one of the most common indications of PKP<sup>10,17</sup>. However, we believe that keratoconus will lose its place among the most common causes of PKP in the coming years, as successful visual rehabilitation can be achieved without the need for surgery in keratoconus patients with the developments in recent years<sup>18</sup>.

When evaluated in terms of preoperative best corrected visual acuity, the preoperative visual acuity was found to be  $1.43 \pm 0.76$  logMAR in Öndaş et al.'s study<sup>6</sup>, and  $2.53 \pm 0.69$  logMAR in our study. The reason for the lower preoperative visual acuity of the patients in our

study may be that the surgeons preferred to operate on patients with lower visual acuity because they had their first keratoplasty experience.

When evaluated in terms of additional surgeries, it was seen that cataract extraction, intraocular lens implantation and synechiotomy were the most common procedures in our study. Similar to our study, it has been reported in the literature that the most common additional surgery is cataract extraction and intraocular lens implantation<sup>2,6</sup>. However, unlike our study, the second most common additional surgery was found to be anterior vitrectomy<sup>2,6</sup>. The reason for this may be that since keratoplasty was started for the first time in our center, it was avoided to operate on complicated cases. Because keratoplasty itself is already a major surgery. This may have caused surgeons new to surgery to avoid complicated cases, as additional pathologies may obscure surgical success.

In our study, the three most common complications were glaucoma, rejection reaction, and cataract development. In a study by Çubuk et al.<sup>2</sup> reported that complications developed in 23% of patients after PKP, the three most common complications were listed as graft rejection, suture loosening, and glaucoma. Although keratoplasty is performed for the first time in our center, the most common complications are mostly consistent with the literature. In a study conducted in our country in 1995, endophthalmitis developed in one of the 42 eyes with PKP and evisceration was applied to the patient<sup>19</sup>. In our study, endophthalmitis developed in only one patient and the patient was referred to the upper center to have vitrectomy. This result shows that the approach to endophthalmitis, which is a catastrophic complication after PKP, can change depending on the changing experience and technological support over the years.

It has been reported that graft transparency is an indicator of the success of keratoplasty<sup>10,20</sup>. Although donor-related factors may affect the transparency of the graft, the indication for PKP and the additional pathologies found in the patient are the main factors in maintaining the transparency of the graft<sup>20,21</sup>. In our study, rejection reaction developed in 5 (7.8%) eyes, graft transparency was lost in 3 (4.6%) eyes, and the need for rekeratoplasty arose. In a study conducted in our country in recent years, the rate of graft rejection was found to be 7%, similar to our study<sup>2</sup>. However, in our study, we think that this rejection rate will increase even more over time. Because, as the follow-up period increases,

the graft survival rate has been found to decrease<sup>22</sup>. It has been reported in the literature that approximately half of the cases that developed rejection returned with medical treatment<sup>10</sup>. In our study, in accordance with these results, the reaction was controlled with medical treatment in 40% of the patients who developed a rejection reaction.

Physicians who will perform keratoplasty should be aware that additional surgeries such as cataract extraction and intraocular lens implantation, synechiotomy, pupilloplasty and rarely anterior vitrectomy and scleral fixation may be needed during surgery. They should not forget that postoperative follow-up is also very important in addition to a successful surgery. For this reason, surgeons should closely monitor their patients in terms of glaucoma, rejection reaction, cataract development, suture status and infective signs during the postoperative follow-up period. In addition, we think that these physicians should have sufficient knowledge and skills in the diagnosis, follow-up and treatment of these complications.

Our study is of great importance in terms of evaluating the results of surgeons' first PKP experiences. Despite this, the lack of long-term results and the small number of patients are limitations of our study. For this reason, there is a need for studies with longer follow-ups and larger series in which the results of physicians who have just started keratoplasty surgery are monitored.

## Conclusion

The most common indication for PKP in our study was pseudophakic bullous keratopathy. In this patient series consisting of the first experiences of surgeons, the postoperative complication rate was 34.3%. Despite this, a significant improvement in visual acuity and graft survival was achieved in 95.3% of patients in early postoperative follow-ups.

## References

1. Whitcher JP, Srinivasan M, Upadhyay P. Corneal blindness a global perspective. *Bull World Health Org.* 2001;79(3):214–21.
2. Çubuk M, Koçluk Y, Özelbaykal B. Indication distributions and clinical results in penetrating keratoplasty cases. *Türkiye Klinikleri J Ophthalmol.* 2019;28(4):273–80
3. Matthaei M, Sandhaeger H, Hermel M, Adler W, Jun AS, Cursiefen C, et al. Changing Indications in Penetrating Keratoplasty: A Systematic Review of 34 Years of Global Reporting. *Transplantation.* 2017;101(6):1387–99.

4. Niederkorn JY. The immune privilege of corneal grafts. *J Leukoc Biol.* 2003;74(2):167–71.
5. Stechschulte SU, Azar DT. Complications after penetrating keratoplasty. *Int Ophthalmol Clin.* 2000;40(1):27–43.
6. Öndaş O, Keleş S, Bozkurt E. Aetiology, Outcomes And Prognosis Of Penetrating Keratoplasty Performed On Patients Aged Above 65 Years. *Turkish Journal of Geriatrics.* 2019; 22(1): 56–65.
7. Arıkan G, Durak İ, Yaman A, Özbek Z. Penetrating keratoplasty in children. *Türk Oftalmoloji Gazetesi* 2006;36:197–202.
8. Bayden Ö, Torun Acar B, Acar S. Pediatric Keratoplasty Indications and Outcomes. *MN Ophthalmol* 2012;19(2):81–8.
9. Tanyıldız B, Goktaş E, Tutaş Gunaydın N, Kandemir B. Clinical Findings and Visual Outcomes of Patients Who Underwent Urgent Keratoplasty. *MN Ophthalmol* 2020;27(2):75–80.
10. Nurözler AB, Özkan G, Onat M, Budak K, Örnek F. The Results of Tectonic Keratoplasty. *MN Ophthalmol* 2008;15(3):157–62.
11. Abdelaal AM, Alqassimi AH, Malak M, Hijazi HT, Hadrawi M, Khan MA. Indications of Keratoplasty and Outcomes of Deep Anterior Lamellar Keratoplasty Compared to Penetrating Keratoplasty. *Cureus.* 2021;13(3):e13825.
12. Dasar L, Pujar C, Gill KS, Patil M, Salagar M. Indications of penetrating keratoplasty in southern India. *J Clin Diagn Res.* 2013 Nov;7(11):2505–7.
13. Zhang AQ, Rubenstein D, Price AJ, Côté E, Levitt M, Sharpen L, et al. Evolving surgical techniques of and indications for corneal transplantation in Ontario: 2000 – 2012. *Can J Ophthalmol.* 2013;48(3):153–9.
14. Koppen C, Kreps EO, Anthonissen L, Van Hoey M, Dhubhghaill SN, Vermeulen L. Scleral Lenses Reduce the Need for Corneal Transplants in Severe Keratoconus. *Am J Ophthalmol.* 2018;185:43–7.
15. Anshu A, Price MO, Price FW Jr. Risk of corneal transplant rejection significantly reduced with Descemet's membrane endothelial keratoplasty. *Ophthalmology.* 2012;119(3):536–40.
16. Yildiz EH, Hoskins E, Fram N, Rapuano CJ, Hammersmith KM, Laibson PR, et al. Third or greater penetrating keratoplasties: indications, survival, and visual outcomes. *Cornea.* 2010;29(3):254–9.
17. Altay Y, Burcu A, Aksoy G, Ozdemir ES, Ornek F. Changing indications and techniques for corneal transplantations at a tertiary referral center in Turkey, from 1995 to 2014. *Clin Ophthalmol.* 2016;10:1007–13.
18. Muhafız E. Advances in Non-surgical Treatment Methods in Vision Rehabilitation of Keratoconus Patients. In: Ziaei A, Lanza M, ed. *Eyesight and Imaging – Advances and New Perspectives* [Internet]. London: IntechOpen; 2021.
19. Akyol F, Küçökgül S, Bayata A, Akkaya A, Çakmaklı Z. Penetrating keratoplasty results in İzmir Atatürk State Hospital. *T Klin J Ophthalmol* 1996;5:312–319.
20. Boisjoly HM, Bernard PM, Dubé I, Laughrea PA, Bazin R, Bernier J. Effect of factors unrelated to tissue matching on corneal transplant endothelial rejection. *Am J Ophthalmol.* 1989;107(6):647–54.
21. Thompson RW Jr, Price MO, Bowers PJ, Price FW Jr. Long-term graft survival after penetrating keratoplasty. *Ophthalmology.* 2003;110(7):1396–402.
22. Muraine M, Sanchez C, Watt L, Retout A, Brasseur G. Long-term results of penetrating keratoplasty. A 10-year-plus retrospective study. *Graefes Arch Clin Exp Ophthalmol.* 2003;241(7):571–6.