



The appearance of a lurking ligament in Laparoscopic Sleeve Gastrectomy; Posterior Gastric Ligament

Mutlu Ünver¹, Şafak Öztürk¹, Türker Karabuğa², İsmail Özsan¹, Zafer Önen¹, Ünal Aydın³

1 İzmir MedicalPark Hastanesi, Department of General Surgery, İzmir, Turkey

2 Özel Sada Hastanesi, Department of General Surgery, İzmir, Turkey

3 Gayrettepe Florence Nightingale Hastanesi, Department of General Surgery, İstanbul, Turkey

Received: 27.10.2016; Revised: 05.12.2016; Accepted: 19.12.2016

Abstract

Objective: The aim of this study was to demonstrate a lurking ligament and its various formation types and to mention the importance of this ligament in Laparoscopic sleeve gastrectomy

Methods: One hundred and twelve patients had laparoscopic sleeve gastrectomy (LSG) procedure in our clinic between March 2011 and September 2013. All procedures were performed with a standard operative technique. Only difference for the last 50 patients was to avoid the excessive dissection of posterior gastric wall. The existence of posterior gastric ligament was recorded and different types of posterior gastric ligament was demonstrated.

Results: Posterior gastric ligament was observed in all of the cases in different formation types. Three types of ligament; complete, partial and skippy, was demonstrated. 53(47.3%) of the patients had skippy, while 41 (36.6%) had partial and 18 (16.1%) had complete type of posterior gastric ligament.

Conclusion: A ligament named as 'posterior gastric ligament' and its various forms were defined in the third dimensional plane of stomach. Posterior gastric ligament remains as the only structure in LSG for preventing the mobility and ability of the stomach to rotate. The excessive dissection of the posterior gastric ligament should be avoided to prevent complications such as kinking and volvulus

Keywords: Gastric ligament, sleeve gastrectomy, third dimension.

DOI: 10.5798/dicletip.298607

Yazışma Adresi / Correspondence: Mutlu Ünver, İzmir Medicalpark Hastanesi, Department of General Surgery, İzmir, Turkey

e_mail: mutluunver@gmail.com

Laparoskopik Sleeve Gastrektomide ortaya çıkan gizlenmiş bir ligaman: Posterior gastrik ligaman

Özet

Giriş: Bu çalışmanın amacı, az bilinen bir bağ olan posterior gastrik ligamanın çeşitli tiplerini demonstre etmek ve laparoskopik sleeve gastrektomideki önemine değinmektir.

Yöntemler: Kliniğimizde laparoskopik sleeve gastrektomi uygulanan 120 hasta çalışmaya dahil edildi. Son 50 hasta hariç tüm hastalara aynı standart prosedür uygulandı. Son 50 hastada ise posterior gastrik duvarın ileri derecede diseksiyonundan kaçınıldı. Çeşitli posterior gastrik ligaman tipleri demonstre edilerek not edildi.

Bulgular: Posterior gastrik ligaman, değişik formasyonlarda da olsa tüm hastalarda gözlemlendi. Tam, parsiyel ve atlamalı biçimde olan 3 tür posterior gastrik ligaman gözlemlendi. 53 hastada atlamalı tarzda, 41 hastada parsiyel ve 18 hastada tam posterior gastrik ligaman gözlemlendi.

Tartışma ve Sonuç: Posterior gastrik ligaman adı verilen ve çeşitli formasyonlarda olan bu bağ 3 boyutlu olarak tanımlanmıştır. Laparoskopik sleeve gastrektomi sonrası, midenin rotasyonunu ve hareket kabiliyetini sınırlayan tek yapı posterior gastrik ligamandır. Kink ve volvulus gibi lomplikasyonlardan kaçınmak için ileri derecede olan posterior gastrik ligaman diseksiyonundan kaçınılmalıdır.

Anahtar kelimeler: Gastrik ligaman, sleeve gastrektomi, üç boyutlu.

INTRODUCTION

The stomach is an important organ of the digestive tract involving the second phase of digestion following mastication. It is fixed in place by four known ligaments: gastrohepatic, gastrocolic, gastrosplenic and gastrophrenic. The mechanism of fixation of the stomach with these ligaments can be evaluated in a two dimensional plane (Figure 1). The importance of these ligaments did not regarded except spontaneous gastric volvulus. With the use of sleeve gastrectomy in morbid obesity surgery, stomach is started to be simplified of its ligaments. Postoperative complications such as kinking and gastric volvulus, suggested us to pay intention to the existence of an anatomic structure of the stomach in the third dimensional plane (Figure 2). Especially after the experience of 'kinking' as a complication of obesity surgery, we evaluated this anatomic structure, which is used to be called 'adhesion'. We aimed to define this lurking ligament, show its various types and mention the importance of it in LSG.

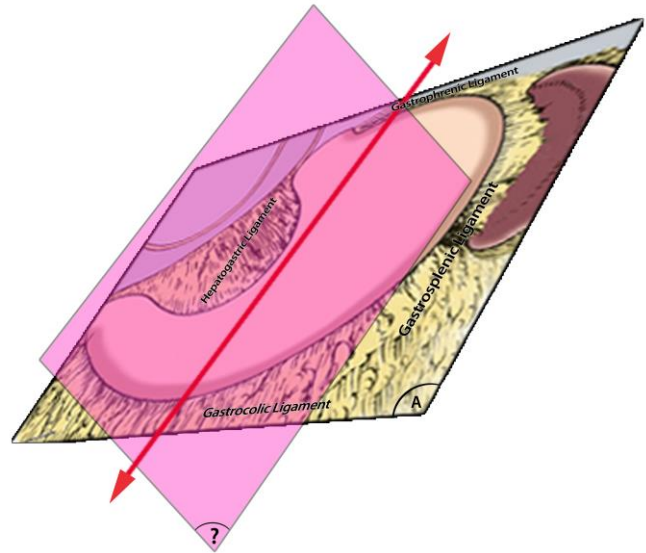


Figure 1. The two dimensional plane and ligaments of the stomach

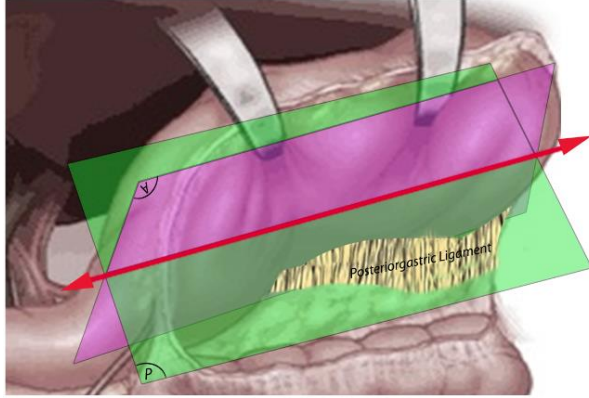


Figure 2. Posterior gastric ligament in the third dimensional plane

METHODS

Between March 2011 and September 2013 we performed 112 laparoscopic sleeve gastrectomy procedure for morbid obesity. The patients' demographic data is given in Table 1. All operations were performed with a standart technique. After trocar replacement, using a 10-mm Ligasure device (Covidien), the greater curvature of the stomach was mobilized, starting from a point 6 cm proximal to the pylorus, staying close to the wall of the stomach all the way up the greater. Once the stomach was completely mobilized, a 32-French orogastric tube was inserted orally into the pylorus. This calibrated the size of the gastric sleeve, prevented constriction at the gastroesophageal junction and provided uniform shape to the entire stomach. Gastric transection was started at a point 6 cm proximal to the pylorus, leaving the antrum and preserving gastric emptying. We staple the greater curvature strictly along the stomach tube using a 60-mm Endo-GIA stapler (Ethicon Endo-Surgery). It is important to inspect the stomach anteriorly and posteriorly to ensure that there is no redundant posterior stomach. Typically, four to five staplelines are needed. The possible areas of bleeding are clipped by 10 mm medium size laparoscopic clip. Intraoperative leak test was employed with methylene blue.

Table 1: Patient demographics

| Patients | Female | Male |
|---------------------------------------|--------------|--------------|
| n (112) | 71 (%63,3) | 41(%36,7) |
| Median age: years (range) | 37,6 (22-59) | 41,3 (24-62) |
| Median BMI: kg/m ² (range) | 42,6 (36-56) | 47,2 (39-58) |

We demonstrated the 'posterior gastric ligament' and excessive dissection of the posterior gastric wall were performed for the first 62 cases. However an uncommon complication 'kinking' was observed in some of patients and the ligament was started to prevent for the next 50 patients. Different formation types of posterior gastric ligament were evaluated and recorded.

RESULTS

One hundred and twelve patients underwent laparoscopic sleeve gastrectomy from March 2011 through September 2013 in our clinic. All of the procedures were achieved by two surgeon experienced in sleeve gastrectomy. Posterior gastric ligament was observed in all of the cases in different formation types. Three types of ligament; complete, partial and skippy, was demonstrated. 53(47.3%) of the patients had skippy, while 41 (36.6%) had partial and 18 (16.1%) had complete type of posterior gastric ligament. Different types of posterior gastric ligament is demonstrated in Figure 3(partial), 4 (skippy) and 5 (complete).

DISCUSSION

The dramatically increasing prevalence of obesity has led to the development of alternative treatment strategies including new operative techniques, such as the laparoscopic sleeve gastrectomy (LSG), which was first described in 2003 by Regan et al. [1] in a staged concept. LSG is a surgical procedure in which the gastrophrenic, gastrosplenic and gastrocolic ligaments are divided and a vertical gastrectomy performed. The stomach is a,

hollow, dilated part of the digestion system which functions as an important organ of the digestive tract. Anatomic position of the stomach is supported by gastrocolic, gastrohepatic, gastrosplenic and gastrophrenic ligaments. Laxity of these ligaments and the absence of omentum or surgical excision/dividing of these structures increase the mobility and ability of the stomach to rotate organo-axially or mesentero-axially [2]. Erenbourg was described a ligament called 'gastro-pancreatic', and they suggested that the presence of this anatomic element can suggest new interpretations of the embryological development of the pancreas [3].

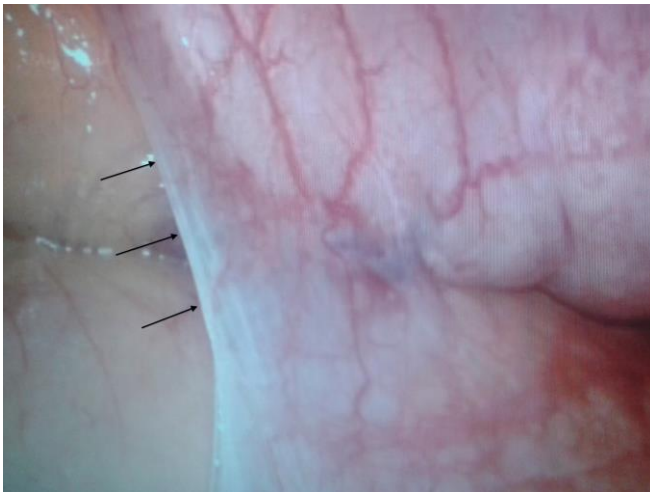

Figure 3. Partial type of posterior gastric ligament

Various surgical procedures such as subtotal gastrectomy, gastro-enterostomy, nissen fundoplication were carried out for benign or malign gastric pathologies. None of them leaves the stomach completely free of its fixating ligaments. But in laparoscopic sleeve gastrectomy, the great curvature and the posterior of the stomach becomes completely free. It leaves the stomach with no fixations along the entire great curvature. Posterior gastric ligament recently called 'adhesions' becomes an important anatomic structure for the fixation of the stomach in LSG. It differs

from other ligaments of the stomach by being in the third dimensional plane.

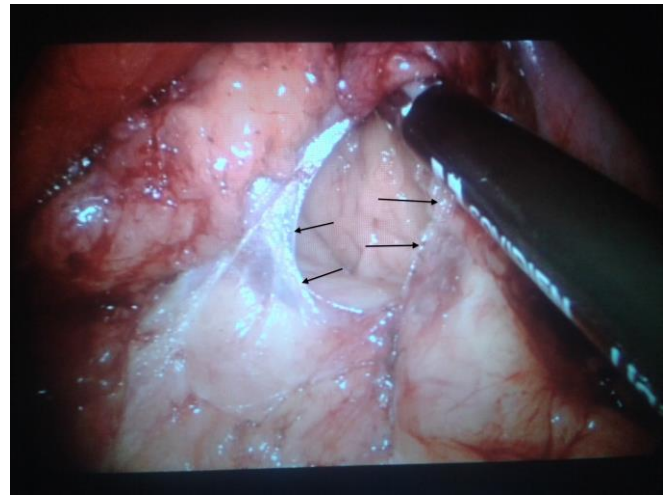


Figure 4. Skippy type of posterior gastric ligament

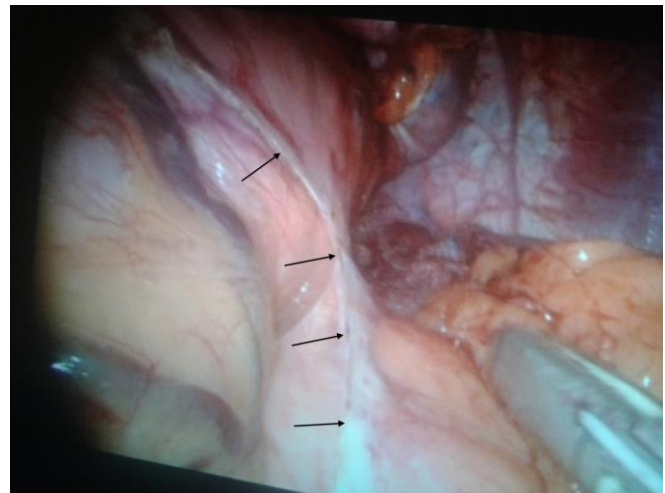


Figure 5. Complete type of posterior gastric ligament

Several gastric volvulus cases have been reported after laparoscopic gastric banding, usually occurring after placement of the band [4-6]. They recommended not to dissect the posterior wall of the stomach during band replacement. Del Castillo et al. reported a gastric volvulus case after laparoscopic sleeve gastrectomy [2]. We also experienced kinking in some of our cases. All of these complications occurs due to the mobility of the stomach.

In conclusion we demonstrated another ligament of the stomach in the third dimensional plane that has no description in the usual anatomy textbooks or in the literature and especially its importance in preventing the mobility of the stomach after LSG. The division of stomach from its main fixator ligaments in LSG reminds the posterior gastric ligament as the only structure for preventing the mobility and ability of the stomach to rotate. The excessive dissection of the posterior gastric ligament should be avoided to prevent complications such as kinking and volvulus.

Declaration of Conflicting Interests: The authors declare that they have no conflict of interest.

Financial Disclosure: No financial support was received.

REFERENCES

1. Regan JP, Inabnet WB, Gagner M, et al. Early experience with two-stage laparoscopic Roux-en-Y gastric bypass as an alternative in the super-super obese patient. *Obes Surg.* 2003; 13:861-4.
2. Del Castillo Dejardin D, Pereferrer FS, Gonzales MH, et al. Gastric volvulus after sleeve gastrectomy for morbid obesity. *Surgery.* 2013; 153:431-3.
3. Erenbourg L, Reggiani P. A new ligament: the 'gastropancreatic'. *Anat Clin.* 1985; 7:143-4.
4. Bortul M, Scaramucci M, Tonello C, et al. Gastric wall necrosis from organo-axial volvulus as a late complication of laparoscopic gastric banding. *Obes Surg.* 2004; 14:285-7.
5. Kicska G, Levine MS, Raper SE, et al. Gastric volvulus after laparoscopic adjustable gastric banding for morbid obesity. *Am J Roentgenol.* 2007; 189:1469-72.
6. Arbell D, Koplewitz B, Zamir G, et al. Midgut volvulus following laparoscopic banding: A rare and dangerous situation. *J Laparoendosc Adv Surg Tech.* 2007;17:321-3.



www.diclemedj.org

