

Giant wart on the tongue

Dil üzerinde dev siğil

Adil Ozcanli¹, Nuri Baris Hasbal², Ayse Armutlu³, Muzaffer Ozan Altuntas⁴, Secil Vural¹

¹Dept. of Dermatology and Venereology, Koç University School of Medicine, Istanbul, Turkey, ²Dept. of Internal Medicine, Koç University School of Medicine, Istanbul, Turkey, ³Dept. of Pathology, Koç University School of Medicine, Istanbul, Turkey, ⁴Dept. of Otorhinolaryngology, Koç University School of Medicine, Istanbul, Turkey

Abstract

Verruca vulgaris is a benign infection caused by the human papillomavirus (HPV). The lesions appear primarily on the cutaneous surfaces; however, mucosal involvement is less frequent. The typical presentation is asymptomatic papules varying in size and number. The differential diagnosis includes a diverse list of benign and malignant conditions.

Herein, we present a 65-year-old male patient with an asymptomatic cauliflower-like mass on the tongue incidentally observed during internal medicine physical examination. The excisional biopsy revealed verruca vulgaris, and no new lesions were detected in the follow-up.

Key words: oral mucosa, human papillomavirus, verruca vulgaris, wart, verrucous carcinoma

Öz

Verruca vulgaris, insan papilloma virüsünün (HPV) neden olduğu benign bir enfeksiyondür. Lezyonlar öncelikle kutanöz yüzeylerde görülür; bununla birlikte, mukozal tutulum daha az sıklıkta görülmektedir. Tipik görünüm, boyut ve sayı olarak değişkenlik gösteren asemptomatik papüllerdir. Ayırıcı tanı, iyi huylu ve kötü huylu çeşitli durumların bir listesini içerir.

Bu yazıda, dahiliye fizik muayenesinde tesadüfen dilde karnabahar benzeri asemptomatik kitle saptanan 65 yaşında bir erkek hasta sunulmaktadır. Eksizyonel biyopsi verruca vulgaris olarak sonuçlandı ve takiplerinde yeni lezyon izlenmedi.

Anahtar kelimeler: oral mukoza, insan papillomavirusu, verruca vulgaris, siğil, verrüköz karsinom

Introduction

The World Health Organization (WHO) defines four oral lesions caused by human papillomavirus (HPV). These are verruca vulgaris (VV), squamous cell papilloma (SP), condyloma acuminatum (CA) and multifocal epithelial

Corresponding author: Adil Ozcanli, Dept of Dermatology, Koç University School of Medicine, Istanbul, Turkey.

Phone: +90 538 9136997, E-mail: aozcanli@ku.edu.tr

Received: 17 January 2023 **Accepted:** 27 January 2023

Conflicts of Interest: None

Funding: None

How to cite this article: Ozcanli A, Hasbal NB, Armutlu A, Altuntas MO, Vural S. Giant wart on the tongue. Mucosa 2023;6:15-18.



This work is licensed under a Creative Commons Attribution-NonCommercial 4.0 International License.

hyperplasia (MFEH). The main distinction of these lesions is based on their association with different HPV subtypes.¹

Verruca vulgaris is the most common one caused by the HPV α -group and is generally associated with HPV 1, 2, 4, 27, 40 and 57. The lesions usually appear as solitary, exophytic, pink-whitish, papillomatous lesions, and the most affected areas are labial mucosa, palate, and anterior tongue. Although oral HPV infections are usually subclinical and spontaneously regress within 1-2 years of infection, chronic disease is observed in a minority of patients.²⁻⁵ Herein, we present a patient with a neglected large wart on the tongue that has been around for 15 years and removed with excisional surgery.

Case

A 68-year-old male patient was referred to the dermatology clinic due to an asymptomatic whitish, painless papillomatous lesion on his tongue that was detected coincidentally during examination to assess his eligibility to be a kidney donor. The patient admitted the lesion developed 15 years ago as a small papule and enlarged progressively and he did not seek medical attention. His medical history was insignificant, and he was a heavy smoker for 40 years. Dermatological examination revealed an approximately 2 cm \times 2 cm in size, white, solitary papillomatosis polypoid lesion on the midline of the tongue (Fig. 1). Oral cavity or extraoral regions were exempt from similar lesions. The lesion was excised, and a pathological examination was performed. The pathology revealed a benign papillomatous lesion consistent with VV. Histopathological examination showed that finger-like papillomatous projections lined by hyperkeratotic stratified squamous epithelium. Intracorneal hemorrhage was seen in some areas. The epithelium showed areas of parakeratosis, hypergranulosis and focal koilocytotic changes (Fig. 2).

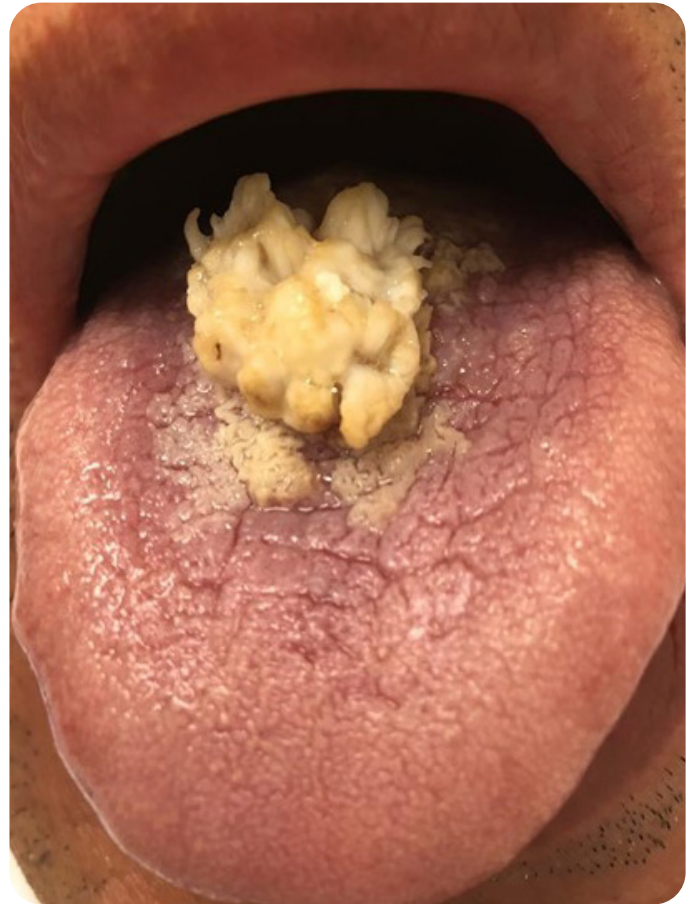

Fig. 1. Large wart on the midline of the tongue.

Discussion

HPV is defined as a sexually transmitted infectious disease. However, there can also be non-sexual transmission routes such as autoinoculation, contaminated objects, and maternofetal transmission at birth.²

The carriage rate of HPV in oral mucosa in healthy individuals is approximately 7.7%, according to a recent meta-analysis.⁶ The incidence of lesion detection due to the HPV virus in the oral cavity is around 3%.⁷ Although the lesions can be seen anywhere in the oral cavity, the lips, palate, and tongue are the most frequently affected areas.⁵

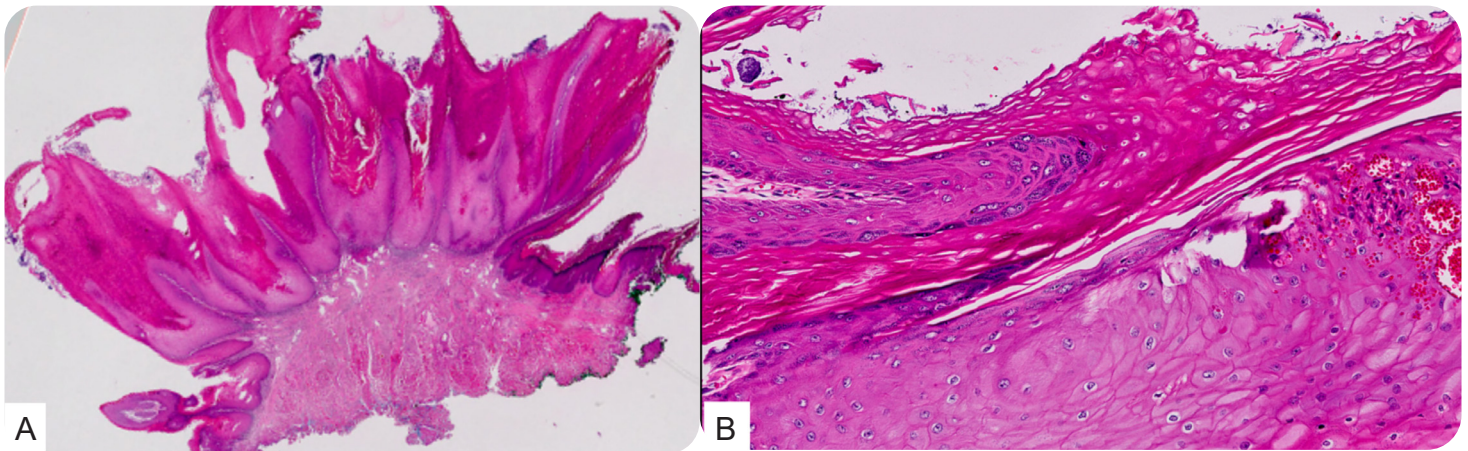


Fig. 2. Histopathologic features of the lesion. **2a.** At low magnification, long, finger-like papillomatous projections. **2b.** Epithelium showed hyperkeratosis, hypergranulosis and intraepithelial hemorrhage (on right side)

The clinical appearances of the lesions vary from benign, hyperplastic, papillomatous, and verrucous lesions to carcinomatous changes, depending on the infected HPV type and body region. The lesions can be seen in pink/white colours depending on the keratinization characteristics of the tissue they are located.^{2,4}

Verruca vulgaris lesions in the oral cavity are usually seen as solitary, papillomatous, whitish, sessile and exophytic masses, and multiple or verrucous or pedunculated lesions may also be seen. In neglected cases, chronic infection may result in the enlargement of lesions as reported in the literature and in our patient.^{4,8,9} A biopsy may be required to make a definite diagnosis. The differential diagnosis may include squamous papilloma, condyloma acuminatum, verrucous leukoplakia, verruciform xanthoma, squamous cell carcinoma and verrucous carcinoma associated with HPV infection.¹⁰

Treatment is necessary to reduce viral transmission. Treatment options are surgical excisional biopsy, destruction using CO₂ laser, electrosurgery, cryotherapy or topical agents for multiple lesions. An excisional biopsy can be recommended as a first-line curative treatment for large lesions affecting the

quality of life.⁵

The risk of malignant transformation in areas with chronic untreated HPV associated lesions and HPV carriers may necessitate a diagnostic biopsy. In a literature review, Atullah et al. reported a case of untreated VV on the lip and transformed squamous cell carcinoma in 4 years.¹¹

In a recently published review article, HPV has been reported to be associated with premalignant and malignant tumors from various oral lesions, including: oral leukoplakia (22-100%), oral erythroplakia (0-54%), oral lichen planus (11-60%), proliferative verrucous leukoplakia (0-89%), squamous cell carcinoma (0-38%), and verrucous carcinoma (0-7.7%).¹² In another systematic review in the literature, the odds ratio of oral potential malignant diseases and HPV are reported as lichen planus (5.12), leukoplakia (4.03), and epithelial dysplasia (5.10) and unspecified (4.44).¹³

In our case, we excised the lesion to rule out a verrucous carcinoma and to increase the quality of life for the patient. The patient was cured with complete removal of the lesions, successfully donated his kidney and no new lesions were detected in the follow-up.

Informed consent: The author certifies that he has obtained all appropriate consent forms from the patient.

Peer-review: Externally peer-reviewed

Authorship contributions:

Conception and design, or analysis and interpretation of data: AO, AA, SV

Drafting the manuscript or revising the content: AO, NBH, MOA, SV

Final approval of the version to be published: AO, NBH, AA, MOA, SV

References

1. Pina AR, Fonseca FP, Flavia-Sirotheau-Correa Pontes, et al. Benign epithelial oral lesions-association with human papillomavirus. *Med Oral Patol Oral Cir Bucal* 2019;24:e290-e5.
2. Alramadhan SA, Fitzpatrick SG, Bhattacharyya I, Islam MN, Cohen DM. Changing trends in benign human papillomavirus (HPV) related epithelial neoplasms of the oral cavity: 1995-2015. *Head Neck Pathol* 2022;16:738-45.
3. Graham SV. The human papillomavirus replication cycle, and its links to cancer progression: a comprehensive review. *Clin Sci (Lond)* 2017;131:2201-21.
4. Ural A, Arslan S, Ersoz S, Deger B. Verruca vulgaris of the tongue: a case report with literature review. *Bosn J Basic Med Sci* 2014;14:136-8.
5. Betz SJ. HPV-related papillary lesions of the oral mucosa: a review. *Head Neck Pathol* 2019;13:80-90.
6. Tam S, Fu S, Xu L, et al. The epidemiology of oral human papillomavirus infection in healthy populations: A systematic review and meta-analysis. *Oral Oncol* 2018;82:91-9.
7. Abbey LM, Page DG, Sawyer DR. The clinical and histopathologic features of a series of 464 oral squamous cell papillomas. *Oral Surg Oral Med Oral Pathol* 1980;49:419-28.
8. Mattoo A, Bhatia M. Verruca vulgaris of the buccal mucosa: A case report. *J Cancer Res Ther* 2018;14:454-6.
9. Nagaraj M. Verruca vulgaris of the tongue. *J Maxillofac Oral Surg* 2013;12:329-32.
10. Shahrabi Farahani S, Treister NS, Khan Z, Woo SB. Oral verruciform xanthoma associated with chronic graft-versus-host disease: a report of five cases and a review of the literature. *Head Neck Pathol* 2011;5:193-8.
11. Atullah JK, Murad N, Khitab U. Oral verruca vulgaris: a rare case with transformation of papilloma to well differentiated oral squamous cell carcinoma. *Pakistan Oral and Dental Journal*. 2010;30.
12. Fiorillo L, Cervino G, Surace G, et al. Human papilloma virus: current knowledge and focus on oral health. *Biomed Res Int* 2021;2021:6631757.
13. Syrjanen S, Lodi G, Von Bultzingslowen I, et al. Human papillomaviruses in oral carcinoma and oral potentially malignant disorders: a systematic review. *Oral Dis* 2011;17:58-72.