








EFFECTIVENESS OF BORIC ACID IN PREVENTING ACRYLAMIDE-CONDUCTED BRAIN DAMAGE IN RATS

 Eda Yıldızhan¹,  Burak Veli Ülger²,  Ercan Gündüz³,  Murat Akkuş¹,  Hüseyin Bilge⁴

1. Department of Histology and Embryology, Dicle University, Faculty of Medicine, Diyarbakir, Türkiye
2. Department of General Surgery, Faculty of Medicine, Dicle University, Diyarbakir, Türkiye
3. Department of Emergency, Faculty of Medicine, Dicle University, Diyarbakir, Türkiye
4. Department of General Surgery, Gazi Yaşargil Training & Research Hospital, University of Health Sciences, Diyarbakir, Türkiye

Abstract

Aim: Acrylamide (ACR) is a water-soluble neurotoxic substance that has been widely researched in recent years. Boric acid (BA) is a component that does not have a toxic effect when taken at low concentrations and has a cystotoxic activity. Studies have reported that BA has antioxidant effects. In this study, we aimed to examine the protective efficacy of BA against the toxic damage that ACR may cause in the brain tissue.

Methods: In this study, 28 Wistar Albino male rats with an average weight of 320-400 grams were used. In our study, ACR was administered intraperitoneally (i.p.) at a dose of 50 mg/kg for 14 days, while BA was administered orally (p.o.) with a dose of 200 mg/kg for 14 days. Group 1 (n=7): It is the control group and no medication was administered for 14 days. Group 2 (n=7): ACR group, Group 3 (n=7): BA group and Group 4 (n=7): ACR + BA group.

Results: The comparison between the groups in terms of serum Total Oxidant Status (TOS) and Malondialdehyde (MDA) analysis revealed that the highest MDA level was in the ACR group. The MDA and TOS levels of the ACR+BA group were significantly lower than the ACR group (p<0.05).

Conclusions: Our study revealed that BA has a protective effect in the prevention of neurotoxicity due to oxidative stress after ACR application

Keywords: Acrylamide, boric acid, oxidative stress

Corresponding Author: Eda Yıldızhan, e-mail: blgc_eda@hotmail.com

Received: 19.01.2023, Accepted: 03.03.2023, Available Online Date: 16.03.2023

Cite this article as: Yıldızhan E, Ülger BV, Gündüz E, et al. Effectiveness of Boric Acid in Preventing Acrylamide-Conducted Brain Damage in Rats.

J Cukurova Anesth Surg. 2023;6(1):92-7.

doi: 10.36516/jocass.1239256



Introduction

Acrylamide (ACR) is a water-soluble neurotoxic substance that has been widely researched in recent years^{1,2}. In different studies on ACR toxicity, it has been reported that ACR triggers kidney, bladder and prostate cancer³, has a toxic effect on the reproductive system⁴ and causes neuropathy⁵. In toxicological studies it has been supported that it has an acute effect in consumption for 14 days or less, and a chronic effect in consumptions of 365 days or more³. It is known that ACR, which is known to cause many damages in the body, is among the components in food cooked at temperatures above 120° C and in cigarette smoke^{6,7}.

Boric acid (BA) is a component that does not have a toxic effect when taken at low concentrations⁸ and has a cystotoxic activity⁹. Studies have reported that BA has antioxidant¹⁰ and antigenotoxic effects¹¹. After it is consumed, boron is excreted by the kidneys very quickly, but until it is excreted, it is kept in the feces with body fluids such as muscle, prostate, adrenal gland, semen, milk, saliva, especially organs such as the brain, bone, testis, liver¹².

We aimed to examine the protective efficacy of BA against the toxic damage caused by ACR in the brain tissue.

Materials and Methods

In this study, 28 Wistar Albino male rats with an average weight of 320-400 grams were used. Rats were fed in steel cages at 22±2 °C without diet and water restrictions.

Supply and Preparation of Chemicals

Acrylamide was purchased from Sigma Aldrich (Germany, Darmstadt) and Boric acid was purchased from Tekkim (Turkey, Bursa). Acrylamide was administered intraperitoneally at a dose of 50 mg/kg for 14 days. In a previous study, ACR was given for 11 days and it was observed that it had a toxic effect¹³. It is also known that ACR can be absorbed by all means in the body¹⁴. Boric acid

was given orally (p.o.) by gavage for 14 days at a dose of 200 mg/kg¹⁵.

Formation of Experimental Groups

Group 1 (n=7): It is the control group and no medication was administered to this group. Group 2 (n=7): ACR group, Group 3 (n=7): BA group and Group 4 (n=7): ACR + BA group, both ACR and BA were administered simultaneously for 14 days.

Termination of Experiment

At the end of the 14th day, the rats were placed under general anesthesia (90 mg/kg Ketamine HCl+ 10 mg/kg Xylazine HCl i.p.), sedation control, skin and finger pinching movements were observed to protect animal welfare. The abdomen was opened by laparotomy by making an incision from the midline of the abdomen. The animals were sacrificed by taking blood by exsanguination via the intracardiac route. The blood samples were centrifuged at 3000 rpm for 10 minutes, separated sera was sent to the biochemistry laboratory for biochemical analysis. Brain tissues taken for histopathological examinations were fixed in 10% formol and sent to the Histology laboratory.

Evaluation of Total Antioxidant (TAS) and Total Oxidant (TOS) Levels

TAS and TOS levels of serum samples taken from rats were measured with kits from Rel Assay Diagnostics (Turkey, Gaziantep). For this, the automatic measurement method developed by Erel was used^{16,17}.

Histological Evaluation

After the brain tissues were fixed in 10% formaldehyde for 24 hours, they were washed in running water for 12 hours and passed through increasing alcohol series (50-70-80-96% alcohol). After embedding in paraffin

blocks, 5 μm thick sections were cut, stained with Hematoxylin & Eosin (H&E) and visualized with a rotary micro-tome (Leica Biosystems, USA). Micrographs containing the hippocampus region were evaluated for inflammation, congestion, vacuolization and degeneration.

Measuring Blood Serum Malondialdehyde (MDA) Values

Serum MDA analysis was performed as described in the study of Kei S¹⁸.

Statistical Analysis

SPSS for Windows version 20 (SPSS Inc., Chicago, IL, USA) software package was used for statistical analysis. One-sided Analysis of Variance (ANOVA) and Tukey's tests were used for normally distributed variables and Mann Whitney-U Test for non-normally distributed variables. $p < 0.05$ was determined as significant.

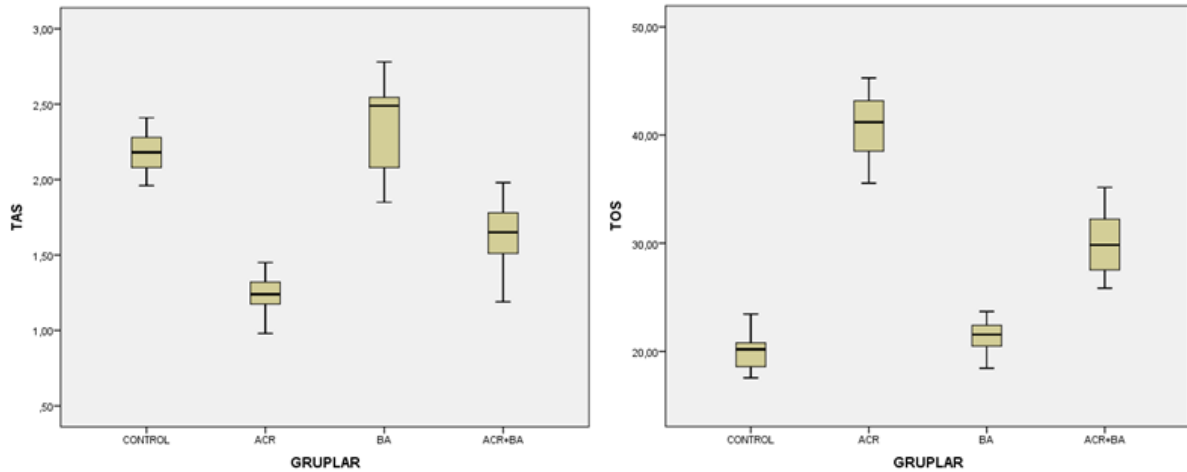
Results

TAS and TOS Measurements

We observed that the TAS levels of the groups did not show a normal distribution. Since the One-Way ANOVA test was significant ($p < 0.05$), Tukey test was used for comparison between groups. There was no significant difference between the ACR group and the ACR+BA group in terms of TAS levels ($p > 0.05$). Despite this, it was observed that the lowest TAS level belonged to the ACR group, and the highest value belonged to the BA group ($p < 0,05$).

When TOS levels were compared, it was observed that there was no statistically significant difference only between the control group and the BA group ($p = 0.15$). While the ACR group had the highest TOS level, the TOS level of the ACR+BA group was significantly lower ($p < 0,05$). (Table 1).

Table 1. Statistical analysis of the mean values of TAS; total antioxidant capacity ($\mu\text{mol H}_2\text{O}_2$ equivalent/L) and TOS; total oxidant capacity (mmol Trolox equivalent/L).



ACR: Acrylamide, BA: Boric acid.

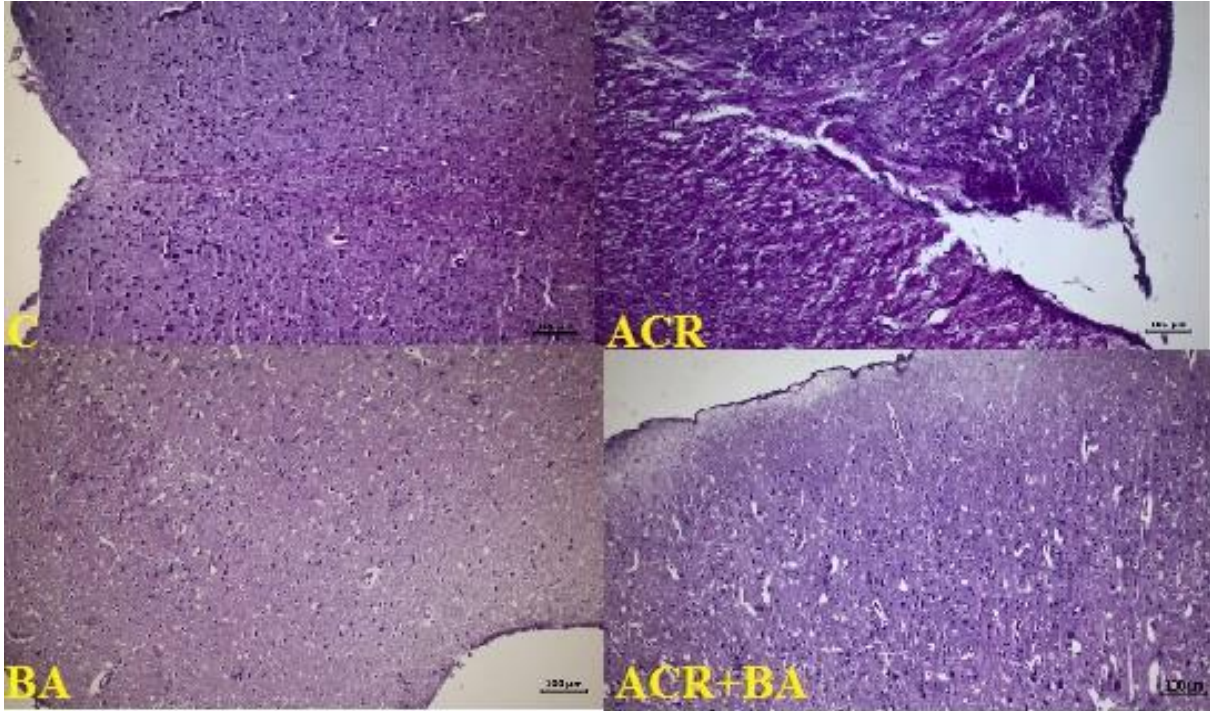
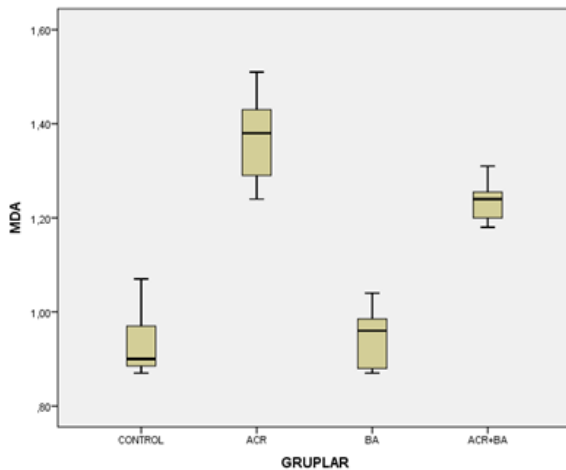


Figure 1. C; Control group, ACR; Acrylamide group, BA: Brain tissue micrographs of boric acid group (H&E, Bar 100 µm).

Table 2. Statistical analysis of the mean values of MDA; Malondialdehit ($\mu\text{mol/l}$) values.



ACR: Acrylamide, BA: Boric acid.

MDA Analysis

When the comparison was made between the groups, it was observed that the highest serum MDA grade was in the ACR group. The MDA level of the ACR+BA group was sig-

nificantly lower than the ACR group ($p=0.01$). There was no statistically significant difference between the control group and the BA group ($p=1.00$) (Table 2).

Histological Evaluation

While histopathological changes such as neural degeneration, inflammation, congestion and vacuolization were common in the ACR group, these changes were less common in the ACR+BA group (Figure 1). No histopathological changes were observed in the control group and BA group.

Discussion

Many diseases occur due to inflammation, especially cancer, diabetes, cardiovascular and neurological diseases. The main causes of this situation are oxidative stress¹⁹. Boric acid (BA) is one of the important forms of boron and has recently been the subject of extensive investigate for medical use²⁰. In the studies performed, ACR was applied at different doses (50 mg/kg, 20 mg/kg) and times, and thus, a significant increase in se-

rum proinflammatory cytokine levels such as Il-1 β , Il-6 and TNF- α was observed^{21,22}. In their study, Acaröz et al. observed an improvement in the levels of inflammatory cytokines such as TNF- α , Il-1 β , and NF κ B in brain and liver tissues of ACR applied rats, and suppression of existing expressions when boron was applied²³. We examined that ACR caused an increase in serum total oxidative stress (TOS) and MDA levels, but this situation improved when BA was applied. Yazici S et al. also pointed out the findings showing that BA has proinflammatory properties in their study²⁴. In this context, our study was parallel with other studies.

In their study, Karimkhani H et al. observed that histopathological changes such as mononuclear cell infiltration and edema occurred among cardiomyocytes in the group with myocardial infarction (MI), and that in the MI+BA group, intercalated disc structures with normal appearance were observed, and this group was very close to the control group²⁵. In their experimental renal ischemia and reperfusion (I/R) injury study, Can B et al. observe a significant increase in inflammatory cytokine levels such as GSH and MDA compared to the control group. They showed that this situation improved when treated with boric acid in case of renal I/R injury²⁶. Similarly, we observed that there was an increase in serum MDA levels in case of ACR toxicity and this situation improved when BA was applied.

Conclusion

Our study revealed that BA has a protective effect in the prevention of neurotoxicity caused by oxidative stress after ACR application, thanks to its antioxidant property.

Conflict of interest

The authors declare that they have no conflict of interest.

Funding

Authors declared no financial support.

Ethical approval

This study was approved by the Local Ethics Committee of Dicle University (DÜHADEK - 2022/21).

References

1. Tyl RW, Friedman MA. Effects of acrylamide on rodent reproductive performance. *Reprod Toxicol* 2003; 17: 1-13.
[https://doi.org/10.1016/s0890-6238\(02\)00078-3](https://doi.org/10.1016/s0890-6238(02)00078-3)
2. Pan X, Zhu L, Lu H, et al. Melatonin Attenuates Oxidative Damage Induced by Acrylamide In Vitro and In Vivo, *Oxid Med Cell Longev*. 2015; 2015: 703-9.
<https://doi.org/10.1155/2015/703709>.
3. Yousef M, El-Demerdash F. Acrylamide-induced oxidative stress and biochemical perturbations in rats. *Toxicology*. 2006; 219:133-41.
<https://doi.org/10.1016/j.tox.2005.11.008>
4. Dearfield KL, Douglas GR, Ehling UH, et al. Acrylamide: a review of its genotoxicity and an assessment of heritable genetic risk. *Mutation Research/Fundamental and Molecular Mechanisms of Mutagenesis*. 1995; 330:71-99.
[https://doi.org/10.1016/0027-5107\(95\)00037-j](https://doi.org/10.1016/0027-5107(95)00037-j)
5. LoPachin RM, Balaban C, Ross J. Acrylamide axonopathy revisited. *Toxicology and applied pharmacology*. 2003; 188: 135-53.
[https://doi.org/10.1016/s0041-008x\(02\)00072-8](https://doi.org/10.1016/s0041-008x(02)00072-8)
6. Ghanayem BI, McDaniel LP, Churcwell MI, et al. Role of CYP2E1 in the epoxidation of acrylamide to glisidamide and formation of DNA and hemoglobin adducts. *Toxicol Sci*. 2005; 88 (2): 311-8.
<https://doi.org/10.1093/toxsci/kfi307>
7. Sharp D. Acrylamide in food. *Lancet* 2003; 361: 361-2.
[https://doi.org/10.1016/S0140-6736\(03\)12442-7](https://doi.org/10.1016/S0140-6736(03)12442-7)
8. Soriano-Ursúa MA, Das BC, Trujillo-Ferrara JG. Boron containing compounds: Chemico-biological properties and expanding medicinal potential in prevention, diagnosis and therapy, *Expert Opin. Ther. Pat*. 2014; 24: 485-500.
<https://doi.org/10.1517/13543776.2014.881472>
9. O'Donovan MR, Mee CD, Fenner S, et al. Boronic acids anovel class of bacterial mutagen, *Mutat. Res*. 2011;724:1-6.
<https://doi.org/10.1016/j.mrgentox.2011.05.006>

10. Cengiz M. Boric acid protects against cyclophosphamide-induced oxidative stress and renal damage in rats. *Cell Mol. Biol. (Noisy le Grand)*. 2018; 64 (12):11–4.
11. Ince S, Kucukkurt I, Demirel HH, et al. Protective effects of boron on cyclophosphamide induced lipid peroxidation and genotoxicity in rats. *Chemosphere*. 2014; 108: 197–204.
<https://doi.org/10.1016/j.chemosphere.2014.01.038>
12. Ishii Y, Fujizuka N, Takahashi T, et al. A fatal case of acute boric acid poisoning. *Clinical Toxicology*. 1993; 31 (2); 345–52.
<https://doi.org/10.3109/15563659309000402>
13. Al-Qahtani F, Arafah M, Sharma B, Siddiqi N. Effects of alpha lipoic acid on acrylamide-induced hepatotoxicity in rats. *Cell Mol Biol (Noisy-le-grand)*. 2017; 63:1–6.
<https://doi.org/10.14715/cmb/2017.63.6.1>
14. Rizk M, Abo-El-Matty DM, Aly HF, et al, Haroun AA. Therapeutic activity of sour orange albedo extract and abundant flavanones loaded silica nanoparticles against acrylamide-induced hepatotoxicity. *Toxicol Rep*. 2018; 5: 929–42.
<https://doi.org/10.1016/j.toxrep.2018.08.021>
15. Mahmood SA, Amin KA, Salih SF. Effect of acrylamide on liver and kidneys in albino wistar rats. *Int J Curr Microbiol App Sci*. 2015; 4:434–44.
16. Erel O. A new automated colorimetric method for measuring total oxidant status. *Clin Biochem*, 2005; 38: 1103–11.
<https://doi.org/10.1016/j.clinbiochem.2005.08.008>
17. Erel O. A novel automated method to measure total antioxidant response against potent free radical reactions. *Clin Biochem*, 2004; 37: 112–9.
<https://doi.org/10.1016/j.clinbiochem>
18. Kei S. Serum lipid peroxide in cerebrovascular disorders determined by a new colorimetric method. *Clin Chim Acta* 1978;90:37e43.
[https://doi.org/10.1016/0009-8981\(78\)90081-5](https://doi.org/10.1016/0009-8981(78)90081-5)
19. Ince S, Arslan-Acaroz D, Demirel HH, et al. Taurine alleviates malathion induced lipid peroxidation, oxidative stress, and proinflammatory cytokine gene expressions in rats. *Biomed Pharmacother*. 2017; 96: 263–8.
<https://doi.org/10.1016/j.biopha.2017.09.141>
20. Lopalco A, Lopodota AA, Laquintana V, et al. Boric acid, a Lewis acid with unique and unusual properties: formulation implications. *J Pharm Sci* 2020;109(8):2375–2386.
<https://doi.org/10.1016/j.xphs.2020.04.015>.
21. Zhang L, Wang E, Chen F, et al. Potential protective effects of oral administration of allicin on acrylamide-induced toxicity in male mice. *Food Funct*. 2013; 4: 1229.
<https://doi.org/10.1039/c3fo60057b>
22. Abdel-Daim MM, Abd Eldaim MA, Hassan AG. *Trigonella foenum-graecum* ameliorates acrylamide-induced toxicity in rats: roles of oxidative stress, proinflammatory cytokines, and DNA damage. *Biochem Cell Biol*. 2014; 93 (3): 192–8.
<https://doi.org/10.1139/bcb-2014-0122>
23. Acaroz U, Ince S, Arslan-Acaroz D, Gurler Z, et al, Zhu, K. The ameliorative effects of boron against acrylamide-induced oxidative stress, inflammatory response, and metabolic changes in rats. *Food Chem Toxicol*. 2018; 118:745–52.
<https://doi.org/10.1016/j.fct.2018.06.029>
24. Yazici S, Aksit H, Korkut O, et al. Effects of boric acid and 2-aminoethoxydiphenyl borate on necrotizing enterocolitis. *J Pediatr Gastroenterol Nutr* 2014;58(1):61–7.
<https://doi.org/10.1097/MPG.0b013e3182a7e02>
25. Karimkhani H, Özkoç M, Shojaolsadati P, et al. Protective Effect of Boric Acid and Omega-3 on Myocardial Infarction in an Experimental Rat Model. *Biological Trace Element Research*. 2021; 199:2612–20.
<https://doi.org/10.1007/s12011-020-02360-z>
26. Can B, Kar F, Kar E, et al. Conivaptan and Boric Acid Treatments in Acute Kidney Injury: Is This Combination Effective and Safe? *Biological Trace Element Research*. 2022; 200:3723–37.
<https://doi.org/10.1007/s12011-021-02977-8>